

PREVALENCE OF *CANDIDA* SPECIES IN NECROTIC PULP WITH CHRONIC PERIAPICAL PROCESSES

Natalia Nastri¹, Maria Nastri¹, Virginia Jewtuchowicz^{1,2}, Maria Mujica², Cristina Iovanniti², Ariel Gualtieri³, José Ponton⁴, Alcira Rosa¹

¹ Department of Microbiology, and Parasitology, Faculty of Dentistry, University of Buenos Aires, Argentina.

² Department of Microbiology, Faculty of Medicine, University of Buenos Aires, Argentina.

³ Department of Biophysics, Faculty of Dentistry, University of Buenos Aires, Argentina.

⁴ Department of Immunology, Microbiology and Parasitology, School of Medicine and Odontology University of Basque Country, Leioa, Spain.

ABSTRACT

The aim of this study was to identify species of the genus *Candida* in mucosa of oral cavity and in single-rooted teeth with pulp necrosis with chronic endodontic periapical processes, with radiographic images 2 ± 4 mm and without clinical symptomatology, in immunocompetent patients. The study included 82 immunocompetent patients of both sexes aged 18-70 years with a clinical dental diagnosis of septic pulp necrosis. Samples were taken from root canals with sterile # 25 paper points and from oral mucosa with a sterile swab. Seven different *Candida*

species were identified (*C. albicans*, *C. dubliniensis*, *C. guilliermondii*, *C. krusei*, *C. parapsilopsis*, *C. tropicalis* and *C. glabrata*). All of them were present in oral mucosa, while two of them (*C. parapsilopsis* and *C. glabrata*) were not identified in the periapical zone of necrotic canals. Considering all the samples isolated from oral mucosa, there was a significantly greater frequency of *C. albicans* than there was in the periapical zone of necrotic canals.

Key words: *Candida*, Dental Pulp Necroses.

PREVALENCIA DE ESPECIES DE *CANDIDA* EN PULPAS NECRÓTICAS CON PROCESOS PERIAPICALES CRÓNICOS

RESUMEN

El propósito de este estudio fue identificar especies del género *Candida* en mucosa de cavidad bucal y dientes unirradiculares con necrosis pulpar con procesos periapicales crónicos de origen endodóntico con imágenes radiográficas entre 2 ± 4 mm sin sintomatología clínica en pacientes inmunocompetentes. El estudio incluyó 82 pacientes inmunocompetentes de ambos sexos con edades entre 18-70 años con diagnóstico clínico dentario de necrosis pulpar séptica. Las muestras fueron obtenidas del conducto radicular con conos de papel estéril # 25 y de la mucosa bucal mediante hisopo estéril. Se identificaron 7

especies diferentes de *Candida* (*C. albicans*, *C. dubliniensis*, *C. guilliermondii*, *C. krusei*, *C. parapsilopsis*, *C. tropicalis* y *C. glabrata*). Todas estuvieron presentes en mucosa bucal, mientras que dos de ellas (*C. parapsilopsis* y *C. glabrata*) no se identificaron en zona periapical de conductos con necrosis. Del total de las muestras aisladas de mucosa bucal hubo una frecuencia significativamente mayor de *C. albicans* que la proporción de estas levaduras en la zona periapical en conductos con necrosis.

Palabras clave: *Candida*, necrosis de la pulpa dental.

INTRODUCTION

Microorganisms from reservoirs in the oral cavity can spread and act as a source of infection. When the dentin-pulp complex is infected, microorganisms invade and may cause disease in the pulp and in root canal system¹⁻⁴.

Most of those microorganisms are opportunistic pathogens. Their survival is favored by different environmental factors in the root canal (oxygen tension, redox potential, pH, temperature and type of nutrients), which may be responsible for selecting and establishing the dominant microbe species⁵⁻⁷.

Most pathogenic responses are related to the presence of microorganisms that have numerous virulence factors (microbial capsule, fimbriae, pili, lipopolysaccharides, enzymes, fatty acids, ammonia, etc.)⁸⁻¹¹. Microorganisms in the root canal system have been found to be capable of invading tubules in dentin walls down to depths of 150-250 μm , where they cannot be eliminated by the irrigants or medication used during root canal treatment¹²⁻¹⁵.

Infection of the dentin-pulp complex may occur either as a result of necrosis produced by microorganisms or because microorganisms colonize necrotic tissue¹⁶⁻¹⁸.

Certain microorganisms may spread hematogenously from chronic apical and periapical processes to heart valves, prosthetic devices and other metastatic foci^{17,18}.

The aim of this work was to identify species of the genus *Candida* in samples from oral mucosa and chronic periapical processes of endodontic origin without clinical symptomatology in immunocompetent patients.

MATERIALS AND METHODS

Study population

The study was performed on samples isolated from 82 immunocompetent adults of both sexes aged 18 to 70 years; average age 43.3 ± 15.4 , who visited the Faculty of Dentistry offices at the University of Buenos Aires in 2005-2009. Their evaluation included dental/medical history, clinical/radiographic examination and pulp vitality tests.

The teeth selected were upper incisors diagnosed with pulp necrosis, with periapical lesion in chronic evolution (TROPE classification)¹⁹. Each tooth had crown-root integrity, with a 2 ± 4 mm circumscribed or diffuse radiolucent, radiographically visible periapical lesion without clinical symptomatology.

Patients signed an informed consent form after the aim of the study was explained.

Exclusion criteria

Patients who were pregnant, had severe periodontal disease, systemic disease or had taken antibiotics, non-steroidal anti-inflammatory drugs and/or corticoids or anti-fungal medication.

Permanent teeth with immature apex, teeth with difficult access to foramen, endodontic re-treatments or teeth with restorations.

Sampling

Patients rinsed their mouths with sterile distilled water, after which samples were taken from:

1. Oral mucosa, by swabbing the dorsal and ventral part of the tongue after relative isolation of the area with cotton rolls and aspiration with high-power suction.
2. Root canal: the tooth was completely isolated with a rubber dike and aspiration using high-power suction. A 10% povidone iodine solution was applied to the operating field, an opening made with a stone bur followed by sterile round drill #2, and a Maillefer/ Dentsply® K-file #15 was used to perform the catheterization and confirm that the canal could be reached. A #25 paper point (Meta Biomed Co, LTD®) was inserted into the root canal and left for 1 minute. Then the paper point was suspended in a tube containing 1000 microliters of PBS transport medium (buffered solution of sterile Phosphate Buffer 0.1 M pH 7.4, kept at 4°C), which was vortexed and then processed.

Microbiological method

1. Direct microscopy studies of the samples, fresh and Gram-and Giemsa-stained²⁰.
2. Cultures – samples were placed in selective and differential media. In order to isolate the yeast species, 100 μl microliters (0.1 ml) of the sample was transferred to a Petri dish containing solid chromogenic differential medium (CHROMagar® *Candida*, Paris, France). They were incubated at 30°C for 72 hs, and checked daily for growth.

The isolated yeasts were identified according to (A) the color developed in the chromogenic medium, (B) development of pseudomycelium with chlamydoconidia in 1%-Tween 80 milk agar (Jitaurong et al. 1993) and (C) carbohydrate assimilation profile using API ID 32D commercial systems (BioMérieux®, France)²⁰.

Any green colored colony found on the CHROMagar *Candida* was subject to the following additional studies in order to complete the presumptive identification as *C. dubliniensis*: (A) D-xylose assimilation, (B) growth at 45°C (negative for *dubliniensis*) and (C) chlamydoconidia formation on Staib medium (Staib 1999) (Sullivan and Coleman, 1998; Jewtuchowicz, 2007). It was inoculated by stabbing on a sterile slide containing 3 ml of the

medium, and incubated at 28°C for 48 hs in a moist chamber. Presence of chlamydoconidia was observed under microscope at 200X and 400X.

Enzymatic activity (lipase) was visible on the 1% tween-80 and Ca chloride medium by the opaque precipitation zone.

Statistical analysis

The *Candida* species identified in the oral mucosa and canals with pulp necrosis were distributed according to frequencies. The Chi-square test for comparing frequencies in contingency tables was used, with Yates correction for continuity (significance level $\alpha = 0.05$), using *PASW Statistics 18 (SPSS Inc.)* software.

RESULTS

Seven *Candida* species were identified (*C. albicans*, *C. dubliniensis*, *C. guilliermondii*, *C. krusei*, *C. parapsilopsis*, *C. tropicalis* and *C. glabrata*). They were all identified from oral mucosa samples, while two of them (*C. parapsilopsis* and *C. glabrata*) were not found in the periapical zone of root canals with pulp necrosis (Fig. 1 and Fig. 2).

The difference between the two groups proved to be significant for *C. albicans*, which was much higher from oral mucosa samples than from the apical zone of canals with septic necrosis ($p < 0.050$). For the rest of the species studied there were differences between the two areas, although they were not statistically significant (*C. dubliniensis*: $p = 0.368$; *C. guilliermondii*: $p = 0.677$; *C. krusei*: $p \approx 1.000$; *C. parapsilopsis*: $p \approx 1.000$; *C. tropicalis*: $p \approx 1.000$; *C. glabrata*: $p = 0.477$ (Table 1).

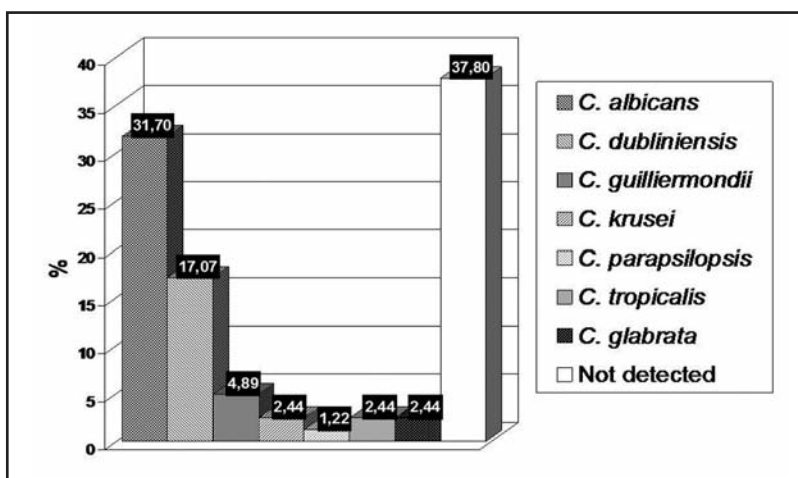


Fig. 1: Frequency distribution of *Candida* species identified in oral mucosa.

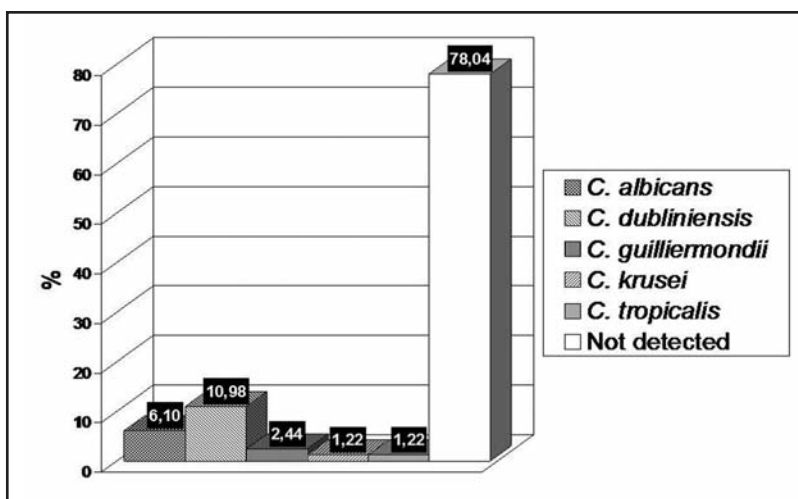


Fig. 2: Frequency distribution of *Candida* species in the periapical zone of canals with septic necrosis.

Table 1. Presence of *Candida* species in oral mucosa and periapical zone of canals with septic necrosis.

<i>Candida</i> species	Oral mucosa n	Periapical zone of canals with septic necrosis n
<i>C. albicans</i>	26*	5*
<i>C. dubliniensis</i>	14	9
<i>C. guilliermondii</i>	4	2
<i>C. krusei</i>	2	1
<i>C. parapsilopsis</i>	1	0
<i>C. tropicalis</i>	2	1
<i>C. glabrata</i>	2	0
No detectado	31	64

n: number of patients. * Significant differences between samples ($p < 0.050$).

DISCUSSION

In 2002, Nasia²¹ proposed that the true role of biofilms had not yet been elucidated, and that in the etiology of endodontic disease, mutation of microorganisms in biofilms brings about changes such as increased resistance to antimicrobial agents, increased adhesion, morphological and other changes which differ from the planktonic forms. As a result of this resistance, microorganisms in the biofilm may become reservoirs for the establishment of chronic infections.

As a result of dentistry procedures (tooth extraction, endodontic treatment, scaling and root planing, oral irrigation devices and others) infections of the oral cavity may act as a focus from which hematogenous spread of microorganisms may occur, and in presence of previous pathologies of the host, systemic infections might develop²².

We agree with Torres²³, in using cultures on chromogenic media for the primary isolation of *Candida* species, because it allows the existence of other species to be observed more easily.

Microorganisms have been isolated from teeth with pulp necrosis and clinically intact crowns. The teeth appear to be clinically healthy but reveal micro-fissures in hard tissues, which provide a means of entry for microorganisms. It has also been suggested that bacteria in the gingival crevice or periodontal pocket may reach the canals through periodontal blood vessels. Pulp infection may also occur through exposed dentin tubules at the cervical surface of the root due to lacunae in the cement covering. Microorganisms have also been found in necrotic pulp through blood circulation²⁴.

We agree with Nair²⁴ that pulp necrosis might be associated under certain circumstances with fissures in the hard tissues or other means of entry. A thin, permeable epithelium (gingival fissure) enables microorganisms that are present to reach the connective tissue and blood capillaries. It should also be noted that the endoperiodontal habitat may undergo changes in pH, oxygen pressure, nutrient availability and a range of interactions of the microbiota that is present¹².

A review of the literature on candidiasis mentions the genus *Candida* and the species *albicans* as the most frequently identified, whereas the other species are found less frequently²⁵.

Our work agrees with that of Rodríguez Ortega²⁵; in that *C. albicans* is the most prevalent species from oral mucosa samples, and in our study, a low number of a variety of other *Candida* species were identified, such as *dublinskiensis*, *guilliermondii*, *krusei*, *parapsilopsis*, *tropicales* and *glabrata*.

Sen et al.²⁶ reported that *C. albicans* is the yeast that is most frequently isolated from samples from the dentin wall of root canals and was considered to be a dentinophilic microorganism.

In our study, the most prevalent species from the periapical zone of canals with septic necrosis was *Candida dublinskiensis* (10.98 %), followed by *Candida albicans* (6.1%).

The importance of identifying the genus and species in these endodontically originating processes is epidemiological surveillance, because they form reservoirs of opportunistic microorganisms, which, under certain clinical situations, take part in specific chronic diseases.

The presence of *Candida albicans* has been found to be associated with the failure of root canal treatments, and irrigant solutions and intracanal medication are required to eliminate it²⁷.

An extensive review of the literature on endodontic microbiology showed that the different types of infections have poly-microbial etiology, and that they are usually represented by a mixed consortium whose diversity varies according to the type of infection. The profile of the microbial community shows great inter-individual variability, and the differences are even more pronounced when samples are taken from different geographic locations²⁸.

Further studies should be undertaken on larger numbers of patients in order to analyze the role of *Candida* species in the biofilm of root canals and its relationship with different parts of the oral cavity in our environment.

CONCLUSION

1. *Candida* species were identified in single-root teeth with closed chronic periapical lesion with septic necrosis.
2. The species that was most frequently isolated from oral mucosa was *Candida albicans*, followed by *Candida dublinskiensis*, while from the periapical zone of canals with septic necrosis it was *Candida dublinskiensis* followed by *Candida albicans*.

ACKNOWLEDGMENTS

This work was supported by a Grant UBACYT O 016 from University of Buenos Aires.

CORRESPONDENCE

Dra. Alcira Cristina ROSA
Cátedra de Microbiología y Parasitología,
Facultad de Odontología, Universidad de Buenos Aires
M.T. de Alvear 2142 (C1122AAH) Buenos Aires, Argentina.
E-mail: flianastri@yahoo.com

REFERENCES

1. Siqueira JF Jr. Endodontic infections: concepts, paradigms, and perspectives. *Oral Surg Oral Med Oral Pathol Oral Radiol Endod* 2002;94:281-293.
2. Nair PN, Sjögren U, Kahnberg KE, Krey G, Sundqvist G. Intraradicular bacteria and fungi in root-filled, asymptomatic human teeth with therapy-resistant periapical lesions: a long-term light and electron microscopic follow-up study. *J Endod* 2000;16:580-588.
3. Nair PNR. On the causes of persistent apical periodontitis; a review. *Int Endodont J* 2006;39:249-281.
4. Donian RM. Biofilms: Microbial life on surfaces. *Emerg Infect Dis* 2002;8:881-889.
5. Peters LB, van Winkelhoff AJ, Buijs JF, Wesselink PR. Effects of instrumentation, irrigation and dressing with calcium hydroxide on infection in pulpless teeth with periapical bone lesions. *Int Endod J* 2002;35:13-21.
6. Horiba N, Maekawa Y, Abe Y, Ito M, Matsumoto T, Nakamura H. Correlations between endotoxin and clinical symptoms or radiolucent areas in infected root canals. *Oral Surg Oral Med Oral Pathol* 1991;71:492-495.
7. Hashika K, Suzuki K, Yoshida T, Nekane A, Horiba N, Nakamura H. Relationship between clinical symptoms and enzyme-producing bacteria isolated from infected root canals. *J Endod* 1994;20:75-77.
8. Maita E, Horiuchi H. Polyamine análisis of infected root canal contents related to clinical symptoms. *Endod Dent Traumatol* 1990;6:213-217.
9. Harriott M, Noverr MC. *Candida albicans* and *Staphylococcus aureus* from polymicrobial biofilm: effects on antimicrobial resistance. *Antimicrob Agents Chemother* 2009;53:3914-3922.
10. Friedman S. Prognosis of initial endodontic therapy. *Endodontic Topics* 2002;2:59-88.
11. Munson MA, Pitt-Ford T, Chong B, Weightman A, Wade WG. Molecular and cultural analysis of the microflora associated with endodontic infections. *J Dent Res* 2002;81:761-766.
12. Waltimo T, Haapasalo M, Zehnder M, Meyer J. Clinical aspects related to endodontics yeast infection. *Endodontic Topics*. 2004;9:66-78.
13. Adam B, Baillie G, Douglas LJ. Mixed species biofilms of *Candida albicans* and *Staphylococcus epidermidis*. *J Med Microbiol* 2002;51:344-349.
14. Svensater G, Bergenholtz G. Biofilm in endodontic infections. *Endodontic Topics*. 2004;9:27-36.
15. Thomas N, Nakaes L. Managing the complexity of dynamic biofilms *J Dent Assoc* 2006;137(suppl);10S-15S.
16. Brown PD. Surgery for infective endocarditis. *Curr Infect Dis Rep* 2007;9:291-296.
17. Sritharan M, Sritharan V. Indian Emerging problems in the management of infectious diseases: the biofilms. *J Med Microbiol* 2004;22:140-142.
18. Listgarten MA, Lai CH, Young V. Microbial composition and pattern of antibiotic resistance in subgingival microbial samples from patients with refractory periodontitis. *J Periodontol*. 1993;64:155-161.
19. Ortiz Moncada C. Interpretación clínica de las lesiones endoperiodontales. *Medisan* 2002;16 (2) <http://www.sld.cu/revistas/san/vol16>
20. Jewtuchowicz VM, Brusca MI, Mujica MT, Gliosca LA, Finkelievich JL, Iovannitti CA, Rosa AC. Subgingival distribution of yeast and their antifungal susceptibility in immunocompetent subjects with and without dental devices *Acta Odontol. Latinoam* 2007;20:7-22.
21. Nasia Safdar MD, Dennis G, Maki MD. The commonality of risk factors for nosocomial colonization and infection with antimicrobial-resistant *Staphylococcus aureus*, *Enterococcus*, Gram-Negative Bacilli, *Clostridium difficile*, and *Candida*. *Ann Intern Med* 2002;136:834-844.
22. Philip S. Stewart Mechanisms of antibiotic resistance in bacterial biofilms *International. J Med Microbiol* 2002; 292:107-113.
23. Torres Rodríguez JM. *Micología Médica*. Spain: Editorial Masson, 1993:24. Nair PNR. Pathogenesis of apical periodontitis and the causes of endodontic failures. *Crit Rev Oral Biol Med* 2004;15:348-381.
24. Rodríguez Ortega J, Miranda Tarrago J. Candidiasis de la mucosa bucal. Revisión bibliográfica. *Rev Cubana Estomatol* 2002;39:1-18.
25. Sen BH, Safavi KE, Spanberg LS. Growth pattern of *Candida albicans* in relation to radicular dentin. *Oral Surg Oral Med Oral Pathol Oral Radiol Endod* 1997; 84:68-73.
26. Ashraf H, Samiei M, Eslami G, Ghodse Hosseini MR. Presence of *Candida Albicans* in root canal system of teeth requiring endodontic retreatment with and without periapical lesions. *Iranian Endodontic Journal* 2007;2:24-8.
27. Siqueira JF Jr, Rôças IN. Diversity of endodontic microbiota revisited. *J Dent Res* 2009;88:969-981.