

# A METHOD FOR MEASURING POST-EXTRACTION ALVEOLAR DIMENSIONAL CHANGES WITH VOLUMETRIC COMPUTED TOMOGRAPHY

Hernán Bontá, Federico G. Galli, Facundo Caride, Nelson Carranza

Department of Periodontology, School of Dentistry, University of Buenos Aires.

## ABSTRACT

The aim of this study is to present a predictable method for evaluating dimensional changes in the alveolar ridge through cone beam computed tomography (CT). Twenty subjects with single-rooted tooth extraction indication were selected for this preliminary report, which is part of a larger ongoing investigation. After extraction, two CT scans were performed; the first within 24 hours post-extraction (TC1) and the second 6 months (TC2) later. A radiographic guide with a radiopaque element placed along the tooth axis was developed to locate the same plane of reference in two different CT scans. For each patient, backtrack analysis was performed in order to establish the reproducibility error of a predetermined point in space between two CT scans. Briefly, an anatomical landmark was selected and its coordinates to the radiopaque marker were recorded. One week later, the coordinates were followed backwards in the same CT scan to obtain the position where the reference point should be

located. A similar process was carried out between two different CT scans taken 6 months apart. The distance between the anatomical reference and the obtained point of position was calculated to establish the accuracy of the method. Additionally, a novel method for evaluating dimensional changes of the alveolus after tooth extraction is presented. The backtrack analysis determined an average within-examiner discrepancy between both measurements from the same CT scan of 0.19 mm. SD +/- 0.05. With the method presented herein, a reference point in a CT scan can be accurately backtracked and located in a second CT scan taken six months later. Taken together, they open the possibility of calculating dimensional changes that occur in the alveolar ridge over time, such as post-extraction alveolar resorption, or the bone volume gained after different augmentation procedures.

**Keywords:** tooth socket - tooth extraction- cone beam computed tomography

## METODO PARA MEDIR CAMBIOS DIMENSIONALES EN ALVEOLOS POST- EXTRACCION MEDIANTE TOMOGRAFIA VOLUMETRICA COMPUTADA

### RESUMEN

El objetivo de este estudio es presentar un método predecible para evaluar cambios dimensionales en rebordes alveolares mediante tomografía volumétrica computada (TC). Veinte pacientes con indicación de exodoncia de piezas uniradiculares fueron seleccionados para este estudio. Posterior a las exodoncias se realizaron dos estudios tomográficos; el primero dentro de las 24hs post-extracción (TC1) y la segunda (TC2) a los seis meses de realizada la misma. Una guía radiográfica fue confeccionada utilizando un elemento radiopaco siguiendo el eje mayor de la pieza dentaria para poder localizar el mismo plano de referencia en las dos tomografías realizadas. Un método de validación fue aplicado en cada paciente para establecer el grado de reproducibilidad ubicando un punto predeterminado en ambas tomografías. Un punto anatómico de referencia fue seleccionado y las coordenadas para ubicarlo, desde el elemento radiopaco de la guía, fueron registradas. Una semana después, las coordenadas registradas fueron utilizadas en la

misma TC para encontrar la posición donde el punto anatómico de referencia debería estar ubicado. El mismo procedimiento se realizó utilizando las dos tomografías (TC1 y TC2) tomadas con seis meses de diferencia. Para establecer la exactitud del método se midió la distancia entre la posición obtenida y el punto anatómico de referencia. Se presenta además, un nuevo método para evaluar cambios dimensionales en alvéolos post-extracción. El método de validación determinó una discrepancia promedio entre ambas mediciones en la misma TC de 0,19 mm SD +/- 0.05. Con este nuevo método de medición podemos ubicar con exactitud el mismo punto anatómico en dos estudios tomográfico con un intervalo de seis meses. Este método de medición nos permite cuantificar cambios dimensionales que ocurren en rebordes alveolares posteriores a un exodoncia o un procedimiento de aumento de volumen.

**Palabras Clave:** alveolo dentario - extracción dentaria - tomografía volumétrica computada.

## INTRODUCTION

The alveolar healing process following tooth extraction has been extensively studied throughout the history of dentistry, and has attracted more attention in

the last two decades due to the advent of dental implants. This paradigm shift has generated renewed interest in the healing, remodeling and resorption processes of alveolar sockets post-extraction.

Several authors have analyzed the physiological healing process that occurs after tooth extraction, and described the remodeling and resorption process<sup>1-3</sup>, where the total volume of the socket is markedly reduced and presents wall resorption and bone filling in its center. It has been determined that bone resorption is greater on the vestibular crest than on the lingual or palatal crest of the alveolus. Vestibular bone resorption occurs not only in vestibulo-lingual direction but also along the apical-coronal tooth axis<sup>4</sup>. The greatest degree of resorption in post-extraction sockets occurs during the first six months after the extraction<sup>5</sup>.

The bone remodeling process that takes place after tooth extraction determines the optimal position in which an implant should be placed as replacement. Physiological changes that take place in the alveolus after dental extraction make the pursuit of the highest esthetic and functional requirements difficult at the time of the patient's prosthetic rehabilitation. The decision on the timing of implant placement, in relation to tooth extraction, must be based on a proper understanding of the structural changes that take place in the alveolar ridge after the loss of a tooth.

Various techniques have been described for measuring alveolar ridges, through analysis techniques, subtraction radiography, intraoperative models and measurements through re-entries at treated sites<sup>6</sup>. The results described have varying degrees of reproducibility and accuracy, according to the technique applied.

The aim of this study is to present a predictable method for assessing dimensional changes in the alveolar ridge through 3D volumetric cone beam tomography.

## MATERIALS AND METHODS

Twenty subjects who visited the Periodontology Department (FOUBA) were enrolled in this study. All subjects were over 21 years old, and had extraction indication of one or more single-rooted teeth with alveolar bone preservation<sup>7</sup>.

Exclusion criteria were blood dyscrasia, pregnancy, human immunodeficiency virus, uncontrolled hypertension, need for antibiotic prophylaxis or being under antibiotic treatment, uncontrolled diabetes, fractured teeth with alveolar wall damage and smoking. The reasons for tooth extractions were non-restorable caries, root fracture and periapical

infection. A medical, clinical and radiographic history was made for each subject and they all received hygiene instructions, and, if required, periodontal therapy.

## Radiographic Stent

Study models were obtained to make a dual-purpose acrylic stent to be used as a reference marker for taking tomographic measurements and intra-operative clinical measurements (not included in this report). The acrylic guide included a radiopaque element that consisted of a stainless steel wire 1 mm thick and 2 cm long, folded to form a 90° angle with each side measuring 1 cm. The radiopaque element was placed so that both the tips and the angle of the wire marker were aligned with the long axis of the tooth crown to be extracted (Fig. 1a,b). The CT guide was extended one tooth minimum at each side of the extraction site to provide rigidity and stability. The circumference at the bone crest level of the tooth to be extracted was delineated by drilling, and an indentation was made at each of four sides (mesial, distal, palatal or lingual and vestibular) to guide a probe if additional clinical measurements were needed (not included in this report).

## Tomographic Study

Within 24 hours of the extraction, each patient underwent a computed tomography scan (CT1) with the previously developed acrylic guide containing the radiopaque reference points in order to record measurements at baseline. One case was selected for a pilot study, on which a second CT

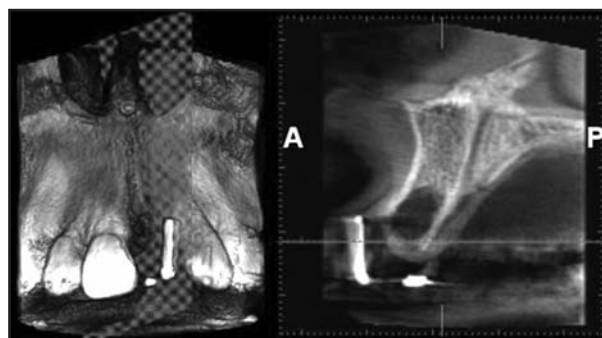


Fig. 1: The radiopaque element was placed so that both tips and angle of the wire marker were aligned with the long axis of the tooth (LAT) extracted. The radiopaque element of the guide was identified on the sagittal plane using Romexis Viewer 2.0.3.R. Planmeca.

scan was performed 6 months after tooth extraction (CT2). Alveolar ridge measurements (as described below) from CT1 and CT2 were compared for this representative study case, and changes in the ridge were calculated.

All tomographic studies were performed with a 3D cone-beam volume computed tomograph\*. Images were analyzed using the software Romexis Viewer 2.0.3.R† as follows:

The radiopaque element of the guide was identified on the sagittal plane to perform tomographic measurements. The reference sagittal plane was located, which was the plane on which both ends of the wire marker and its 90° angle could be observed simultaneously.

Then the image was rotated over the sagittal plane to align the horizontal plane (blue line) with points A and X (wire marker ends). This line (line *a*), forms the hypotenuse of a right-angled triangle, while the radiopaque element forms its legs (lines *c* and *b*). In the sagittal plane, side *b* has vestibular orientation and side *c* has palatal or lingual orientation.

#### Alveolar Ridge Measurement Method

Once the reference sagittal plane was located and a triangle was formed using the horizontal plane blue

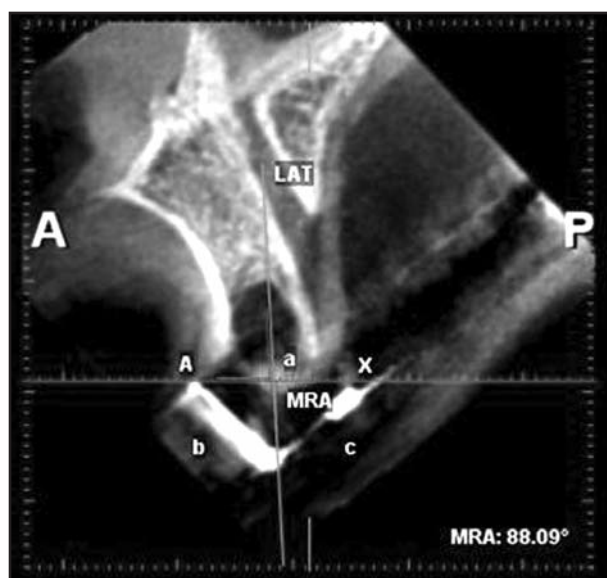

Fig. 2: The image was rotated over the sagittal plane to align points A and X (wire marker ends) with the horizontal plane (blue line). LAT (green line) and MRA (red angle) are determined.

\* Promax 3D, Planmeca, Finland.

† Romexis Viewer 2.0.3.R, Planmeca, Finland.

line, the image was saved as a new two-dimensional static image on which reference points were marked in order to take future measurements.

A reference line was marked along the long axis of the tooth (LAT). This line passes through the apex of the tooth and the incisal edge as observed in the reference sagittal plane. The angle between the LAT line and the hypotenuse (line *a*) was determined and recorded for future reference.

The angle formed between the hypotenuse (line *a*) of the triangle and the LAT line was determined, recorded and termed Main Reference Angle (MRA) (Fig 2).

Points B and B1 were then identified and marked in order to take the vestibular measurement of the alveolar ridge. Point B1 was marked on the vestibular crest while point B was a coronal projection of B1 where a line parallel to LAT (long axis of the tooth) crosses the hypotenuse (line *a*) of the triangle. By joining points B-B1, a segment was obtained called measurement segment B-B1. This segment provides the measurement from the hypotenuse to the ridge of the vestibular crest and sufficient geometrical data to locate this same point in subsequent tomographic images.

Joining points A and B forms a segment along the hypotenuse. The size of this segment will be used as a reference to find points B and B1 again and it is called reference segment A-B.

The angle formed between segments AB and B-B1 is equal to angle MRA (Fig. 3).

Once the distance between the vestibular crest and the bony crest was recorded, the same procedure was carried out in the center of the alveolar ridge (point C1) and the lingual or palatal crest (Point D1). Point C on the hypotenuse of the triangle was assigned to the center of the alveolar ridge, thus constituting reference segment A-C, while point C1 on the bone ridge formed measurement segment C-C1.

Palatal or lingual crests were measured with the same procedure. Similarly, they constituted points D1 (lingual bony crest) and D, and reference segments A-D, D-D1.

Accordingly, the angles between segments A-C and A-D were equal to angle MRA.

For the single pilot study case, six months after the extraction the CT scan was repeated (CT2) using

the same radiographic guide. On CT2, the same sagittal plane was located with the radiographic marker, and all the segments and reference angles obtained in CT1 were identified and marked in order to measure the dimensional changes that occurred after tooth extraction.

**Bony Crest Changes**

Displacement of the buccal crest was determined in both vertical and horizontal directions. Additionally, the displacement of the lingual crest and the bone fill of the socket were calculated in a vertical dimension.

*Vertical changes*

Point B2V (vertical displacement of the buccal bony crest) was determined where a line originating at point B1 and parallel to line LAT intersects the alveolar ridge.

Points C2V and D2V (vertical displacement of mid-alveolar and lingual bony crest respectively) were determined in the same way.

*Horizontal changes*

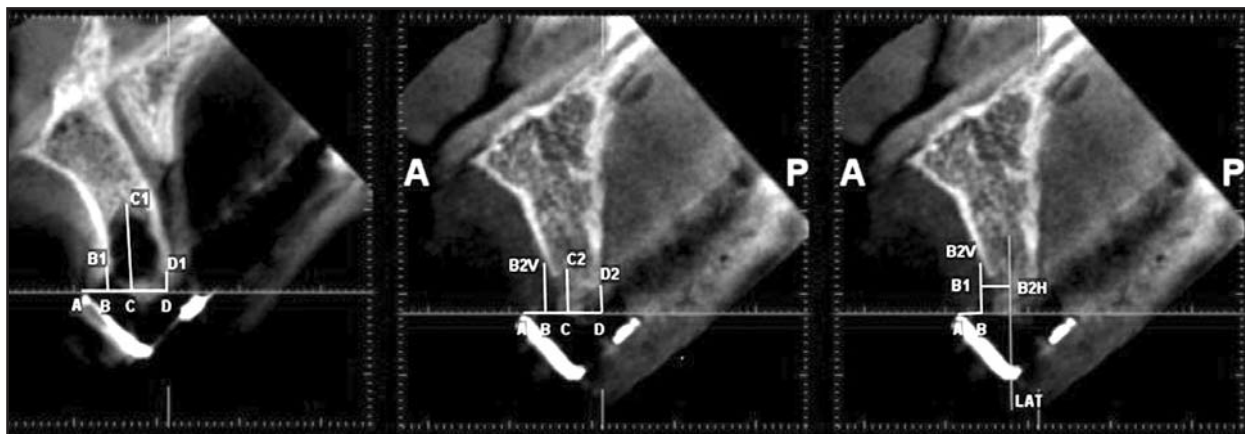
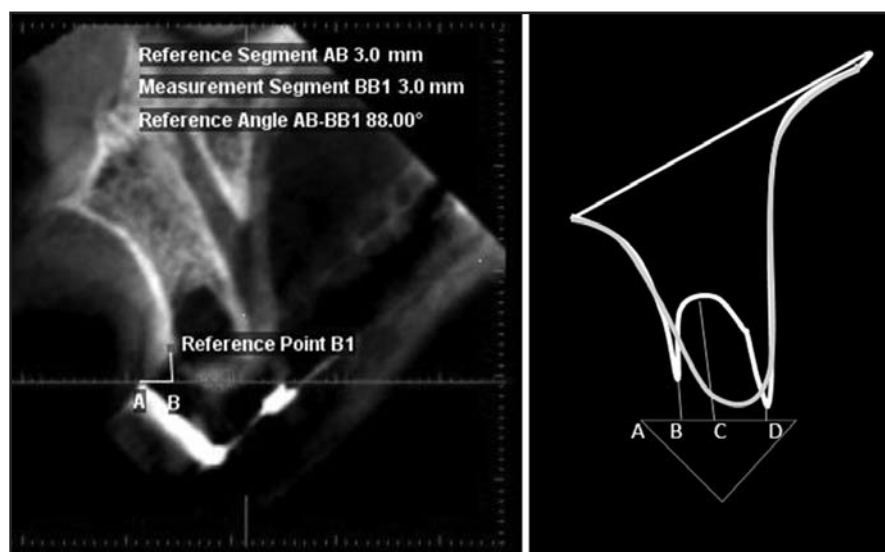
Point B2H (horizontal displacement of buccal bony crest) was determined where a line originating at point B1 and perpendicular line LAT intersects the alveolar ridge. Horizontal displacements in the mid-crestal or lingual bony crest (Fig.4 a,b,c) were not measured.

**Backtrack Measurement**

**Validation Method**

For each subject, the apex of a tooth next to the extraction socket was selected as a fixed predetermined anatomical reference point. This point was named REF3. Two segments and one angle were

*Fig. 3: Vestibular measurement of the alveolar ridge: Reference Segment AB, Measurement Segment BB1 and Reference Angle AB-BB1 equal to the angle MRA. M.*



*Fig. 4: Vertical and horizontal measurements performed at baseline and 6 months after tooth extraction.*

measured and recorded to determine the spatial location of the REF3 point relative to the radiopaque marker. Following these coordinates backwards should lead to the same location of reference point REF3.

Initially, the plane of reference was aligned as described above. A reference point named REF1 was marked along the hypotenuse (line a). This point was arbitrarily established at 10 mm lingual to point A.

Once the image was tridimensionally aligned and REF1 point established, the three planes – horizontal (blue), sagittal (red) and frontal (green) – were positioned at the level of the root apex selected as a landmark and called REF3.

The sagittal plane was then moved sideways until it was perfectly realigned with the radiopaque marker.

A reference point (REF2) was established at the intersection between the repositioned sagittal plane (aligned with the radiopaque marker) and the other two planes. The distance between the apex of the tooth (REF3) and point REF2 was measured and recorded. This segment, named REF2-REF3, ran perpendicular to the sagittal plane.

Along the sagittal plane, a segment joining points REF1 and REF2 was marked and measured (REF1-REF2). The angle between the hypotenuse (line a) and this segment was recorded (Fig.5).

Backtrack analysis was performed 1 week later, and consisted of realigning the sagittal plane with the radiopaque marker, determining the position of REF1, redrawing segment REF1-REF2 taking in account its angulation respective to line a. It was thus possible to re-establish position REF2. Finally

the position of REF3 (apex) was determined by redrawing segment REF3-REF1.

To determine the accuracy of this backtrack re-establishment of the reference point, the distance was measured between the real tooth apex and the obtained REF3.

## RESULTS

When two separate scans were taken six months apart, the same anatomical points of reference were easily found in the baseline and final measurements. The backtrack analysis determined an average within-examiner discrepancy between the two measurements from the same CT scan of 0.19 mm, SD +/- 0.05. By using this method, a reference point in a CT scan can be accurately traced back and located in a second CT scan taken six months later. Additionally, the novel method presented herein opens the possibility of calculating dimensional changes that occur in the alveolar ridge over time, such as post-extraction alveolar resorption or bone gained after different augmentation procedures.

## DISCUSSION

Throughout history, different techniques have been developed to preserve post-extraction sockets, in order to limit bone resorption as described above. The most popular studies in the literature carried out in humans and animals are those where bone fillers, guided bone regeneration techniques with absorbable and non-absorbable membranes were used, and implants were placed immediately after tooth extraction<sup>8-11</sup>.

Lekovic et al. used absorbable and non-absorbable membranes on post-extraction sockets and found pos-

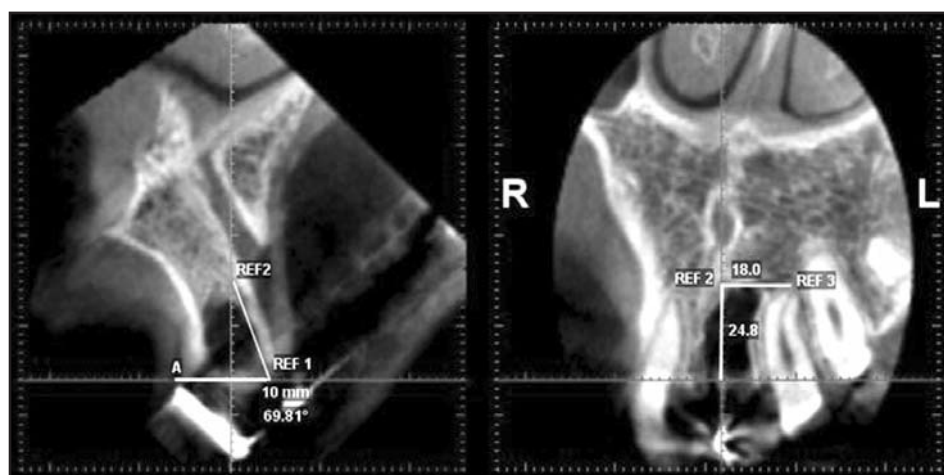


Fig. 5: Backtrack Measurement Validation Method.

itive results in terms of dimensional preservation<sup>12, 13</sup>. Isaella et al. presented similar results in humans in a clinical and histological evaluation using FDDBA and a collagen membrane<sup>14</sup>. Artzi et al. used bovine hydroxyapatite in 15 patients and performed histological analyses at 9 months post-extraction<sup>15</sup>. They concluded that the application of the bone filler is a suitable technique for preserving the alveolar bone structure. Araujo et al. and Fickl et al. in studies conducted in dogs, arrived at similar conclusions, showing that although bone fill in the alveolar socket is improved with bone grafting materials, partial resorption of the buccal alveolar crest is inevitable<sup>16</sup>.

Controversy thus arises regarding the possibility of maintaining the initial alveolar bone ridge morphology. New trends in esthetic implant dentistry advocate full preservation of the buccal bone crest height in order to provide stable support to the gingival margin<sup>17</sup>. Clinically, it has been challenging so far to establish precisely the location of the original bone crest once resorption has occurred.

Different measurement methods have been published in the literature for identifying and quantifying dimensional changes that occur in post-extraction sockets, with or without the application of biomaterials. Schropp used study models and standardized intraoral and subtraction radiography to evaluate 46 patients over a 12-month period. Bidimensional intraoral radiographies allowed only mesiodistal measurements and there were limitations in the application of subtraction radiography techniques<sup>18</sup>. In 2008, Fickl et al. evaluated dimensional changes in post-extraction sites in five beagle dogs by scanning

models obtained before treatment, at 2 months and 4 months post-extraction. Authors described limitations when trying to observe changes in the different alveolar ridge walls<sup>19</sup>. Nevins presented a method for measuring alveolar ridges by performing CT scans on 36 patients immediately after extraction, at 30 and 90 days<sup>20</sup>. He took the sinus floor as measurement reference because the study was performed on antero-superior teeth and there was no reference that allowed the location of the same point horizontally in subsequent scans.

The method presented in this study proved to be simple, reproducible and effective, allowing the identification of the same point in space at different CT scans with a high degree of accuracy. Through the implementation of this measurement system it was possible to observe changes and bone formation in alveolar ridges post-extraction in all three planes. Greater knowledge of the healing and remodeling of the alveolar process will enable more effective selection of techniques and better timing of implant placement in post-extraction alveoli.

## CONCLUSION

The measurement method presented herein proves reliable in finding the same point in space at different CT scan studies, allowing the identification of dimensional changes that occur in the alveolar ridge after extraction. Atraumatic extractions and the displaced flap for alveolar primary closure resulted in greater bone resorption in the vestibular crest than in the palatal-lingual crest, in both vertical and horizontal direction.

## ACKNOWLEDGMENTS

This work was supported by a grant from the Argentine Society of Periodontology, Buenos Aires, Argentina. The study was approved by the Facultad de Odontología, Universidad de Buenos Aires Ethics Committee.

## REFERENCES

1. Atwood DA Some clinical factors related to the rate of resorption of residual ridges. *J Prosthet Dent* 1962;12: 441-450.
2. Johnson K. A study of the dimensional changes occurring in the maxilla after tooth extraction. Part I. Normal healing. *Aust Dent J* 1963;8:428-433.
3. Boyne PJ. Osseous repair of the postextraction alveolus in man. *Oral Surg Oral Med Oral Pathol* 1966;21:805-813.
4. Pietrokovski, J, Massler M. Alveolar ridge resorption following tooth extraction. *J Prosthet Dent* 1967;17:21-27.
5. Amler MH. The time sequence of tissue regeneration in human extraction wounds. *Oral Surg Oral Med Oral Pathol.* 1969;27:309-318.
6. Chen S. T., Wilson T. G. Jr., Hämmerle C.H. Immediate or early placement of implants following tooth extraction: review of biologic basis, clinical procedures, and outcomes. *International J Oral Maxillofac Implants* 2004;19:12-25.

## CORRESPONDENCE

Dr. Hernan Bonta  
Department of Periodontology  
M.T. de Alvear 2142, 17 "A"  
C1122AAH Ciudad Autónoma de Buenos Aires, Argentina  
E-mail: hernanbonta@yahoo.com.ar

7. Greenstein G, Greenstein B, Cavallaro J, Elian N, Tarnow D. Flap advancement: Practical techniques to attain tension-free primary closure. *J Periodontol* 2009;80:4-15.
8. Beker W, Cameron C, Sennerby L, Urist M, Becker B. Histologic findings after implantation and evaluation of different grafting materials and titanium micro screws into extraction sockets: Case reports. *J Periodontol* 1998;69:414-421.
9. Araújo MG, Sukekava F, Wennström JL, Lindhe J. Ridge alterations following implant placement in fresh extraction sockets: An experimental study in the dog. *J Clin Periodontol* 2005;32: 212-218.
10. Melloning JT, Triplett RG. Guided tissue regeneration and endosseous dental implants. *Int J Periodontics Restorative Dent* 1993;13:108-119.
11. Simion M, Dahlin C, Trisi P, Piattelli A. Qualitative and quantitative comparative study on different filling materials used in bone tissue regeneration: A controlled clinical study. *Int J Periodontics Restorative Dent* 1994;14:198-215.
12. Lekovic V, Kennev EB, Weinlaender M, et al. A bone regenerative approach to alveolar ridge maintenance following tooth extraction. Report of 10 cases. *J Periodontol* 1997;68:313-323.
13. Lekovic V, Camargo PM, Klokkevold PR, et al. Preservation of alveolar bone in extraction sockets using bioabsorbable membranes. *J Periodontol* 1998;69:1044-1049.
14. Iasella J, Greenwell H, Miller R. Hill M, Drisko C, Bohra A., Scheetz, J. Ridge preservation with freeze-dried bone allograft and a collagen membrane compared to extraction alone for implant site development: a clinical and histologic study in humans. *J Periodontol* 2003;74:990-999.
15. Artzi Z, Tal H, Davan D. Porous bovine bone mineral in healing of human extraction sockets. Part 1: Histomorphometric evaluation at 9 months. *J Periodontol* 2000;21:1015-1023.
16. Araújo MG, Linder E, Wennström J, Lindhe J. The influence of Bio-Oss Collage non healing of an extraction socket: An experimental study in the dog. *Int J Periodontics Restorative Dent*.2008;28:123-135.
17. Carmagnola D., Adriaens P, Berglundh T. Healing of human extraction sockets filled with Bio-Oss. *Clin Oral Implants Res* 2003;14:137-143.
18. Schropp L, Wenzel A, Kostopoulos L, Karring T. Bone Healing and Soft Tissue Contour Changes Following Single-Tooth Extraction: A Clinical and Radiographic 12-Month Prospective Study. *Int J Periodontics Restorative Dent* 2003;23:313-323.
19. Fickl S, Zuhr O, Wachtel H, Stappert CFJ, Stein JM, Hu"rzeler MB. Dimensional changes of the alveolar ridge contour after different socket preservation techniques. *J Clin Periodontol* 2008;35:906-913.
20. Nevins M, Camelo M, De Paoli S, Friedland B, Schenk R K, Parma-Benfenati S, Simion M, Tinti C, Wagenberg B. A study of the fate of the buccal wall of extraction sockets of teeth with prominent roots. *Int J Periodontics Restorative Dent* 2006;26:19-29.