

# USE OF 3D CARTILAGE SCAFFOLDS FOR THE STABILIZATION OF IMPLANTS AND BONE REGENERATION WITH THE FIT-LOCK TECHNIQUE

Giovanni Falisi<sup>1</sup>, Massimo Galli<sup>1</sup>, Pedro Vittorini-Velasquez<sup>2</sup>, Juan C. Gallegos-Rivera<sup>3</sup>, Roberto Minasi<sup>1</sup>, Alberto De Biase<sup>1</sup>, Carlo Di Paolo<sup>1</sup>

<sup>1</sup> Department of Oral and Maxillo Facial Sciences, Sapienza University of Rome.

<sup>2</sup> Maxillo-facial Clinic Cochabamba, Bolivia.

<sup>3</sup> Department of Dentistry, Municipal Japanese University Hospital, Santa Cruz de la Sierra, Bolivia.

## ABSTRACT

*The surgical procedures for implant applications on the lateral-upper areas depend on sinus pneumatization and availability of the residual bone.*

*In these cases, autologous bone grafting remains the gold standard. Nevertheless, because of the morbidity associated to the donor site and the post-surgical complications, several alternative bone substitutes have been introduced, which, however, imply additional costs and show limited osteoinductive properties.*

*Such limitations can be compensated with new regeneration strategies for biological and mechanical tissue restoration, a subject which has been addressed by tissue engineering in recent years.*

*The authors present a new therapeutic option for implant application in the upper maxilla with bone availability less than 4 mm by using 3D scaffolds obtained from antigen-free porcine cartilage in the fit-lock technique.*

*A longitudinal study on 18 consecutive cases was performed, with a 95.2% success rate one year after the implant.*

*The advantages of this new technique are: 1) Functional and anatomical recovery of the maxillary antrum, 2) Immediate application of the implants; 3) Reduction of surgical times; 4) Absence of patient morbidity; 5) Local anesthesia; 6) Use of implants with a diameter > 4 mm.*

**Keywords:** bone regeneration, dental implants

## EL USO DE ANDAMIO CARTILAGINOSO 3D PARA LA ESTABILIZACIÓN DE LOS IMPLANTES Y LA REGENERACIÓN ÓSEA EN LA TÉCNICA DE BLOQUEO DE IMPLANTE

### RESUMEN

*Los procedimientos quirúrgicos para la aplicación de los implantes en los sectores latero superiores, están condicionadas por la neumatización del seno y la disponibilidad del hueso residual.*

*En estos casos el injerto de hueso autólogo permanece como la mejor opción, pero a causa de la morbilidad asociada al sitio donante y a las complicaciones post quirúrgicas, se pusieron a disposición diversas alternativas de sustitutos óseos, que implican sin embargo un aumento de los costos económicos y con limitadas propiedades osteoinductivas.*

*Tales defectos pueden ser compensados con nuevas estrategias de regeneración biológica y mecánica de los tejidos a los cuales fue dirigida la ingeniería biológica y mecánica en los últimos años.*

*Se presenta una nueva posibilidad terapéutica en la aplicación de los implantes en el maxilar superior con disponibilidad ósea inferior a los 4 mm, mediante la utilización de andamios 3D confeccionados en cartilago de cerdo libre de antígenos obtenido según la técnica Fit-Lock.*

*Se realizó un estudio longitudinal en 18 casos consecutivos evidenciando al cabo de un año de la carga implantológica, un éxito del 95,2%.*

*Las ventajas en esta nueva técnica son: 1) La recuperación funcional y anatómica del antro del maxilar 2) La aplicación inmediata de los implantes; 3) Reducción de los tiempos quirúrgicos; 4) Ausencia de morbilidad para el paciente; 5) Uso de anestesia local; 6) Uso de implantes con diámetros superiores a los 4 mm.*

**Palabras Clave:** regeneración ósea, implantes dentales

### INTRODUCTION

The use of implants in common practice and increasing patient demand for implant-supported prostheses have led to an increased need to use different techniques for regenerative purposes in situations of poor bone availability<sup>1,2</sup>.

Surgical procedures for implant applications on the lateral-upper areas depend on sinus pneumatization and the availability of residual bone.

An analysis of the international literature shows that when bone availability is less than 4 mm, as in the Misch IV classification, it is necessary to proceed

firstly with a reconstructive-regenerative phase, and then with a successive surgical phase for implant insertion<sup>3,4</sup>.

In these cases, autologous bone remains the gold standard. However, because of post-surgical complications, morbidity and sometimes insufficient bone availability in the harvest area, clinicians often opt for alternate regenerative techniques and materials which do not have osteoinductive properties<sup>5,11</sup>.

The review of international literature reveals that in the recent years, tissue engineering has focused on bone reconstruction techniques with 3D scaffolds for *in vitro* and *in vivo* regenerative strategies, in order to achieve biological and mechanical tissue restoration<sup>12-16</sup>.

The main advantages of these materials are their potential low immunogenicity, bioactive behavior and ability to interact with host tissues<sup>17,18</sup>.

Furthermore, natural 3D scaffolds of animal origin contain collagen, fibrinogen, chitosan and hyaluronic acid, compounds that provide the capacity to interact with the host tissues<sup>17,19</sup>.

In general, the required scaffold characteristics are:

- 3D structure to provide a temporary skeletal support until neo-tissue formation<sup>20,21</sup>.
- Low or absent antigenicity to avoid antibody reactions.
- Biodegradability, an essential factor for resorption by the surrounding tissues, without the need for surgical removal.
- Resorption speed rate, through which the degradation occurs, coinciding as much as possible with the new tissue formation.
- Structural integrity, able to support a mechanical stress.
- Porosity, to facilitate the seeding and/or spread of cells and nutrients throughout the entire structure<sup>22-26</sup>.

Although the authors have previously described an implant application technique for maxillary sinus augmentation with autologous bone, they propose the use of an antigen-free pig cartilage 3D scaffold (Condrotek, TecnoSS Ltd.) as a substitute for autologous bone harvest, either as an implant stabilizer or bone tissue regenerating material with the fit-lock technique<sup>27</sup>.

The aim of this longitudinal study was to evaluate the effectiveness of this method, focusing on implant stability and regenerative capacity.

To this end, a 1-year prospective follow-up study was performed on a sample of 18 subjects undergoing 21 great sinus augmentation and 41 Tekka implant applications.

Resonance frequency (Osstell mentor) was used to evaluate the degree of stability, and Cone Beam Computed Tomography (CT) was used to evaluate the degree of regeneration, taking as a reference the histomorphometric data performed on animals.

## MATERIALS AND METHODS

About 50 patients were admitted to the Department of Dental Sciences of the "Sapienza University" of Rome and the Japanese municipal hospital of Santa Cruz de la Sierra between March 2012 and December 2012 for implant-supported prosthetic rehabilitation of the posterior upper areas.

All patients were screened according to our clinical implant protocol for prosthetic rehabilitation. During this time, 18 patients were included in the study according to the following inclusion and exclusion criteria.

### *Exclusion criteria:*

- Poor oral hygiene
- Acute or chronic sinusitis in the maxillary sinus
- Patients with absolute risk factors
- Patients subject to Cadwell Luc treatments
- Patients subject to radiotherapy
- Patients with bone height greater than 4mm.

### *Inclusion criteria:*

- Radiological bone height less than 4 mm.
- Obtained patient consent to participate to the study
- Obtained patient consent to undergo periodical clinical follow-up.

Twenty out of 50 patients were excluded. Of the remaining 30 patients, 10 did not provide informed consent and 2 refused to undergo the follow-up. Thus, the remaining group was composed of 18 patients.

The group was composed of 11 males with mean age 47.7 years and 7 females with mean age 48.5 years, for a total of 21 great sinus augmentations and 41 implants inserted.

In all patients we utilized Tekka dental implants in Grade 5 titanium, with a cylindrical-conical shape with increasing thread depth (Condensing Thread) and a sandblasted and acid etched SA2 surface tre-

atment consisting of a blasting with 260 micron corundum particles followed by a double chemical attack in an acid bath.

The total number of implants was 41, distributed as follows: 2 implants in zone 14; 3 implants in zone 15; 9 implants in zone 16; 7 implants in zone 17; 1 implants in zone 24; 5 implants in zone 25; 8 implants in zone 26 and 6 implants in zone 27.

The measurements of the implants were as follows: 24 implants with 3.5 mm diameter and 11.5 mm height; 15 with 4mm diameter and 11.5 mm height; 2 with 3.5 mm diameter and 13 mm height.

In our implant surgical protocol, we used porcine antigen-free cartilage 3D scaffolds (Condrotek of TecnoSS Ltd.) as a graft substitute in order to gain implant stability and osteoconductive properties.

The choice of this scaffold was based on its physical and mechanical properties fulfilling the requisites, and on *in vivo* histomorphometric results<sup>16,21,25,26</sup>.

All implants were subject to evaluations of resonance frequency during the different follow-up periods.

The Osstell Mentor (Osstell instrument, Integration Diagnostics AB, Gothenburg, Sweden) was used for measurements, at time of insertion (time zero, T0), at six months (time 1, T1) and at 12 months (time 2, T2) after progressive loading<sup>28,29</sup>.

### **Operative protocol**

Two hours before surgery, patients are treated pharmacologically with 2g amoxicillin and clavulanic acid, to prevent surgical site infections (SSI).

Asepsis of the surgical field: intraoral with chlorhexidine gluconate 0.2% mouthwash for 2 minutes, and extraoral with povidone (polyvinyl pyrrolidone, PVP).

Isolation of the operative field with sterile surgical drapes.

Local anesthesia with mepivacaine hydrochloride (1:100.000 IU) in the plexic and troncular maxillary area (retromolar trigone, palatal vestibular and retroincisive canal).

1. Flap design, primary crestal incision and secondary full-thickness releasing incisions (trapezoidal flap).
2. Flap detachment with Freeman periosteal elevator.
3. Exposure of the vestibular cortical malar bone surface up to the retromolar tuberosity.
4. Osteotomy of the vestibular wall of the maxillary sinus with oscillating saw.

5. Detachment of the osteotomised wall with the exposure of Schneider membrane. The Bony Window fragment is placed in a sterile container with physiological solution to prevent dehydration.
6. Detachment of the Schneider membrane is performed starting from the back portion to pass with gentle movements to the front and then inferior portions to achieve complete detachment and exposure of the bone portion of maxillary sinus medial wall.
7. Cavity rinse with antibiotic solution (gentamicin 80 mg.)
8. Preparation of the undersized alveolar surgical implant socket.
9. Rehydration of the 3D scaffold with antibiotic solution.
10. Scaffold insertion in the maxillary sinus keeping it stable with straight tissue tweezers until the complete implant seating with a low speed handpiece 360/1.
11. Filling of the spaces with collagen-based antigen-free bovine bone (MP3 TecnoSS SRL) filling material.
12. Bony Window Repositioning.
13. Separated point suture.

### **Statistical methods**

- Test of normality for stability measure distribution (Kolmogorov-Smirnov test)
- Descriptive statistics of stability measures: measures of central tendency (mean, median, mode) and variability (variance, standard deviation, standard error, quartile deviation)
- Non-parametric analysis of variance Friedman test
- *Post hoc* test

*Objective:* to determine whether the stability of the inserted implants, as measured by “the implant stability quotient” (ISQ), increases progressively and in a statistically significant manner from the time of insertion (ISQ T0) up to six (ISQ T1) and 12 months (ISQ T2) after insertion.

### **RESULTS**

The overall results show only two implant losses, caused in one case by the temporary removable prosthesis and in the other by a post-surgical infection occurring 15 days from insertion.

As for the other 39 implants, no complications were observed during the course of the study.

The Kolmogorov-Smirnov test performed on the implant stability measures detected at times T0, T1 and T2, reveal an approximately normal distribution ( $P > 0.20$ ).

In detail, we compared the implant stability values at the three time points using the non-parametric Friedman test.

The values (mean and median) of implant stability increase progressively over time, i.e., T2 ISQ values are on average higher than T1 ISQ values and the latter are on average higher than those at T0. (Table 1)

**Table 1: Descriptive statistics of the three implant stability measures.**

Variable	ISQ T0	ISQ T1	ISQ T2
Valid N	39	39	39
Mean	39.666	47.153	60.615
Median	40	47	60
Mode	Multiple	51	59
Frequency of Mode	5	7	8
Minimum	32	40	52
Maximum	46	56	69
Lower Quartile	37	45	58
Upper Quartile	43	49	63
Variance	11.385	10.975	14.4
Std. Dev.	3.374	3.312	3.794
Coef. Var.	8.506	7.025	6.26
Standard Error	0.540	0.530	0.607

ISQ= implant stability quotient

Values (mean and median) of implant stability increase progressively over time, i.e. the ISQ T2 values are on average higher than ISQ T1 values and these latter are on average higher than those of ISQ T0.

**Table 2: Friedman ANOVA and Kendal Coeff. of Concordance.**

Variable	ISQ T0	ISQ T1	ISQ T2
Average Rank	1	2	3
Sum of Rank	39	78	117
Mean	39.666	47.153	60.615
Std. Dev.	3.374	3.312	3.794

ISQ= implant stability quotient

ANOVA Chi Sqr.(N=39, df=2)=78,0 p=0.000

Coeff. of Concordance= 1.000 Aver.Rank r=1.000

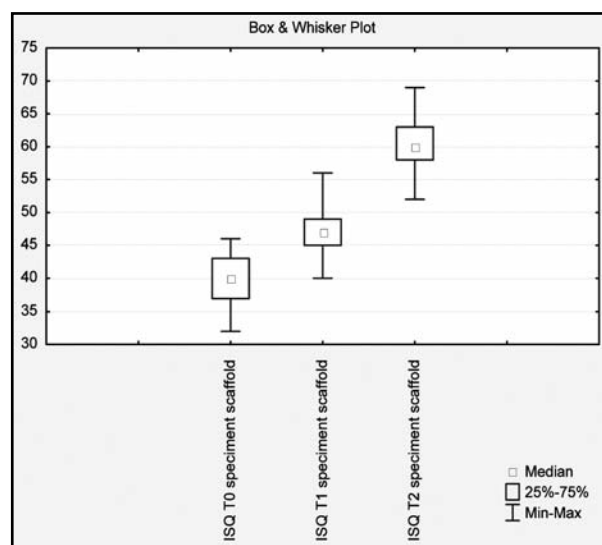
ANOVA Friedman test shows that the differences between the median ISQ values registered at the three time points are statistically significant.

ANOVA Friedman test shows that the differences between the median ISQ values registered at the three time points are statistically significant (Table 2).

Comparison between the ISQ values recorded at times T0, T1, and T2. The smallest squares at the center of the box represent the median values, the box plots represent the values comprised between the lowest and the highest quartile, while the vertical axes indicate the minimum and maximum values recorded (Fig. 1). A significant value obtained with the Friedman test indicates that at least one of three examined conditions is significantly different from the others. However, this test does not show which condition is different and how many conditions differ from the others. So, in order to determine which condition differs from the others, a post hoc test with a critical Z value of 2.394 is applied.

The z values of the three possible comparisons between conditions are the following: ISQ T0 vs. T1 ISQ,  $z = 4.416$ ; ISQ T0 vs. T2 ISQ,  $z = 8.832$ ; ISQ T1 vs. T2 ISQ,  $z = 4.416$ .

Since all z values exceed the abovementioned critical value, we conclude that the differences between the three conditions are all statistically significant. Moreover, this result is further confirmed after a control parametric analysis (ANOVA for repeated measures and t-test for dependent data).



*Fig. 1: Comparison between the ISQ values recorded at times T0, T1, and T2. The smallest squares at the center of the box indicate the median values, the box plots indicate values comprised between the lowest and the highest quartile, while the vertical axes indicate the minimum and maximum recorded values.*

## DISCUSSION

Case studies on implant survival in posterior lateral areas type SA4 reported in literature ranges between 90 and 97%.

These data are influenced by several factors (Del Fabbro 2004):

- The survival of autologous bone alone is, for example, about 87.70% while in combination with bone substitutes it is about 94.88%, and when only bone substitutes are used, survival is about 95.98%;
- Implant production methodology. The survival of non-treated implants is about 85.6%, while if implants are treated superficially and made rough, the percentage rises to 95.8%;
- Implant insertion time does significantly influence implants if applied in the same surgical time or if when regeneration is complete, in fact, in the first case the survival rate is 92.17%, while in the second it is 92.93%<sup>30</sup>.

Some surgical protocols in international literature suggest that when bone availability is thinner than 4 mm, as in the Misch IV classification, it is necessary to intervene with a first reconstructive-regenerative phase and then proceed to a second surgical phase of implant insertion<sup>3,4</sup>.

These protocols are justified by the fact that some authors claim that survival is also influenced by the quality and density of the bone, which is reduced in these areas and may therefore threaten implant stability<sup>29,31</sup>.

Nedir et al., in 2009, proposed one-stage surgery with simultaneous insertion of implants in patients with atrophic maxilla without grafting, provided that primary stability was guaranteed<sup>32</sup>.

Other authors later proposed the contextual implant placement, with a wider sample without filling or with PRF (platelet-rich fibrin) with 100% success in situations of lower bone availability, in order to reduce the surgical steps<sup>33,34</sup>.

The technique described seems to ensure a good success rate (95.2% one year after insertion) in

Misch IV class cases with simultaneous implant insertion.

The technique allows immediate implant stabilization, a result also associated with the innovative implant design which certainly improves the performance in cases of reduced bone density.

Compared to similar techniques, the one described herein appears to be simpler and more reproducible. In addition, it is not operator-dependent and requires less biological and economic efforts from the patient, considerably reducing the prosthetic rehabilitation period.

The results indicate that the stability of implants inserted via the Fit-lock 3D scaffold technique increases progressively over time in a statistically significant manner.

That is, the stability recorded one year post-insertion (ISQ T2) is significantly higher than that recorded after six months (ISQ T1) and the latter is significantly higher than that recorded at the time of implant insertion (ISQ T0).

Even in the *post hoc* analysis, the differences between the three conditions are statistically significant.

The given ISQ value is in line with the safety values reported by other authors, which allow different implant loading according to the biological times<sup>28,29</sup>.

As has been documented, problems occur when, in cases of dental-implant incompatibility, an onlay graft is necessary<sup>27</sup>.

This procedure certainly represents a therapeutic option, given the clinical results comparable to other techniques described in literature<sup>35,36</sup>.

In view of these results, the authors confirm that primary stability is the basic requirement to ensure proper implant healing and demonstrate that the fit-lock technique enables this to be achieved, even in conditions of reduced bone availability.

Given the small number of patients, additional histomorphometric analysis on a larger cohort of samples is recommended.

## ACKNOWLEDGMENTS

We thank Tekka Implant Global D for the donation of all implant material used, Tecness SRL the donation of the scaffold, Prof. Claudio Rastelli and Dr. Massimo Vullo for participating in the interventions.

## REFERENCES

1. Razavi R, Zena RB, Khan Z, Gould AR. Anatomic site evaluation of edentulous maxillae for dental implant placement. *J Prosthodont* 1995;4:90-94.

## CORRESPONDENCE

Dr. Giovanni Falisi  
Via del Vivaio 19- 00172 Rome - Italy  
g.falisi@tiscali.it

2. Wailan D. Chan, Hiran Perinpanayagam, Harvey A. Goldberg, Graeme K. Hunter, S. Jeffrey Dixon; Gildo C. Santos Jr., Amin S. Rizkalla. Tissue engineering scaffolds for the regeneration of craniofacial bone. *J Can Dent Assoc* 2009;75:373-377.

3. Misch CE. Maxillary sinus augmentation for endosteal implants: organized alternative treatment plans. *Int J Oral Implantol* 1987;4:49-58.
4. Tischler M, Misch CE. Extraction site bone grafting in general dentistry. Review of applications and principles. *Dent Today* 2004;23:108-113.
5. Jung JH, Choi BH, Jeong SM, Li J, Lee SH, Lee HJ. A retrospective study of the effects on sinus complications of exposing dental implants to the maxillary sinus cavity. *Oral Surg Oral Med Oral Pathol Oral Radiol Endod* 2007;103:623-625.
6. Doud Galli SK, Lebowitz RA, Giacchi RJ, Glickman R, Jacobs JB. Chronic sinusitis complicating sinus lift surgery. *Am J Rhinol* 2001;15:181-186.
7. McDermott NE, Chuang SK, Woo VV, Dodson TB. Maxillary sinus augmentation as a risk factor for implant failure. *Int J Oral Maxillofac Implants* 2006;21:366-374.
8. Li J, Wang HL. Common implant-related advanced bone grafting complications: classification, etiology, and management. *Implant Dent* 2008 ;17:389-401.
9. Galindo-Moreno P, Avila G, Fernández-Barbero JE, Mesa F, O'Valle-Ravassa F, Wang HL. Clinical and histologic comparison of two different composite grafts for sinus augmentation: a pilot clinical trial. *Clin Oral Implants Res* 2008 ;19:755-759.
10. Hallman M, Sennerby L, Lundgren S. A clinical and histologic evaluation of implant integration in the posterior maxilla after sinus floor augmentation with autogenous bone, bovine hydroxyapatite, or a 20:80 mixture. *Int J Oral Maxillofac Implants* 2002 ;17:635-43.
11. Boëck-Neto RJ, Artese L, Piattelli A, Shibli JA, Perrotti V, Piccirilli M, Marcantonio E Jr. VEGF and MVD expression in sinus augmentation with autologous bone and several graft materials. *Oral Dis* 2009;15:148-154.
12. Glowacki J, Mizuno S. Collagen Scaffolds for Tissue Engineering. *Biopolymers* 2008;89:338-344.
13. Elisseff J, Ma PX. Scaffolding in tissue engineering. Boca Raton: CRC. E. Book, Downloaded at 15th January 2009, ISBN 1- m57444. 2005;pp. 521-529.
14. Nukavarapu SP, Dorcenus DL. Osteochondral tissue engineering: Current strategies and challenges. *Biotechnol Adv* 2013;31:706-721.
15. Kneser U, Schaefer DJ, Polykandriotis E, Horch RE. Tissue engineering of bone: the reconstructive surgeon's point of view. *J Cell Mol Med* 2006;10:7-19.
16. Mangano C, Piattelli A, Tettamanti L, Mangano F, Mangano A, Borges F, Iezzi G, d'Avila S, Shibli JA. Engineered bone by autologous osteoblasts on polymeric scaffolds in maxillary sinus augmentation: histologic report. *J Oral Implantol* 2010;36:491-496.
17. Yang S, Leong KF, Du Z, Chua CK. The design of scaffolds for use in tissue engineering. Part I. Traditional factors. *Tissue Eng* 2001;7:679-689.
18. Shanti RM, Li WJ, Nesti LJ, Wang X, Tuan RS. Adult mesenchymal stem cells: biological properties, characteristics, and surgical maxillofacial applications. *J Oral Maxillofac Surg* 2007;65:1640-1647.
19. Badylak SF, Freytes DO, Gilbert TW. Extracellular matrix as a biological scaffold material: Structure and function. *Acta Biomater* 2009;5:1-13.
20. Phadke A, Hwang Y, Hee Kim S, Hyun Kim S, Yamaguchi T, Masuda K, Varghese S. Effect of scaffold microarchitecture on osteogenic differentiation of human mesenchymal stem cells. *Eur Cell Mater* 2013; 25:114-129.
21. Chu TM, Warden SJ, Turner CH, Stewart RL. Segmental bone regeneration using a load-bearing biodegradable carrier of bone morphogenetic protein-2. *Biomaterials* 2007; 28:459-467.
22. Chen F, Mao T, Tao K, Chen S, Ding G, Gu X. Bone Graft in the Shape of Human Mandibular Condyle Reconstruction via Seeding Marrow-Derived Osteoblasts Into Porous Coral in a Nude Mice Model. *J Oral Maxillofac Surg.* 2002;60:1155-1159.
23. Salgado AJ, Coutinho OP, Reis RL. Bone tissue engineering: state of the art and future trends. *Macromol Biosci.* 2004;4:743-765.
24. Khaled EG, Saleh M, Hindocha S, Griffin M, Khan WS. Tissue engineering for bone production- stem cells, gene therapy and scaffolds. *Open Orthop J* 2011;5:289-295.
25. Lau TT, Lee LQ, Vo BN, Su K, Wang DA. Inducing ossification in an engineered 3D scaffold-free living cartilage template. *Biomaterials* 2012;33:8406-8417.
26. Kheir E, Stapleton T, Shaw D, Jin Z, Fisher J, Ingham E. Development and characterization of an acellular porcine cartilage bone matrix for use in tissue engineering. *J Biomed Mater Res A* 2011;99:283-294.
27. Vittorini-Velasquez P, Falisi G, Galli M, Gallegos-Rivera JC. Self bone graft and simultaneous application of implants in the upper jawbone. (Fit lock technique). *Acta Odontol Latinoam.* 2011;24:163-167
28. Gupta RK, PadmanabhanTV. Resonance frequency analysis. *Indian J Dent Res* 2011;22:567-573.
29. Nedir R, Bischof M, Szmukler-Moncler S, Bernard J-P, Samson J. Predicting osseointegration by means of implant primary stability. *Clin Oral Implants Res* 2004; 15: 520-528.
30. Del Fabbro M, Testori T, Francetti L, Weinstein R. Systematic review of survival rates for implants placed in the grafted maxillary sinus. *Int J Periodontics Restorative Dent.* 2004;24:565-577.
31. Turkyilmaz I, McGlumphy EA. Influence of bone density on implant stability parameters and implant success: a retrospective clinical study. *BMC Oral Health* 2008; 24:8-32. doi: 10.1186/1472-6831-8-32.
32. Nedir R, Nurdin N, Szmukler-Moncler S, Bischof M. Osteotome sinus floor elevation technique without grafting material and immediate implant placement in atrophic posterior maxilla: report of 2 cases. *J Oral Maxillofac Surg* 2009;67:1098-1103.
33. Rajkumar GC, Aher V, Ramaiya S, Manjunath GS, Kumar DV. Implant placement in the atrophic posterior maxilla with sinus elevation without bone grafting: a 2-year prospective study. *Int J Oral Maxillofac Implants* 2013; 28:526-530.
34. Tajima N, Ohba S, Sawase T, Asahina I. Evaluation of sinus floor augmentation with simultaneous implant placement using platelet-rich fibrin as sole grafting material. *Int J Oral Maxillofac Implants* 2013;28:77-83.
35. Hirsch JM, Ericsson I. Maxillary sinus augmentation using mandibular bone graft and simultaneous installation of implants. *Clin Oral Implants Res* 1991;2:91-96.
36. Khoury F. Augmentation of sinus floor with mandibular bone block and simultaneous implantation: 6 year clinical investigation. *Int J Oral Maxillofac Implants* 1999;14:557-564.