

A RETROSPECTIVE ANALYSIS OF REACTIVE HYPERPLASTIC LESIONS OF THE ORAL CAVITY: STUDY OF 1149 CASES DIAGNOSED BETWEEN 2000 AND 2011, CHILE

Andrea Maturana-Ramírez, Daniela Adorno-Farías, Montserrat Reyes-Rojas, Marcela Farías-Vergara, Juan Aitken-Saavedra

Department of Pathology and Oral Medicine. School of Dentistry. University of Chile, Chile

ABSTRACT

The aim of this study was to determine the relative frequency and distribution of reactive hyperplastic lesions (RHL) of the oral mucosa at the Oral Pathology Institute of the School of Dentistry at the University of Chile.

This was a retrospective study of 1149 biopsies with histopathological diagnosis of RHL, performed between 2000 and 2011. The RHL were classified in 4 groups: fibrous hyperplasia (FH), pyogenic granuloma (PG), peripheral giant-cell granuloma (PGCG) and peripheral ossifying fibroma (POF).

Results: the most frequent RHL was FH (71.1%), followed by PG (21.1%), PGCG (5%) and POF (2.9%). RHLs were more frequent in women (70.7%). The most highly affected age group was the 50- to 59-year-olds (22%). The most frequent location for RHL was maxilla (24.7%), followed by cheek (20.6%), tongue (19.4%) and jaw (18.5%). The most prevalent RHL diagnosis was FH. The most frequently affected sex was female, the most frequent age range was 50-59 years, and the most frequent location, maxilla.

Key words: gingival hyperplasia, giant cell granuloma, pyogenic granuloma, mouth mucosa.

ANÁLISIS RETROSPECTIVO DE LESIONES REACCIONALES HIPERPLÁSTICAS EN MUCOSA ORAL: ESTUDIO DE 1149 CASOS DIAGNOSTICADOS ENTRE EL 2000-2011 EN CHILE

RESUMEN

El objetivo de este estudio fue determinar la frecuencia relativa y distribución de lesiones reaccionales hiperplásticas (LRH) de la mucosa oral, presentes en el registro de biopsias del Servicio de Anatomía Patológica de la Facultad de Odontología, Universidad de Chile.

Este estudio, de tipo retrospectivo consistió en 1149 biopsias con diagnóstico histopatológico de LRH, entre los años 2000-2011. Las LRH se clasificaron en 5 grupos: Hiperplasia fibrosa (HF), granuloma piogénico (GP), granuloma periférico de células gigantes (GPCG) y fibroma osificante periférico (FOP). Los datos de edad y sexo de los sujetos, y de localización y tipo de lesión, fueron obtenidos del registro de biopsias de cada caso.

De las LRH, la lesión más frecuente fue HF (71,1%), seguido de GP (21,1%), GPCG (5%) y FOP (2,9%) respectivamente. Las biopsias de LRH fueron más frecuentes en mujeres (70,7%). El rango etario más afectado fue el de 50 a 59 años (22%). La localización de mayor frecuencia de LRH fue el maxilar superior (24,7%), seguida de mejilla (20,6%), lengua (19,4%), mandíbula (18,5%), labio inferior (9,9%) y labio superior (6,7%). En este estudio, de las LRH el diagnóstico más prevalente fue FH. El sexo más afectado fue el femenino, el rango etario el de 50 a 59 años y la ubicación más frecuente, maxilar superior. Estos resultados en general son concordantes con lo descrito en otros países.

Palabras-clave: hiperplasia gingival, granuloma de células gigantes, granuloma piogénico, mucosa de la boca.

INTRODUCTION

Reactive hyperplastic lesions (RHL) are a group of fibrous alterations of the connective tissue. They usually appear in the oral mucosa in response to injuries¹ such as local chronic irritation or trauma due to the presence of stone, restorations with irregular edges, low-grade traumatism and iatrogenic factors. The mucosa reacts to these irritant factors with local hyperplasia composed of mature collagen, fibroblasts, mineralized tissue, endothelial cells and giant multinucleated cells. These lesions are not

considered neoplasms, but inflammatory hyperplastic reactions².

The accepted classification of oral mucosa RHL includes a wide range of lesions², including fibrous hyperplasia (FH), pyogenic granuloma (PG), fibrous epulis with ossification or peripheral ossifying fibroma (POF) and peripheral giant-cell granuloma (PGCG). The clinical and histopathological characteristics of each are described below.

FH is a solid mass, painless, nodular, with a smooth surface and normal color that can appear at any

location of the oral mucosa. Histologically, it is composed of connective tissue with dense collagen^{2,3}. PG appears clinically as an erythematous mass, painless, smooth, lobulated, fast-growing and bleeding easily when touched. It is associated with trauma, poor oral hygiene and increase in hormonal levels during pregnancy. It generally appears in the gum but also in less usual places such as the lips, tongue and oral mucosa³. Histologically, it is composed of hyperplastic granulation tissue with a marked proliferation of endothelial cells covering the capillary channels and an infiltrate of mixed inflammatory cells².

POF appears only in the gum, beginning in the periodontal ligament. It is considered more an RHL than a neoplasm. Clinically, it appears as a nodular mass, pedunculated or sessile, painless, which usually comes from the interdental papilla, pink or red colored, and may be ulcerated². Histologically, it is composed of cellular fibroblastic tissue and formation of mineralized products: bone, cement-like material or dystrophic calcifications⁴.

PGCG is exclusively a lesion of the gum or the alveolar mucosa. It appears as an increase of nodular volume, painless, red to blue-red colored, pedunculated or sessile. Histologically, it consists of a proliferation of giant multinucleated cells and a proliferation of mesenchymal cells, associated with prominent vascularization, abundant hemorrhage and hemosiderin deposits at the periphery of the lesion. It can also present signs of chronic inflammation and areas of formation of reactive bone and even dystrophic calcifications²⁻⁵.

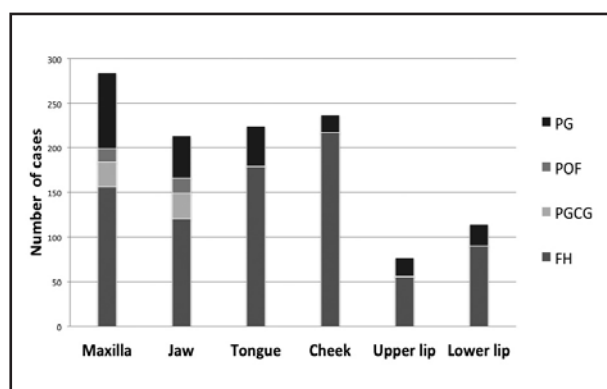


Fig. 1: Distribution of reactive hyperplastic lesions according to gender. FH: fibrous hyperplasia; PGCG: peripheral giant-cell granuloma; POF: peripheral ossifying fibroma; PG: pyogenic granuloma.

There are variations in the prevalence of RHL according to type of lesion, age, gender and affected site¹. In its clinical appearance it is very similar to some neoplasms, making differential diagnosis difficult⁶. Appropriate knowledge of the distribution and frequency of RHL enables better clinical diagnosis of affected patients. These data have been analyzed in countries such as Iran¹, China², Canada³, United States⁴ and India⁵. However, there is no epidemiological record of oral reactional lesions in Chile or the rest of Latin America, so it would be of great interest to research the topic.

The aim of this study was to determine the relative frequency and distribution of the most common RHL of the oral mucosa by analyzing the 2000 to 2011 archives of the Department of Oral Pathology at the School of Dentistry, University of Chile.

MATERIALS AND METHODS

We processed whole biopsies or specimens from the 2000 to 2011 archives of the Department of Pathology and Oral Medicine at School of Dentistry, University Chile. The study included samples with RHL histopathological diagnosis according to the revision in Buchner et al.² The samples were classified into 4 groups: fibrous hyperplasia (FH), pyogenic granuloma (PG), peripheral giant-cell granuloma (PGCG) and peripheral ossifying fibroma (POF). The specimens were analyzed based on their frequency and distribution according to patient age and gender. The anatomic location of the lesion was obtained from the biopsy register for each case. The Stata V10 software was used for data analysis.

RESULTS

Of the 6369 specimens diagnosed between 2000 and 2011 in the registers, 1149 (18%) had RHL. Out of the RHL, 817 (71.1%) were FH, 57 (5%) PGCG, 33 (2.9%) POF and 242 (21.1%) PG.

RHL affected 629 (72.2%) females and 520 (27.8%) males. Regarding the distribution of the RHL by gender, for FH, 238 cases (29.3%) were male and 575 (70.7%) female. For PGCG, 33 cases (51.6%) were male and 31 (48.4%) female. For POF, 15 cases (42.9%) were male and 20 (57.1%) female. For GP, 49 cases (20.7%) were male and 188 (79.3%) female (Fig 1).

Out of all the RHL patients, 37 (3.2%) were 0-9 years old, 83 (7.2%) were 10 to 19 years old, 98 (8.5%) were 20 to 29 years old, 146 (12.7%) were 30 to 39

years old, 225 (19.5%) were 40 to 49 years old, 253 (22%) were 50 to 59 years old, 208 (18.1%) were 60 to 69 years old, 83 (7.2%) were 70 to 79 years old and 16 (1.4%) were over 80 years old (Fig. 2).

The most frequent location of RHL was maxilla, with 284 cases (24.7%), followed by cheek (oral mucosa) with 237 cases (20.6%), tongue with 224 (19.4%), jaw, which includes the gum and/or lower alveolar process, with 213 cases (18.5%), lower lip with 114 (9.9%) and upper lip with 77 (6.7 %) (Fig. 3).

DISCUSSION

The aim of this study was to determine the relative frequency and distribution of the most frequent RHLs in the 2000 to 2011 archives of the Department of Oral Pathology at the School of Dentistry, University of Chile.

RHL frequency

Out of the 6369 specimens, 18.04% had RHL. When comparing this data with other studies, the percentage of RHL compared to total specimens varies from 5% in China⁷, to 6.4% in Canada⁸, 6.7% in Israel² and 48% in Iran¹. Among other reasons, these variations could be explained by the different criteria used in each country or location regarding what lesions should be biopsied. Moreover, many RHLs may have been clinically diagnosed but not biopsied, which does not necessarily lead to appropriate diagnosis and treatment.

Our study found a higher percentage of FH (71.1% of total RHL) than any of the other studies that used similar methodology and RHL classification. The results are closest to ours are Daley et al.⁸ in Canada (61.2%) and Zang et al.⁷ in China (61%).

Although most studies^{2, 7-11} report FH as the most prevalent RHL, authors such as Stableinet et al.¹², Ababneh et al.¹³ and Zarei et al.⁷ report PG as the most prevalent. The percentage of PG with respect to RHL varies from 11.9% in Canada⁸ to 42.8% in USA¹². However, most authors report percentages between 20 and 30%^{2, 9, 14, 15}, in agreement with our results (21.1%). It should be highlighted that in all the studies, including ours, PG was more frequent in women.

Our percentage of POF compared to total RHL was lower (2.9%) than that of most of the other studies, which report percentages varying from 7.2%¹³ to 40%¹⁵. The latter study even categorizes POF as the most frequent RHL.

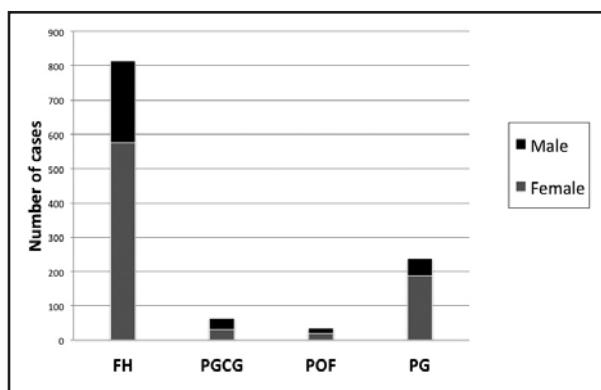


Fig. 2: Distribution of reactive hyperplastic lesions according to location. FH: fibrous hyperplasia; PGCG: peripheral giant-cell granuloma; POF: peripheral ossifying fibroma; PG: pyogenic granuloma.

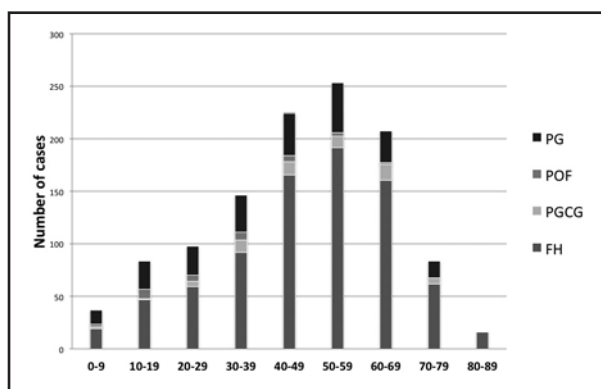


Fig. 3: Distribution of reactive hyperplastic lesions according to age group. FH: fibrous hyperplasia; PGCG: peripheral giant-cell granuloma; POF: peripheral ossifying fibroma; PG: pyogenic granuloma.

In our study, PGCG accounts for 5% of all RHL. The frequencies described in other studies range from 18.7% in Israel² to 1.5% in China⁷.

RHL distribution according to gender

PGCGs were more frequent in males (51.6%), but all the rest of the lesions were more prevalent in females, with 70.7% for FH, 79.3% for PG, and 57.1% for POF. Buchner et al.¹⁶ found similar results in both adults and children, where RHL are also more common in females, except for PGCG. Although Buchner describes differences between genders which are similar to ours, his FH percentage for females is lower than in our study (57.7% vs. 70.7%). Zarei et al.¹⁷, Salum et al.¹⁸, and Kfir et al.⁹, also report a higher RHL frequency in females, except for PGCG, which was higher in males but

without significant differences. Other studies also showed significant predominance of RHL in females^{1, 5, 7, 14, 17, 19}, with the exception of Anneroth et al.²⁰ in Sweden, who found no difference in FH percentage between genders.

RHL distribution according to age group.

The highest RHL prevalence was found in the group of 50- to 59- year-olds. The oldest and youngest groups had the lowest prevalence, with 3.2% in 0- to 9-year-olds and 1.4% in patients over 80 years old.

FH (23.6%) and PG (19.9%) were the most frequent among 50- to 59-year-olds, while PGCG (23.7%) prevailed in 60- to 69-year-olds. These data match those reported in Greece²¹, England²², China⁷, Canada⁸, Sweden²⁰ and USA⁹, where a similar distribution of these lesions was found according to age range. POF (23.8%) was most frequent in 10- to 19-year-olds, in agreement with Buchner et al.², with PG and POF being the most frequent in this age range, with 18.3% and 24.5%, respectively. Other studies^{4, 8, 9, 23}, also report POF as the most frequent lesion in this age range.

In general, our study matches the results reported in most papers on the frequency of RHL in different age ranges, except for PG, which at 19.9 %, mainly affects subjects aged 50 to 59 years, whereas most other papers^{7-9, 11, 18, 20} place it before the age of 30 years.

Distribution according to location

Our study found similar percentages of FH distribution according to location in maxilla and jaw (19.1% and 14.7%, respectively) as studies published in Israel² and USA¹³. However, it is

essential to note that 48.4% of FH were located in soft tissues, with 21.9% on the tongue and 26.6% on the cheek. Naderi⁶ reports similar frequencies, with 54.8% for mandible and maxilla, 20.3% for tongue and 24.9% at other sites. Ala Aghbali¹ found a 83.9% for maxilla and jaw and only 12.8% for cheek and 2.6% for tongue.

As for PGCG, studies carried out in Sweden²⁰, Greece²¹, Iran⁵ and Denmark²⁴ report a higher frequency in the jaw than in the maxilla. Our study shows an equal distribution at both sites (50%-50%), which resembles studies in USA^{9, 23} and England²².

Regarding PG, our results agree with those reported in Israel², USA⁹, India¹¹ and Brazil¹⁸, with this lesion being more prevalent in the maxilla than in the jaw. Higher prevalence in the jaw was only reported in China⁷. Although our study reports greater presence of PG in the maxilla (35.1%) than the jaw (19.4%), we also found 7.7 % of PG in cheek and 18.6 % in tongue.

Our study found slightly greater presence of POF in the jaw (51.5%), which differs from findings in Israel², USA^{4, 9} and China⁷, where greater prevalence was reported in the maxilla.

The differences in frequency in the several series detected when comparing our study to studies in other countries may be explained by the socio-economic and cultural variations, available resources and type of department where the research was conducted. These types of variables should be evaluated in the future in order to associate them with the frequency of the diagnosed pathologies and thus help improve the epidemiological approach in each country carrying out similar studies.

CORRESPONDENCE

Juan Pablo Aitken Saavedra.

Código Postal: 8380492

Sergio Livingstone 943. Independencia. Santiago, Chile.

jaitken@odontologia.uchile.cl

REFERENCES

1. Ala Aghbali A, Vosough Hosseini S, Harasi B, Janani M, Mahmoudi SM. Reactive hyperplasia of the oral cavity: a survey of 197 cases in Tabriz, northwest Iran. *J Dent Res Dent Clin Dent Prospects* 2010;4:87-89.
2. Buchner A, Shnaiderman-Shapiro A, Vered M. Relative frequency of localized reactive hyperplastic lesions of the gingiva: a retrospective study of 1675 cases from Israel. *J Oral Pathol Med* 2010;39:631-638.
3. Gonsalves WC, Chi AC, Neville BW. Common oral lesions: Part II. Masses and neoplasia. *Am Fam Physician* 2007; 75:509-512.
4. Buchner A, Hansen LS. The histomorphologic spectrum of peripheral ossifying fibroma. *Oral Surg Oral Med Oral Pathol* 1987;63:452-461.
5. Motamedi MH, Eshghyar N, Jafari SM, Lassemi E, Navi F, Abbas FM, Khalifeh S, Eshkevari PS. Peripheral and central giant cell granulomas of the jaws: a demographic study.

- Oral Surg Oral Med Oral Pathol Oral Radiol Endod 2007; 103:39-43.
6. Naderi NJ, Eshghyar N, Esfahanian H. Reactive lesions of the oral cavity: A retrospective study on 2068 cases. *Dent Res J (Isfahan)* 2012;9:251-255.
 7. Zhang W, Chen Y, An Z, Geng N, Bao D. Reactive gingival lesions: a retrospective study of 2,439 cases. *Quintessence Int* 2007;38:103-110.
 8. Daley TD, Wysocki GP, Wysocki PD, Wysocki DM. The major epulides: clinicopathological correlations. *J Can Dent Assoc* 1990;56:627-630.
 9. Kfir Y, Buchner A, Hansen LS. Reactive lesions of the gingiva. A clinicopathological study of 741 cases. *J Periodontol* 1980;51:655-661.
 10. Layfield LL, Shopper TP, Weir JC. A diagnostic survey of biopsied gingival lesions. *J Dent Hyg* 1995; 69:175-179.
 11. Shamim T, Varghese VI, Shameena PM, Sudha S. A retrospective analysis of gingival biopsied lesions in South Indian population: 2001-2006. *Med Oral Patol Oral Cir Bucal* 2008;13:414-418.
 12. Stablein MJ, Silverglade LB. Comparative analysis of biopsy specimens from gingiva and alveolar mucosa. *J Periodontol* 1985;56:671-676.
 13. Ababneh KT. Biopsied gingival lesions in northern Jordanians: A retrospective analysis over 10 years. *Int J Periodontics Restorative Dent* 2006;26:387-393.
 14. Al-Khateeb TH. Benign oral masses in a Northern Jordanian population: a retrospective study. *Open Dent J* 2009;3:147-153.
 15. Macleod RI, Soames JV. Epulides: a clinicopathological study of a series of 200 consecutive lesions. *Br Dent J* 1987;163:51-53.
 16. Buchner A, Shnaiderman A, Vared M. Pediatric localized reactive gingival lesions: a retrospective study from Israel. *Pediatr Dent* 2010;32:486-492.
 17. Zarei MR, Chamani G, Amanpoor S. Reactive hyperplasia of the oral cavity in Kerman province, Iran: a review of 172 cases. *Br J Oral Maxillofac Surg* 2007;45:288-292.
 18. Salum FG, Yurgel LS, Cherubini K, De Figueiredo MA, Medeiros IC, Nicola FS. Pyogenic granuloma, peripheral giant cell granuloma and peripheral ossifying fibroma: retrospective analysis of 138 cases. *Minerva Stomatol* 2008;57:227-232.
 19. Awange DO, Wakoli KA, Onyango JF, Chindia ML, Dimba EO, Guthua SW. Reactive localized inflammatory hyperplasia of the oral mucosa. *East Afr Med J* 2009;86:79-82.
 20. Anneroth G, Sigurdson A. Hyperplastic lesions of the gingiva and alveolar mucosa. A study of 175 cases. *Acta Odontol Scand* 1983;41:75-86.
 21. Katsikeris N, Kakarantza-Angelopoulou E, Angelopoulos AP. Peripheral giant cell granuloma. Clinicopathologic study of 224 new cases and review of 956 reported cases. *Int J Oral Maxillofac Surg* 1988;17:94-99.
 22. Mighell AJ, Robinson PA, Hume WJ. Peripheral giant cell granuloma: a clinical study of 77 cases from 62 patients, and literature review. *Oral Dis* 1995;1:12-19.
 23. Eversole LR, Rovin S. Reactive lesions of the gingiva. *J Oral Pathol* 1972;1:30-38.
 24. Andersen L, Fejerskov O, Theilade J. Oral giant cell granulomas. An ultrastructural study of the vessels. *Acta Pathol Microbiol Scand A* 1975; 83:69-76.