

ALVEOLAR DIMENSIONAL CHANGES RELEVANT TO IMPLANT PLACEMENT AFTER MINIMALLY TRAUMATIC TOOTH EXTRACTION WITH PRIMARY CLOSURE

Nelson Carranza¹, Hernan Bonta¹, Ariel F. Gualtieri², Mariana A. Rojas¹, Federico G. Galli¹, Facundo Caride¹

¹Department of Periodontics, School of Dentistry University of Buenos Aires, Buenos Aires, Argentina.

²Department of Biophysics, School of Dentistry, University of Buenos Aires, Buenos Aires, Argentina.

ABSTRACT

The purpose of this study is to evaluate the dimensional changes that occur in the alveolar ridge after minimally traumatic tooth extraction by means of computed tomography (CT), with special focus on the portion of bone supporting the gingival zenith. Twenty subjects with indication for single-rooted tooth extraction and preserved alveolar walls were selected for this study. After a minimally traumatic extraction, two CT scans were performed; the first within 24 hours post-extraction (TC1) and the second 6 months (TC2) later. A radiopaque guide with a radiopaque marker was used to obtain references that enabled accurate measurements over time, in both vertical and horizontal directions. The bone crest immediately apical to the gingival zenith was identified and termed "osseous zenith". The displacement of the osseous zenith in horizontal and vertical direction was analyzed and correlated with several alveolar anatomical variables with the aim of identifying possible predictors for bone remodeling.

Dimensional changes that occur in post-extraction sockets within a 6-month period showed significant vertical and horizontal displacement of the osseous zenith ($p < 0.001$). Mean vertical resorption was 2.1 ± 1.7 mm, with a median of 1.9 mm and a range of 0.2 to 7.5 mm. Mean horizontal resorption was 1.8 ± 0.8 mm with a median of 1.7 mm and a range of 0.6 to 4.4 mm. However, no correlation was found between the width of the facial alveolar crest and the displacement of the osseous zenith.

The results of the present study showed that if the width of the facial crest at the apical-coronal mid-point is less than 0.7 mm, a high degree of displacement of the osseous zenith (> 3 mm) should be expected.

The present study suggests that the width of the alveolar crest at its mid-level, rather than crestal width, may be correlated with the displacement of the osseous zenith.

Key words: tooth socket- tooth extraction- computed tomography.

CAMBIOS DIMENSIONALES EN EL REBORDE ALVEOLAR RELACIONADOS CON LA COLOCACIÓN DE IMPLANTE POSTERIOR A EXODONCIA ATRAUMÁTICA CON CIERRE PRIMARIO

RESUMEN

El objetivo del presente estudio es evaluar los cambios dimensionales que ocurren en el reborde alveolar luego de realizar una exodoncia atraumática mediante tomografía computada, con especial atención en el tejido óseo que soporta el cémit gingival.

Se seleccionaron 20 sujetos con indicación de exodoncia de piezas unirradiculares y que presentaban las paredes alveolares conservadas. Luego de llevar a cabo una exodoncia atraumática se realizaron dos tomografías computadas (TC); la primera dentro de las 24 hs post-exodoncia (TC1) y la segunda a los 6 meses (TC2). Se utilizó una guía radiológica con un marcador radiopaco para obtener medidas precisas en el tiempo, tanto en el plano horizontal como vertical. Se identificó la cresta ósea inmediatamente apical al cémit gingival y se definió como "cémit óseo". Se realizó un análisis del desplazamiento del cémit óseo en el plano horizontal y vertical y se correlacionó con diferentes variables anatómicas

con el objetivo de determinar posibles predictores del remodelado óseo.

Los cambios dimensionales que ocurren 6 meses post-exodoncia mostraron un desplazamiento significativo del cémit óseo ($p < 0.001$). La reabsorción vertical promedio fue de 2.1 ± 1.7 mm con una media de 1.9 mm y un rango de 0.2 a 7.5 mm. El promedio de reabsorción horizontal fue de 1.8 ± 0.8 mm con una media de 1.7 mm y un rango de 0.6 a 4.4 mm. No se halló correlación entre el ancho de la cresta vestibular y el desplazamiento del cémit óseo. Los resultados del presente estudio mostraron que si el ancho de la cresta vestibular en el punto medio (en sentido apico-coronal) es menor a 0.7 mm se puede esperar un desplazamiento del cémit óseo (> 3 mm).

Este estudio sugiere que el ancho de la cresta alveolar en su punto medio podría predecir el desplazamiento del cémit óseo.

Palabras clave: alvéolo dentario, extracción dentaria, tomografía computada.

INTRODUCTION

The alveolar healing process following tooth extraction has been studied throughout the history of dentistry, but has commanded more attention over the past two decades due to the advent of dental implants.

Several authors analyzed the physiological healing process that occurs after tooth extraction and described its remodeling process¹⁻², where the total volume of the socket is markedly reduced and presents resorption of the facial and lingual walls, as well as of the bone filling in its center³. It has been determined that there is more bone resorption on the vestibular than on the lingual or palatal crest of the alveolus⁴. The greatest degree of resorption in post-extraction sockets occurs during the first three to six months after tooth extraction⁵. In one study, bone resorption was reported to be as much as 50% in a vertical direction⁶. Recent systematic reviews agree that there is more bone resorption in a vertical direction than in a horizontal direction^{7,8}. Several clinical trials have demonstrated that socket preservation procedures with bone grafts and guided bone regeneration significantly reduce bone resorption^{9,10}.

Tools for accurate, reproducible measurements of bone changes are necessary to obtain a clear notion of normal bone remodeling. Various techniques have been utilized to measure alveolar remodeling in humans, such as subtraction radiography, intraoperative models, direct measurement at re-entry surgical procedures, and lately, cone beam volumetric tomography (CBVT)^{12,13}.

To obtain accurate measurements, however, it is essential to locate the same reference locations in different CBVT studies taken at different points in time. The authors developed a simple, reproducible, effective method that enables the same point in space to be identified in different CT scans with a high degree of accuracy¹¹.

Many dentists and patients nowadays expect their implant-supported restorations not only to be functionally healthy over time, but also to look like natural dentition. The ability to achieve a biomimetic result, however, has been challenged by the difficulty in obtaining predictable peri-implant gingival morphology. Current understanding and knowledge establish that the stability and precise location of the peri-implant gingival margin is greatly dependent on the position of the underlying

bone crest, among other factors. The most apical point in the facial gingival margin has been defined as the gingival zenith, and its location is of paramount importance in the overall esthetic result¹². Analogously to the gingival zenith, the authors defined the bone crest that gives support to the gingival zenith as the *osseous zenith*, establishing its location as the nearest portion of bone tissue underlying the gingival zenith.

Thus, as esthetic expectations increase, more attention is focused on the remodeling process of the mid-facial bony crest, or osseous zenith. Various studies in animal models demonstrated that regardless of the extraction technique utilized, there is always some degree of resorption of the facial crestal bone¹³. Studies performed on human subjects with CBVT have rarely focused on the displacement of the osseous zenith, and thus we lack information regarding the extent to which this bone crest, which will support the implant facial gingival zenith, moves in apical and lingual directions. There is also insufficient information regarding any predictor of such displacement and alveolar behavior with atraumatic tooth extraction and primary closure with soft tissues.

Osseous zenith displacement may be closely related to the width of the facial crest. It is therefore the aim of this study to determine the displacement of the osseous zenith in vertical and horizontal directions, and to provide a description of dimensional changes in 20 dental alveoli 6 months after atraumatic tooth extraction with primary closure, utilizing a novel measuring technique and CBVT.

Additionally, this report examines the association between several pre-extraction measurements and bone remodeling in an attempt to find variables with predictable value for bone remodeling patterns.

MATERIALS AND METHODS

Twenty subjects who visited the Periodontology Department at the Buenos Aires University School of Dentistry were enrolled in this clinical tomographic prospective study. The inclusion criteria was being systemically healthy. All subjects were older than 21 years and had extraction indications of one or more single-rooted teeth with preserved alveolar bone, with the intention of replacing the tooth with an implant supported prostheses. The diagnosed indications for tooth extractions were caries, endodontic complications, root fracture,

orthodontic, and prosthetic reasons. All patients in the study accepted the clinical procedures and signed approved informed consent. The project was approved by the FOUBA ethics committee.

Exclusion criteria were blood dyscrasia, pregnancy, human immunodeficiency virus, uncontrolled hypertension, requiring antibiotic prophylaxis, being under antibiotic treatment, uncontrolled diabetes, smokers, or fractured teeth with alveolar wall damage.

Diagnostic Phase: A medical, clinical and radiographic history was made for each subject and they all received hygiene instructions, and, if required, periodontal therapy. Study models were obtained to make an acrylic stent to be used as reference marker for taking tomographic measurements. The acrylic guide with a radiopaque element was constructed as previously described¹⁴. Briefly, an "L" shaped metal wire 20 mm long was bent at 90 degrees in the middle, so that both halves measured 10 mm. The wire marker was included in an acrylic structure adapted to a study cast model, and used as the radiographic stent. Special care was taken to place the wire marker in the center of the facial aspect of the tooth, indicating the gingival zenith and the long axis of the tooth.

Surgical Phase: Local anesthesia was applied and careful extractions were performed in all cases in order to preserve the alveolar crests. A periosteal elevator was initially used, followed by application of light traction and slight rotational forces with dental forceps. Following extraction, gentle curettage of the socket was performed to remove any remaining soft tissue. Thorough examination of the integrity of the alveolar walls was corroborated clinically. A lingual or palatal flap was elevated and displaced to perform a primary closure without elevating a vestibular flap to obtain primary closure¹⁴. Simple or mattress sutures and nylon material were used in all cases.

Post-Surgical Care: Sutures were removed 15 days after surgery.

Subjects were treated with amoxicillin 500 mg every 8 hours for 7 days and ibuprofen 600 mg every 8 hours as needed for pain. Regular hygiene of the treated area was interrupted and replaced with a local antimicrobial mouthwash for 3 days (0.12% chlorhexidine digluconate every 12 hrs.).

Tomographic Study: Within 24 hours of the extraction, each patient underwent a computed tomography (TC1) scan with the previously prepared acrylic guide containing the radiopaque reference points in order to standardize measurements at baseline and at 6 months (TC2). The studies were performed with a 3D cone-beam volume CT (Promax 3D, Planmeca, Finland).

Images were analyzed through the Romexis Viewer 2.0.3.R program (Romexis Viewer 2.0.3.R, Planmeca, Finland).

Initial Tomograms

Three easily recognizable anatomical landmarks were identified and traced in the initial tomographic image: the osseous zenith, the lingual bony crest and the alveolus apex. Additionally, the long axis of the tooth (LAT) was traced as described previously (Fig. 1).

The osseous zenith represents the bone underlying the gingival zenith and was defined as the most coronal aspect of the osseous crest at the center of facial aspect of tooth. The alveolus apex was identified as the most apical aspect of the alveolus.

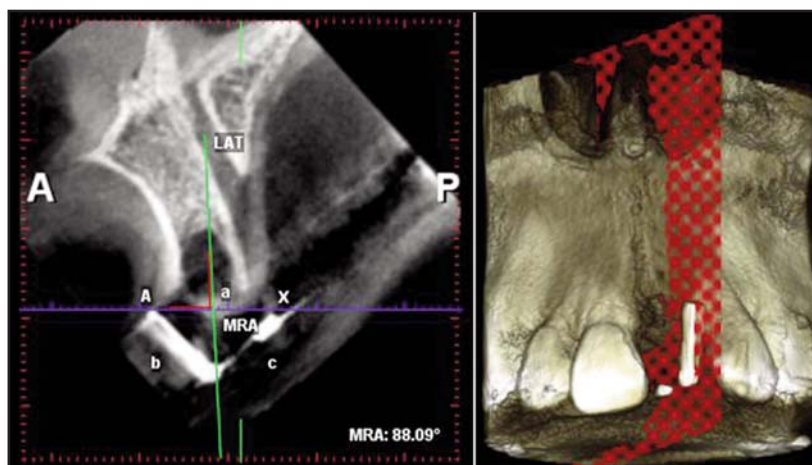


Fig. 1: The radiopaque element was placed such that both tips and angle of the wire marker were aligned with the long axis of the tooth (LAT) extracted. The radiopaque element of the guide was identified on the sagittal plane and the reference points using Romexis Viewer 2.0.3.R. Planmeca.

On tomograms taken immediately after tooth extraction, the osseous zenith, the apex of the alveolus and the lingual crest corresponded to, and were labeled as, point B1, point C5 and point D1 respectively.

Levels of horizontal measurements: Five parallel levels of horizontal measurement were selected as follows.

Firstly, five points were identified and marked along the LAT and labeled with the letter C. The most coronal point (C1) was a point where a segment originating in the bony crest (osseous zenith, B1) intersected the LAT at a 90° angle. The most apical point (C5) coincided with the alveolus apex. Points C2, C3, and C4 were respectively located along the LAT at a 25%, 50% and 75% of the total distance between C1 and C5.

Concordantly, five points were identified along the buccal bony surface (B1 to B5). While point B1 coincided with osseous zenith, points B2, B3, B4 and B5 were identified as the points where segments originating in the LAT at a 90° from points C2, C3, C4 and C5, respectively, intersected the buccal bony surface. Points D1, D2, D3, D4 and D5 were identified as the points where segments originating in the LAT at a 90° from points C2, C3, C4 and C5, respectively, intersected the lingual bony surface.

Additionally, along these five segments, the width of the bony buccal wall, the width of the lingual wall and the alveolus width were measured.

Levels of vertical measurements: Three levels of vertical measurements were selected as follows. Vertical measurements were taken at the level of the osseous zenith (level B) at the center of the alveolus (level C) and at the lingual bony crest (level D). All vertical measurements were taken linearly through these levels, and always parallel to the LAT.

Levels of interproximal measurements: The image was 3-dimensionally aligned and reference points were established. The three planes – horizontal (blue), sagittal (red) and frontal (green) – were positioned. A reference point was identified, marked along the LAT and labeled with the letter E1. Measurements were taken from E1 to E2 located at the interproximal bony wall.

Six months after the tooth extractions, a new tomographic image was taken utilizing the radiographic stent. All previously determined reference points and segments were traced over the second tomographic image on the same plane using the “backtrack analysis method”. This method was described by Bontá et al. in previous paper¹² and enables reproducibility of measurements.

Additionally, new 6 post extraction measurements were taken in a similar way as the initial measurements and labeled under the prime symbol ('). Thus, a new set of points B1' to B5', C1' to C5', and D1' to D5' were established.

Horizontal measurements (variations in horizontal measurements): Dimensional changes that occurred along the buccal wall in a horizontal direction were measured at the previously mentioned five different horizontal levels, as changes in the segments B1-B1' through B5-B5'.

Vertical measurements (variations in the vertical measurements): Vertical resorption of the buccal wall was calculated by the linear vertical displacement of the original bony crest (point C1) as follows. Point C1' was determined where a line originating in point C1, running apically parallel to the LAT, intersected the buccal bony surface. Similarly, variations in the lingual crest height were determined with points D, D1 and DD.

Accordingly, bone fill of the alveolus was calculated based on the vertical measurement at the center of the alveolus. Thus, point CC' was calculated where segment originating in point C (placed at the AX reference segment) and running apically along the LAT, intersected the bony surface. Bone fill was linearly calculated as the difference between segments C-C1 and C-CC'.

Statistical Analysis

Descriptive statistics of variables included the arithmetic mean, median, standard deviation (SD), minimum (Min) and maximum (Max). In the text, group data are presented as mean ± SD. Statistical tests for paired samples were used to compare measurements between pre-operative and post-operative examinations: paired *t* test or Wilcoxon signed-rank test was selected according to whether normality assumption was satisfied or rejected, respectively. Normality assumption was tested

by Shapiro-Wilk test. A value of $P < 0.05$ was considered statistically significant.

Receiver operating characteristic (ROC)¹⁵ was analyzed with the aim of finding optimal cut-off points for vestibular plate and alveolus widths, which can help to predict high vertical and horizontal displacements of the osseous zenith. An ROC curve is constructed by plotting sensitivity versus 1-specificity. Sensitivity and specificity are the proportion of positive and negative cases detected, respectively. Vertical and horizontal displacements of the osseous zenith which exceeded the 85th percentile for the sample used in the present study (3.0 mm and 2.6 mm, respectively) were classified as “positive” cases. The rest of the values were considered as “negative” cases. Thus, in the ROC context, the widths of the vestibular plate and the alveolus are the diagnostic variables. The displacements of the osseous zenith in both vertical and horizontal directions, classified as positive (high) or negative according to the above criteria, are the outcome variables. The following criteria for the ROC analyses were set: both low values of vestibular plate width and high values of alveolus width would be related to high values of vertical and horizontal displacements of the osseous zenith. The area under the ROC curve (AUC) and its confidence interval of 95% (95% CI) are reported. AUC is a measure of the accuracy of the diagnostic variable for detecting positive and negative outcomes. The accuracy is minimal when AUC is 0.5 and maximal when AUC is 1.0. One way to interpret the intermediate values is as follows: between 0.5 and 0.7, accuracy is low; between 0.7 and 0.9, moderate; more than 0.9, high. The P value was calculated for the null hypothesis that AUC equals 0.5¹⁶. When this P value was less than 0.05 (significant result), optimal cut-off points were chosen using the Youden index¹⁷. Briefly, optimal cut-off points selected by this method maximize the sum of sensitivity and specificity. Sensitivity and specificity for optimal cut-offs points are reported.

Analyses were performed with statistical software. (Infostat version 2013¹⁸ - used for descriptive statistics, paired t test, Wilcoxon signed-rank test and Shapiro-Wilk test, R version 3.0.2¹⁹, pROC²⁰ and verification packages^{xxi} - used for ROC analyses).

RESULTS

Reference landmarks were determined at baseline and in final evaluations performed on each subject included in the study. The measurements were taken in a predictable manner, by recording dimensional changes that occur in post-extraction sockets within a 6-month period.

Table 1 summarizes the results at the pre-operative measurements of the width of the vestibular plate, palatal and alveolus width at levels 1 to 5, as well as the alveolar height.

ROC analyses were performed for each of the five levels where both vestibular plate and alveolus widths were measured. Only at level 3 were significant results obtained for the prediction of high displacement of the osseous zenith in both directions. Thus, in order to simplify the presentation of results, reporting of further analyses was restricted only to level 3.

At level 3, mean widths of the vestibular plate and palatal plate and alveolus width were 1.0 ± 0.5 mm (range: 0.4 to 2.1 mm), 3.7 ± 1.5 mm (range: 0.9 to 6.8 mm) and 4.2 ± 0.6 mm (range: 3.2 to 5.2 mm), respectively. Alveolus height was 8.5 ± 2.2 mm (range: 6.0 to 14.3 mm).

Vestibular plate horizontal remodeling is shown in Table 2. LAT-VP values decreased significantly between pre-operative and post-operative examinations for all five measured levels ($p < 0.001$).

At level 3, pre-operative and post-operative LAT-TV values were 3.0 ± 0.5 mm (range: 2.2 to 4.3 mm) and 1.5 ± 1.8 mm (range: -5.5 to 4.2 mm), respectively; and difference between them was -1.5 ± 1.6 mm (range: -7.8 to -0.1 mm).

Vertical and horizontal displacement of the osseous zenith was also significant ($p < 0.001$) (Fig. 2). Mean vertical resorption was 2.1 ± 1.7 mm, with a median of 1.9 mm and a range of 0.2 to 7.5 mm. Mean horizontal resorption was 1.8 ± 0.8 mm with a median of 1.7 mm; and a range of 0.6 to 4.4 mm.

ROC analyses were performed with the aim of finding a variable which can help predict vertical and horizontal displacement of the osseous zenith. Table 3 shows the results of ROC analysis. AUC values for the prediction of high vertical and horizontal displacement of the osseous zenith by the width of the vestibular plate (at level 3) were 0.82 (95% IC: 0.63 to 1.00) and 0.88 (95% IC: 0.73 to 1.00), respectively. In both cases, the AUC

Table 1. Width of plate (vestibular and palatal faces) and alveolus at the five measured levels and height of alveolus in the 20 examined cases on preoperative examinations.

	Mean	Median	SD	Min	Max
Vestibular plate width (mm)					
level 1	0.9	0.9	0.3	0.4	1.8
level 2	1.0	0.9	0.4	0.5	1.8
level 3	1.0	0.9	0.5	0.4	2.1
level 4	1.1	1.0	0.7	0.2	3.2
level 5	1.9	1.8	1.1	0.5	4.7
Palatal plate width (mm)					
level 1	1.3	1.4	1.0	0.3	4.1
level 2	2.5	3.0	1.4	0.6	5.3
level 3	3.7	3.6	1.5	0.9	6.8
level 4	4.9	5.3	1.9	1.5	8.2
level 5	6.8	6.9	2.2	3.3	10.3
Alveolus width (mm)					
level 1	5.8	5.7	1.0	4.1	7.7
level 2	4.9	4.8	0.7	3.5	5.8
level 3	4.2	4.2	0.6	3.2	5.2
level 4	3.4	3.4	0.6	2.1	4.8
level 5	1.3	1.3	0.4	0.6	2.0
Alveolus height (mm)	8.5	8.3	2.2	6.0	14.3

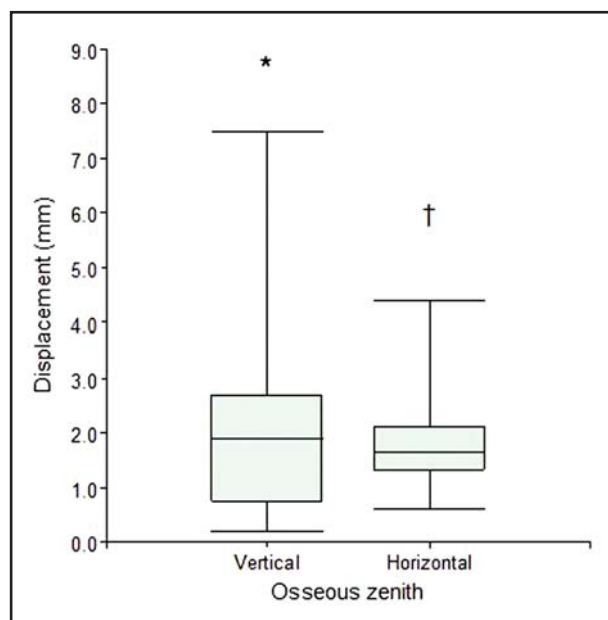


Fig. 2: Boxplot diagrams for vertical and horizontal displacements of the osseous zenith in the 20 examined cases, with the boxes representing 25th and 75th percentiles, including the median and whiskers showing minimum and maximum. *Significant vertical displacement ($p < 0.001$, Wilcoxon signed-rank test). †Significant horizontal displacement ($p < 0.001$, paired t test).

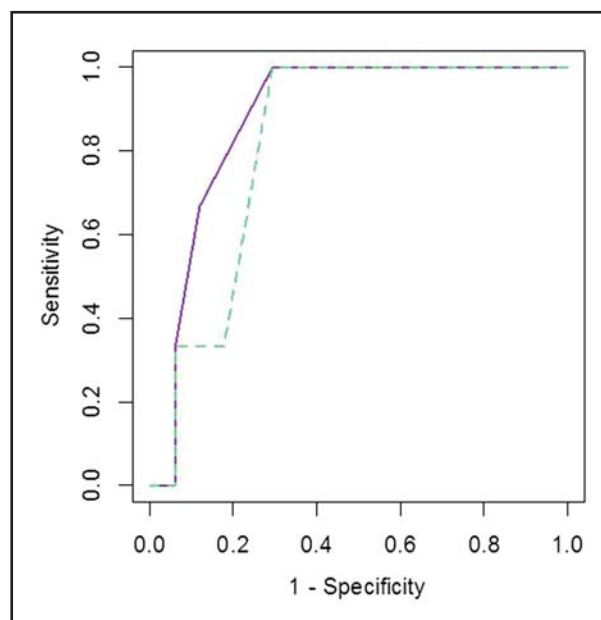


Fig. 3: ROC curves for the prediction of high displacement of the osseous zenith in both vertical (green dashed) and horizontal (purple solid) directions by vestibular plate width (measured at level 3) using the 20 examined cases.

differed significantly from 0.5 ($P < 0.05$). Thus, AUC values indicate significant and moderate accuracy for these two evaluations. The two ROC curves are shown in Fig. 3.

A vestibular plate width of 0.7 mm (at level 3) was the optimal cut-off point obtained for prediction of high vertical and horizontal resorption of the osseous zenith. Thus, if table width is less than or

Table 2. Changes in LAT-TV buccal plate (BP) at the five measured levels between preoperative and postoperative examinations.

Level	Level LAT-TV (mm)						
	n	Mean	Median	SD	Min	Max	P Value
1							
Preoperative (Pre)	20	3.5	3.4	0.6	2.6	5.3	
Postoperative (Post)	13	0.7	1.0	1.3	-1.4	3.0	<0.001 *
Difference (Post - Pre)	13	-2.9	-2.3	1.2	-5.1	-1.5	
2							
Preoperative (Pre)	20	3.3	3.2	0.6	2.6	5.0	
Postoperative (Post)	20	1.2	1.5	2.3	-7.5	4.7	<0.001 †
Difference (Post - Pre)	20	-2.2	-1.7	2.1	-10.5	-0.3	
3							
Preoperative (Pre)	20	3.0	2.9	0.5	2.2	4.3	
Postoperative (Post)	20	1.5	1.9	1.8	-5.5	4.2	<0.001 †
Difference (Post - Pre)	20	-1.5	-1.1	1.6	-7.8	-0.1	
4							
Preoperative (Pre)	20	2.8	2.6	0.8	2.2	4.9	
Postoperative (Post)	20	1.6	1.7	1.7	-4.7	3.9	<0.001 †
Difference (Post - Pre)	20	-1.2	-0.8	1.5	-7.1	-0.1	
5							
Preoperative (Pre)	20	2.7	2.3	1.1	1.3	6.0	
Postoperative (Post)	20	1.8	1.9	1.7	-4.3	4.1	<0.001 †
Difference (Post - Pre)	20	-0.9	-0.5	1.5	-6.5	0.6	

Table 3. Analysis of receiver operating characteristic (ROC) for the prediction of high displacements of the osseous zenith by vestibular plate and alveolus widths (measured at level 3) using the 20 examined cases.

Diagnostic variable	Displacement of the osseous zenith in vertical direction					Displacement of the osseous zenith in horizontal direction				
	AUC (95% IC)	P Value	Optimal cut-off point	Sensitivity	Specificity	AUC (95% IC)	P Value	Optimal cut-off point	Sensitivity	Specificity
Vestibular plate width (level 3)	0.82 (0.63 to 1.00)	0.044 *	0.7 mm †	1.00	0.71	0.88 (0.73 to 1.00)	0.021 *	0.7 mm ‡	1.00	0.71
Alveolus width (level 3)	0.58 (0.26 to 0.90)	0.355	NC	NC	NC	0.75 (0.34 to 1.00)	0.101	NC	NC	NC

* $P < 0.05$, AUC significantly different from 0.5.

† Vestibular plates widths ≤ 0.7 mm predict osseous zenith displacement in vertical direction > 3.0 mm, with sensitivity 1.00 and specificity 0.71.

‡ Vestibular plates widths ≤ 0.7 mm predict osseous zenith displacement in horizontal direction > 2.6 mm, with sensitivity 1.00 and specificity 0.71.

equal to 0.7 mm, a vertical resorption greater than 3.0 mm and a horizontal resorption greater than 2.6 mm are predicted; in both cases with sensitivity 1.00 and specificity 0.71.

ROC analysis for the prediction of high values of vertical and horizontal displacement of the osseous zenith by the alveolus width returned an AUC of 0.58 (95% IC: 0.26 to 0.90) and 0.75 (95% IC: 0.34 to 1.00), respectively. Since in both cases the AUC did not differ significantly from 0.5, the level of prediction was not considered useful and optimal cut-off points were not calculated.

DISCUSSION

The resorption process responsible for dimensional changes following tooth extraction has been studied in different animal models^{21,23} and in human subjects²⁶⁻²⁷. Different methods have been published in the literature for identifying and measuring dimensional changes that occur in post-extraction sockets, with or without the application of biomaterials. Dimensional and contour changes in post-extraction sockets have been described by serial study cast measurements^{28,29}, lateral cephalograms³⁰, radiographic analyses^{31,32} and direct measurements of the ridge following surgical re-entry procedures³³.

Schropp et. al.⁷ used study models and standardized intraoral and subtraction radiography to evaluate 46 patients over a 12-month period. They reported loss of volume in the horizontal dimension in the range of 5 to 7mm within the first 12 months. This corresponded to approximately 50% of the original width of the alveolar bone. Bidimensional intraoral radiographs allowed only mesiodistal measurements and there were limitations in the application of subtraction radiography techniques. Fickl et al. evaluated dimensional changes in post-extraction sites in five beagle dogs by scanning models obtained before treatment, and at 2 and 4 months post-extraction. They concluded that the exposure of the buccal bone had a detrimental effect on the resorption process occurring after tooth extraction. In the presented animal model, 0.7mm additional volumetric shrinkage could be observed. The authors described limitations when trying to observe changes in the different alveolar ridge walls³⁴. Nevins et al. presented a method for measuring alveolar ridges by performing CT scans in 36 patients immediately after extraction, at 30

days and at 90 days post-extraction³⁵. Nineteen extraction sockets received bovine demineralized bone graft, and seventeen sockets received a non-osteogenic material. The majority of the sockets treated with the bone graft showed a loss smaller than 20% of the buccal plate. In contrast, 71% of the control sockets showed a loss of more than 20% of the buccal plate. The nasal floor was used as the anatomical reference but there was no precise reference to enable the location of the same point horizontally in subsequent scans. In general, the articles described agree that bone resorption inevitably occurs after tooth extraction and that bone grafting of the socket diminishes the effect, but is incapable of preventing it completely. The methods for measuring described in these articles present varying degrees of reproducibility and accuracy according to the technique applied.

The method used in this study previously proved to be simple, reproducible and effective, enabling the identification of the same point in space in different CT scans with a high degree of accuracy¹². This measurement system enabled measurement of morphological changes in alveolar ridges after extraction and accurate determination of the displacement of the osseous zenith in the apical and lingual direction.

ROC curves were used to analyze our results statistically. ROC analysis was developed in the mid-twentieth century to optimize signal detection by radars³⁶. Biomedical applications of this method were soon found, and today it is used as a predictive tool for decision-making in different fields of health sciences³⁷. In this context, ROC curves are currently used in dentistry, including periodontology³⁸. The importance of this statistical technique is that it minimizes the probability of error when a clinical decision between two opposite options must be made³⁹. In the present study, ROC analysis provided a simple way to help predict, with significant and acceptable accuracy, the displacement of the osseous zenith based on the width of the vestibular plate. More specifically, our results suggest that low values (< 0.7mm) of the width of the vestibular plate at level 3 (mid-alveolar height) would predict high displacement of the osseous zenith in both horizontal and vertical directions.

Hard tissue modeling and remodeling following tooth extraction were studied in the dog model by Cardaropoli et al⁴⁰.; and Araujo and Lindhe⁴¹. They

demonstrated that the socket was first occupied by a coagulum, which was subsequently replaced by granulation tissue, provisional connective tissue and woven bone. This immature hard tissue was later replaced with lamellar bone and marrow. During healing, the height of the buccal bone wall was substantially reduced. In addition, about 30% of the marginal portion of the alveolar process of the extraction site was modeled and lost.

The patterns of bone remodeling were variable regarding the extent of vertical and horizontal resorption of the facial wall and alveolar fill.

The utilization of an accurate method to evaluate alveolar remodeling enables identification of dimensional changes that occur in the alveolar ridge after extraction. With this methodology¹², it was possible to observe, and precisely measure in human subjects –throughout time and in a non-invasive manner– changes and bone morphology in alveolar ridges in all three spatial dimensions

The present study confirms significant resorption of the facial wall showing more resorption towards the coronal bony crest. Lingual bony wall showed little resorption.

The portion of bone providing support to the gingival zenith, termed in this study “osseous zenith”, showed significant displacement towards

the lingual and apical direction (median vertical: 1.9 mm - median horizontal: 1.7 mm).

With regard to the limitations of this study, we can say that a larger number of cases should be evaluated in order to confirm these results.

In conclusion, physiological changes that occur in the alveolus after dental extraction make the pursuit of the highest esthetic goals difficult and unpredictable. Final bone morphology determines the optimal position in which an implant should be placed as a tooth replacement, and thus greatly affects the ultimate esthetic results. Understanding and predicting the amount and pattern of bone remodeling enables the clinician to elaborate adequate treatment alternatives to prevent, revert or compensate for bone resorption. Atraumatic extractions and the displaced flap for alveolar primary closure produced greater bone resorption in the vestibular crest than in the palatal-lingual crest in both vertical and horizontal direction

The present study suggests that if the width of the facial crest at the apical-coronal mid-point is less than 0.7 mm, a high degree of displacement of the osseous zenith (> 3 mm) should be expected. The width of the alveolar crest at its mid-level, rather than the crestal width, may be correlated with the displacement of the osseous zenith.

ACKNOWLEDGMENTS

This work was financially supported by a grant from the Argentinean Society of Periodontology, Buenos Aires, Argentina.

CORRESPONDENCE

Dr. Mariana Rojas

Department of Periodontics, University of Buenos Aires,.

Marcelo T. de Alvear 2142, 17° A

Buenos Aires, Argentina

rojasmarianaandrea@gmail.com

REFERENCES

1. Atwood DA. Some clinical factors related to the rate of resorption of residual ridges. *J Prosthet Dent* 2001; 86: 119-125.
2. Johnson K. A study of the dimensional changes occurring in the maxilla after tooth extraction. Part I. Normal healing. *Aust Dent Journal* 1969; 8: 241-244.
3. Boyne PJ. Osseous repair of the postextraction alveolus in man. *Oral Surg, Oral Med and Oral Pathol* 1966; 21: 805-813.
4. Barone A, Aldini N, Fini M, Giardino R., Calvo-Guirado JL, Covani U. Xenograft versus extraction alone for ridge preservation after tooth removal: a clinical and histomorphometric study. *J of Periodontol* 2008; 79: 1370-1377.
5. Pietrokovski J, Massler M. Alveolar ridge resorption following tooth extraction. *J Prosthet Dent* 1967; 17: 21-27.
6. Amler MH. The time sequence of tissue regeneration in human extraction wounds. *Oral Surg, Oral Med and Oral Pathol* 1969; 27: 309-318.
7. Schropp L, Wenzel A, Kostopoulos L, Karring T. Bone Healing and Soft Tissue Contour Changes Following Single-Tooth Extraction: A Clinical and Radiographic 12-Month Prospective Study. *Int J Periodontics Restorative Dent* 2003; 23: 313-323.
8. Tan WL, Wong TL, Wong MC, Lang NP. A systematic review of post-extraction alveolar hard and soft tissue dimensional changes in humans. *Clin Oral Implants Res* 2012; 23: 1-21.
9. Van Der Weijden F, Dell'Acqua F, Slot DE. Alveolar dimensional changes of post-extraction sockets in humans: A systematic review. *J Clin Periodontol* 2009 ;36: 1048-1058.
10. Chen ST, Wilson TG Jr, Hämmerle CH. Immediate or early placement of implants following tooth extraction: review of biologic basis, clinical procedures, and outcomes. *Int J Oral Maxillofac Implants* 2004; 19: 12-25.

11. Artzi Z, Tal H, Davan D. Porous bovine bone mineral in healing of human extraction sockets. Part 1: Histomorphometric evaluation at 9 months. *J Periodontol* 2000; 21: 1015-1023.
12. Bontá H, Galli F, Caride F, Carranza N. A method for measuring post-extraction alveolar dimensional changes with volumetric computed tomography. *Acta Odontol Latinoam* 2012; 25: 186-192.
13. Chu SJ, Tan JH, Stappert CF, Tarnow DP. Gingival zenith positions and levels of the maxillary anterior dentition. *J Esthet Restor Dent*. 2009; 21:113-20.
14. Fickl S, Zuhr O, Wachtel H, Stappert CF, Stein JM, Hurzeler MB. Dimensional changes of the alveolar ridge contour after different socket preservation techniques. *J Clin Periodontol* 2008; 35: 906-913.
15. Bonta H, Carranza N, Caride F, Rojas M, Galli F. Lateral sliding flap to assist with anterior maxillary dental implant esthetics. *J of Impl and Advanced Clin Dent*.2015;7(9):11-21. http://jiacd.com/wp-content/files_mf/1448304877JIACDNov15.pdf
16. Bewick V, Cheek L, Ball J. Statistics review 13: receiver operating characteristic curves. *Crit Care* 2004; 8:508-512.
17. NCAR. Research Application Program 2012.verification: Forecast verification utilities. R package version 1.35. URL: <http://CRAN.R-project.org/package=verification..>
18. Youden WJ. Index for rating diagnostic tests. *Cancer* 1950; 3: 32-35.
19. Di Rienzo JA, Casanoves F, Balzarini MG, Gonzalez L, Tablada M, Robledo CW. Info Statversion 2013. Grupo InfoStat, FCA, Universidad Nacional de Córdoba, Argentina. URL: <http://www.infostat.com.ar>.
20. R Core Team. R: A language and environment for statistical computing. R Foundation for Statistical Computing, Vienna, Austria. 2013. URL:: <http://www.R-project.org/>.
21. Robin X, Turck N, Hainard A, Tiberti N, Lisacek F, Sanchez JC, Müller M. pROC: an open-source package for R and S+ to analyze and compare ROC curves. *BMC Bioinformatics* 2011;12,77. DOI: 10.1186/1471-2105-12-77.
22. Akobeng AK. Understanding diagnostic tests 3: Receiver operating characteristic curves. *Acta Pediatr* 2007; 96: 644-647.
23. Kuboki Y, Hashimoto F, Ishibashi K. Time-dependent changes of collagen crosslinks in the socket after tooth extraction in rabbits. *J Dent Res* 1988; 67: 944-948.
24. Araújo MG, Linder E, Wennström J, Lindhe J. The influence of Bio-Oss Collage non healing of an extraction socket: An experimental study in the dog. *Int J Periodontics Restorative Dent*. 2008; 28: 123-135.
25. Carmagnola D, Adriaens P, Berglundh T. Healing of human extraction sockets filled with Bio-Oss. *Clin Oral Implants Res* 2003; 14: 137-143.
26. Lekovic V, Kenney EB, Weinlaender M, Han T, Klokkevold P, Nedic M, Orsini M. A bone regenerative approach to alveolar ridge maintenance following tooth extraction. Report of 10 cases. *J Periodontol* 1997;68: 563-570.
27. Lekovic V, Camargo PM, Klokkevold PR, Weinlaender M, Kenney EB Dimitrijevic B, Neduc M. Preservation of alveolar bone in extraction sockets using bioabsorbable membranes. *J Periodontol* 1998; 69:1044-1049.
28. Lam RV. Contour changes of the alveolar processes following extractions. *J Prosthet Dent*. 1960; 10: 25-32.
29. Watt DM, Likeman PR. Morphological changes in the denture bearing area following the extraction of maxillary teeth. *Br Dent J* 1974; 136: 225-235.
30. Atwood DA, Coy WA. Clinical, cephalometric, and densitometric study of reduction of residual ridges. *J Prosthet Dent* 1971; 26, 280-295.
31. Barone A, Aldini NN, Fini M, Giardino R, Calvo-Guirado JL, Covani, U. Xenograft versus extraction alone for ridge preservation after tooth removal: a clinical and histomorphometric study. *J Periodontol* 2008; 79:1370-1377.
32. Atwood DA. A cephalometric study of the clinical rest position of the mandible. Part II. The variability in the rate of bone loss following the removal of occlusal contacts. *J Prosthet Dent* 1957; 7: 544-552.
33. Carlsson GE, Persson G. Morphologic changes of the mandible after extraction and wearing of dentures.A longitudinal, clinical, and x-ray cephalometric study covering 5 years. *Odontol Revy* 1967;18: 27-54.
34. Fickl S, Zuhr O, Wachtel H, Stappert CF, Stein JM, Hurzeler MB. Dimensional changes of the alveolar ridge contour after different socket preservation techniques.*J Clin Periodontol* 2008; 35: 906-913.
35. Nevins M, Camelo M, De Paoli S, Friedland B, Schenk R K, Parma-Benfenati S, Simion M, Tinti C et al. A study of the fate of the buccal wall of extraction sockets of teeth with prominent roots.*Int J Periodontics Restorative Dent* 2006; 26: 19-29.
36. Zweig MH, Campbell G. Receiver-operating characteristic (ROC) plots: a fundamental evaluation tool in clinical medicine. *Clin Chem* 1993;39: 561-577.
37. Fawcett T. An introduction to ROC analysis. *Pattern Recognit Lett* 2006; :861-874.
38. Nummikoski PV, Steffensen B, Hamilton K, Dove SB. Clinical validation of a new subtraction radiography technique for periodontal bone loss detection. *J Periodontol* 2000;71: 598-605.
39. Swets JA, Dawes RM, Monahan J. Better decisions through science. *Sci Am* 2000;283: 82-87.
40. Cardaropoli G, Araujo M, Lindhe J. Dynamics of bone tissue formation in tooth extraction sites. An experimental study in dogs. *J Clin Periodontol* 2003; 30, 809-818.
41. Araújo MG, Sukekava F, Wennström JL, Lindhe J. Ridge alterations following implant placement in fresh extraction sockets: An experimental study in the dog. *J Clin Periodontol* 2005; 32: 645-652.