

# PULSED ELECTROMAGNETIC FIELDS AS ADJUVANT THERAPY IN BONE HEALING AND PERI-IMPLANT BONE FORMATION: AN EXPERIMENTAL STUDY IN RATS

Daniel R. Grana<sup>1</sup>, Hernán J. Aldana Marcos<sup>2</sup>, Gabriel A. Kokubu<sup>1</sup>

<sup>1</sup> Cátedra de Patología I, Escuela de Odontología Asociación Odontológica Argentina, Universidad del Salvador, Buenos Aires, Argentina.

<sup>2</sup> Laboratorio de Histología, Facultad de Medicina, Universidad de Morón, Argentina.

## ABSTRACT

The objective of this study was to determine whether short exposure to pulsed electromagnetic fields (PEMF) accelerates bone repair and peri-implant bone formation in a rat tibial model at different times.

Sixty Wistar rats were employed. Sterile custom fabricated commercially pure cylinder threaded titanium implants were placed in the right tibial crest, and an osteotomy was performed in the left tibial crest of each animal.

Thirty rats were treated with PEMF (72 mT, 50Hz), twice a day in sessions of 30 minutes each, and 30 rats of the control group were sham-treated.

Rats were sacrificed at 5, 10 and 20 days postsurgery (n=10 per group). Tibias were fixed in formaldehyde and decalcified, embedded in paraffin, and stained with hematoxylin-eosin (half

samples of left tibias), or they were included in methyl-methacrylate, grinded and polished (right tibias and half samples of left tibias). Bone healing was evaluated by image analysis in terms of ossification area, and perimeter and diameter of the lesion. Peri-implant ossification was assessed in terms of ossification percentage.

At day 10 the area of ossification index was higher in the PEMF group than in the control group (p=0.012). At day 20 the osteotomies of the PEMF group were almost completely remodeled. The ossification percentage was higher in the PEMF group (p=0.018).

In conclusion, short daily electromagnetic stimulation appears to be a promising treatment for acceleration of both bone-healing and peri-implant bone formation.

**Key words:** pulsed electromagnetic fields, bone, implant, healing.

## CAMPOS ELECTROMAGNÉTICOS PULSANTES COMO TERAPIA ADYUVANTE EN LA REPARACIÓN Y EN LA FORMACIÓN ÓSEA PERI-IMPLANTARIA: UN ESTUDIO EXPERIMENTAL EN RATAS

### RESUMEN

El objetivo del presente trabajo fue evaluar a diferentes tiempos en un modelo experimental en tibias de rata, el efecto de la exposición breve a campos electromagnéticos pulsantes (PEMF, del inglés Pulsed ElectroMagnetic Fields) sobre la reparación y formación ósea peri-implantaria.

Se utilizaron 60 ratas Wistar. En la cresta tibial derecha de cada animal se colocó un implante roscado de titanio comercialmente puro y en la cresta tibial izquierda se efectuó una osteotomía.

La mitad de los animales fueron tratados con PEMF (72 mT, 50Hz) dos veces por día (30 minutos por sesión), y la otra mitad constituyó el grupo control.

Las ratas se sacrificaron a los 5, 10 y 20 días postcirugía (n=10 por grupo). La mitad de las tibias derechas se descalcificaron, incluyeron en parafina y tiñeron con hematoxilina-eosina, mientras que al resto se las incluyó en metil-metacrilato y se

realizaron cortes por desgaste. Se evaluó el área de osificación, el perímetro y el diámetro de las osteotomías mediante un analizador de imágenes. Para evaluar la osificación peri-implante se obtuvo el porcentaje de osificación.

Al día 10 el índice del área de osificación fue significativamente mayor en el grupo PEMF que en el control (190,6±13,6 vs. 147,9±6,3; p=0,012). Al día 20, las osteotomías del grupo PEMF estaban, en su mayor parte remodeladas. El porcentaje de osificación fue mayor en el grupo PEMF respecto al control (51,9±10,4% vs. 36±12,1%; p=0,018).

La breve estimulación electromagnética pulsante diaria sería un tratamiento promisorio para facilitar la reparación ósea y peri-implantaria.

**Palabras clave:** campos electromagnéticos pulsantes, implantes, cicatrización.

### INTRODUCTION

Implantology is now a well-established discipline in medicine and dentistry. The results of such treatment often depend upon the condition of the receiving site.

The superstructure is seated on the implant after the osseointegration occurs. In order to reduce the time between implantation and placement of the superstructure, and also to accelerate the bone healing process,

several procedures have been developed and are being studied<sup>1</sup>. Since numerous intrinsic and extrinsic factors affect these complex biological processes that comprise several overlapping steps, the procedures are difficult to evaluate clinically<sup>2</sup>. This emphasizes the importance of the animal models, which reduce the biological variability of the different parameters involved in these processes and are very useful in the evaluation of the effect of different treatments on peri-implant bone formation and bone healing.

Enhancement of bone ingrowth is needed to improve the rate of success in terms of reliability and longevity of implants. Adjuvant therapies could improve osseointegration, particularly when endogenous osteogenic potential is expected to be low<sup>3</sup>.

It is now well recognized that exogenously applied low-frequency, low-energy, pulsed electromagnetic fields (PEMF) accelerate bone repair<sup>4-6</sup>.

PEMF has been reported to improve cell-biomaterial interactions and antibiotic efficacy in implant infections<sup>7,8</sup>.

Previous studies have demonstrated that PEMF can stimulate bone formation and can promote healing of delayed union and nonunion fractures<sup>9</sup>. In animal models, several studies have reported PEMF stimulation of osteotomy repair<sup>4,9</sup>. However, several PEMF signals were employed, as well as different exposure times which ranged from 30 minutes per day to 24 hs.

In studies with rats, we found statistically significant differences in the reduction of wounds at day 21 between the group treated with PEMF (AC, 50 Hz, 20 mT) for 30 minutes twice a day and the control and nitrofurazone-treated groups<sup>10,11</sup>. No alterations were found in the behavior or the biochemical parameters studied, including hepatic microsomal enzymes<sup>12</sup>.

In our country, physical therapists employ the parameters used in this and in our previous studies in daily practice. PEMF are usually indicated for patients with muscle-skeletal pain, soft tissue inflammation and wound healing.

The purpose of the present study was to determine whether short exposure (two sessions of 30 minutes each) to PEMF accelerates bone repair and peri-implant bone healing in a rat tibial model at 5-10 and 20 days postsurgery.

## MATERIAL AND METHODS

Sixty Wistar rats of both sexes, body weight 150-250 g, from the animal facilities of the School of

Medicine – USAL were employed throughout. International regulations for the care and use of laboratory animals were strictly observed<sup>13</sup>. Food and water were provided throughout the experiment *ad libitum*. The room was maintained at 23°C, with 12 hour light-dark cycles.

Sterile custom fabricated commercially pure cylinder threaded titanium implants, 2 mm in length and 2 mm in diameter (ImplantVel S.A., Buenos Aires, Argentina), were employed. Implants were made of titanium grade 2 (99.7% purity) and all the fabrication and packaging processes were similar to the ones used for clinical implants.

All operative procedures were performed under intraperitoneal anesthesia (ketamine clorhidrate; 25 mg/kg + acepromazine; 0.5 mg/kg) and with aseptic surgical techniques. The rat's legs were clipped of all hair, prepared with povidone-iodine solution and draped for surgery. A longitudinal skin incision was made in order to expose the tibial crest in both legs. After incising and raising the periosteum, a cortical window was excised with a hollow drill (1.5 mm in diameter) with sterile saline irrigation. In the left leg the wound was closed in layers. Meanwhile, in the right leg, the implant was screwed into the bone with a special wrench and the wounds were closed in layers with silk. The implant design and the procedures replicated as closely as possible those used for human implant placement, but neither antibiotics nor anti-inflammatory or analgesic therapy were employed. The rats were carefully followed in the post surgical period for complications including pain, discomfort, and infection. Animal health was also monitored in terms of potential changes in body weight.

Radiographies were performed with Siemens odontologic equipment (14 mA and 60 Kv).

Rats were randomly assigned to one of two groups:

a) PEMF (n=30), treated with PEMF (72 mT and 50 Hz) generated with a Magnetherp equipment (Meditea Electromédica, Buenos Aires, Argentina), twice a day, in sessions of 30 minutes each. The waves were sinusoidal in modulated trains of impulses of 60 msec with intervals of 450 msec as dead time. The rats were placed in a coil connected to the generator and were not restrained.

b) Control (n=30) without treatment (the animals were submitted to sham sessions in an unplugged coil).

The groups were then divided into 3 subgroups of 10 animals each for sacrifice at 5, 10 and 20 days post surgery.

After sacrifice, all tibias were harvested, cleaned of soft tissue, and fixed in 10% phosphate-buffered formaldehyde for at least 12 hours. They were radiographed and processed for evaluation, i.e. a) after decalcification in 5% nitric acid, the samples were embedded in paraffin, sectioned at 5  $\mu\text{m}$ , stained with hematoxylin-eosin and observed under light microscopy (half samples of left tibias), or b) samples were included in methyl methacrylate, processed by grinding and polishing to 80  $\mu\text{m}$  thickness (right tibia and half samples of left tibias). Sections were stained with a saturated solution of aniline blue and observed under polarized and transmitted light.

Both samples were sectioned perpendicular to the major axis of the implant.

Images (24 bit bmp, 520 x 390) were captured with a video camera SONY SSC-DC50 fitted to a Nikon Eclipse E400 light microscope. Histometric analysis was completed utilizing computer image analysis software (Scion Image for Windows, Scion Corp.). To evaluate bone healing (left tibia) 3 manual measurements were made for each case: ossification area, and perimeter and diameter of the lesion. In order to normalize the comparisons the indexes area/diameter and perimeter/diameter were calculated and compared with two tailed Student's *t* test. To evaluate peri-implant ossification with Scion Image, each triangular area of each thread placed intramedullarly was measured. The portion occupied by bone within that triangular area was also quantified (Fig. 1). Data (ossification percentage) was compared with Student's *t* test.

To eliminate inter-individual observer variation, the same investigator performed all histomorphometric analyses. To eliminate potential bias in the evaluation procedures all analyses were performed blindly.

## RESULTS

No significant differences were found between the body weights of both groups throughout the experimental period. None of the animals were lost to follow-up because of stress or other complications. Only one animal was sacrificed due to infection.

As no differences were observed within each group between males and females, data was not stratified by gender to increase the statistical power.

### Day 5:

No radiological differences were observed between groups.

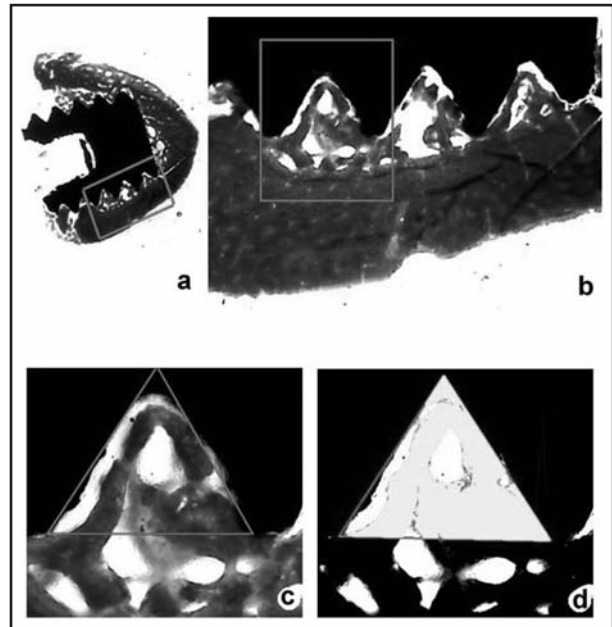


Fig. 1. Undecalcified transversal section, stained with aniline blue, of rat tibia with a threaded titanium implant placed in the tibial crest (a 5X and b 100X).

With the image analysis software Scion Image, each triangular area of each thread placed intramedullarly was measured. Threads in contact with cortical bone were disregarded (c 250X). Finally, the portion occupied by bone within that triangular area was also quantified (d 250X) and the ossification percentage was calculated.

### Osteotomy:

Potential differences between both groups were not measurable since almost no calcified bone tissue was observed. However, structural and maturation changes in the tissue were observed in the PEMF group. These changes were more evident in the polished sections observed under polarized light, where it was possible to see that in PEMF group the collagen fibers of osteoid tissue were perpendicular to the surface of the wound. Conversely, the control group exhibited a disorderly arrangement of collagen fibers.

Microscopically, substance losses were equivalent in both groups, and there were no changes in the marrow channel, endostium, and wound's borders or in the adjacent periosteum.

In the decalcified sections of the control group remains of the clot, neofomed vessels, inflammatory infiltrate with persistence of PMNs and absence of bony trabeculae of reticular type could be observed.

Conversely, no clot remains were observed in the PEMF group. Abundant neofomed vessels and

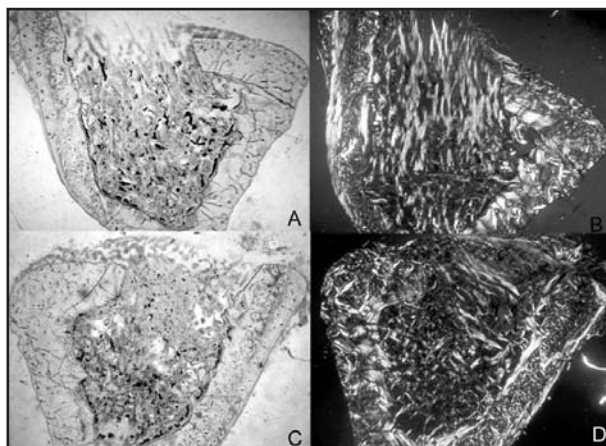


Fig. 2. Undecalcified transversal sections of rat tibia without staining. 36X

A: Control group at day 10 under light microscopy.

B: Same as A observed under polarized light denoting disorganization of collagen fibers and woven bone in comparison to D.

C: PEMF group at day 10 under light microscopy.

D: Same as C observed under polarized light. Note that fibers and trabeculae show a more organized pattern.

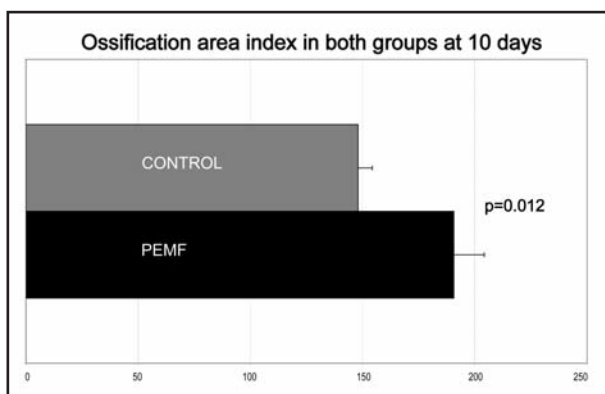


Fig. 3. Ossification area index in both groups at 10 days.

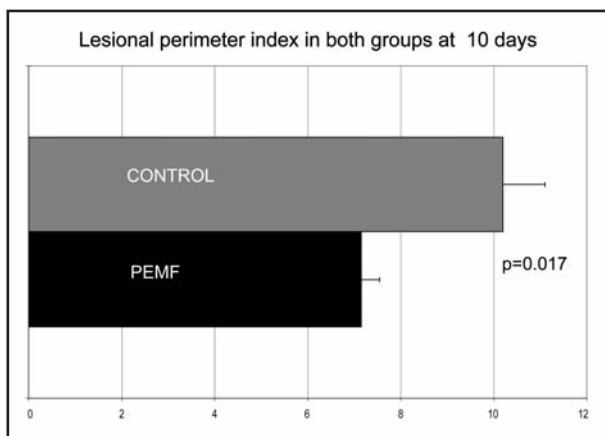


Fig. 4. Lesional perimeter index in both groups at 10 days.

mononuclear inflammatory infiltrate were observed. Chondroid tissue localized in the subperiosteal surface was observed.

#### Implants:

No differences were seen between groups due to the absence of peri-implant bone tissue at the marrow level.

#### Day 10:

No differences were detected between the X-rays of both groups.

#### Osteotomy:

In the polished sections, an other material was observed filling the gaps in both groups. Polarization microscopy showed it was a low refringence substance, suggesting collagen and osteoid, and revealed an apparent difference in the order of the fibers and the quantity and orientation of the neo-trabeculae (Fig. 2).

An increase in periosteal osteogenic activity was observed on the borders in the PEMF group.

The area of ossification index was  $190.62 \pm 13.59$  for the PEMF group vs.  $147.94 \pm 6.35$  for the control group ( $p=0.012$ ) (Fig. 3).

The perimeter index was  $7.15 \pm 0.4$  vs.  $10.2 \pm 0.9$  ( $p=0.017$ ) respectively (Fig. 4).

#### Implant:

Intense osteogenesis was observed at the cervical level, originated from periosteum and endosteum. Induction of intramedullary osteogenesis was also observed.

Although the percentage of ossification of the studied areas was  $13.71 \pm 6.22\%$  in the control group, and  $16.23 \pm 10.23\%$  in the PEMF group, the differences were not significant.

We assessed peri-implant intramedullary bone growth by grinding and polishing samples to 80 mm thickness. Bone sections were too thick for bone characterization. However, section evaluation by polarized light revealed that the distribution of PEMF collagen fibers was more orderly than in the control group.

#### Day 20:

#### Osteotomy:

Total closing of the wounds with thin reticular trabeculae was observed in both groups. Endosteal osteogenesis did not show differences between both groups. At day 10 differences were remarkable among the groups, while at day 20 changes were difficult to quantify as the wounds were completely closed. However, the changes detected pointed to

the osseous remodeling phenomenon, which was much more advanced in the PEMF group. While no bony trabeculae were found in the marrow channel of the PEMF group, they were identified in the controls. The cortical bone of the PEMF group was less cellular, evidencing a difference in maturation degree between both groups.

Radiologically, the wounds of the PEMF group were more radiopaque, suggesting increased osteogenesis.

#### Implant:

Similarly to day 10, intense osteogenesis originating from periosteum and endosteum was observed at the cervical level of the implant. Differences in thickness in peri-implant bone were notorious between 10 and 20 days.

The ossification percentage was  $35.96 \pm 12.08\%$  (mean  $\pm$  standard deviation) in the control group and  $51.86 \pm 10.43\%$  in the PEMF group ( $p=0.018$ ) (Fig. 5).

Although the assessment of osseointegration was out of the scope of this study, more contact between metal and bone was subjectively observed in the PEMF group.

## DISCUSSION

Today, more and more researchers are coming to accept the notion that subtle interactions exist between magnetic and biological systems<sup>14</sup>.

The healing of bone in this study model has similarities and differences with the oral cavity. The formation of long bone results from an endochondral sequence, whereas formation of the mandible and maxilla is intramembranous. However, the sequence in which bone is formed in the osseointegration of dental implants and orthopedic fixation screws is one of repair. As a result, the information obtained in this study may have implications for dental implants<sup>15</sup>. Similar success rates were obtained in the human implant situation and the rat tibia model, establishing the reliability of this method for placement of implants<sup>16</sup>. The advantage of this model is the possibility to investigate bone formation in the gap and bone ingrowth to the implant under very controlled circumstances. The bone healing is not affected by weight loading and takes place in a purely osseous environment. A disadvantage is the difference with the clinical situation, where such controlled situations are rare.

The effects of PEMF on bone formation following pseudoarthrosis, delayed and fresh fractures, and

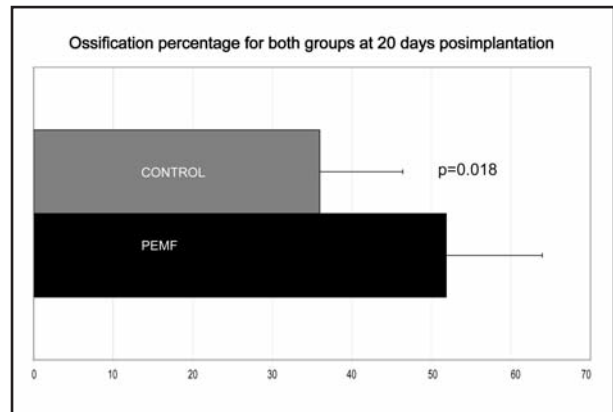


Fig. 5. Ossification percentage for both groups at 20 days post-implantation.

bone graft have been reported<sup>1</sup>, but there are few data on PEMF stimulation following the placement of titanium implants and bone stimulation employing the parameters of this study. Indeed, factors such as the duration of stimulation and intensity of electromagnetic powers are still controversial. Buzzá et al.<sup>17</sup> did not observe any effect on bone-healing around commercially pure dental implants in rabbits treated for 21 and 42 days (frequency of 20 Mc; 30 minutes). Fini et al.<sup>18</sup> reported improvement of bone-HA contact ratio in PEMF-treated rabbits at 3 and 6 weeks (1.6 mT; 75 Hz; 6 hs/day). Ijiri et al.<sup>19</sup> noted improvement of new bone area around titanium in PEMF-treated rabbits at 2 weeks (0.2 mT; 10 Hz; 5 and 10 hs/day). Matsumoto et al.<sup>1</sup> observed improvement of bone contact ratio (with titanium) and bone area ratio in PEMF-treated rabbits at 2 weeks (0.2 mT; 100 Hz; 4 hs/day). Ottani et al.<sup>14</sup> found more advanced bone formation around hydroxyapatite in PEMF-treated rabbits at 4 weeks (8 mT; 50 Hz; 30 min/day). Shimizu et al.<sup>20</sup> reported more bone formation in PEMF-treated rabbits at 3 weeks (0.18 mT; 1.5 Hz; 8 hs/day). With the exception of Buzzá et al.<sup>17</sup>, who did not clearly specify the parameters employed in their study (e.g. intensity), other authors found beneficial results of PEMF in bone healing. The duration of stimulation may be an important factor; the successful reports ranged from 4 to 10 hs of treatment per day, a time-consuming practice which made it clinically impractical<sup>1,18-20</sup>. However, Ottani et al.<sup>14</sup> successfully employed sessions of 30 minutes per day during 4 weeks. We obtained good results with treatment sessions of 1 h/day divided into two sessions of 30 minutes

each, a reasonable exposure time bearing in mind clinical usefulness. We also employed a high intensity, 72 mT, when compared with other studies on implanted materials, but this is still a low intensity compared to the values currently used in Physical Therapy. Our observations suggest that bone remodeling started earlier in PEMF-treated animals.

However, one possible limitation of our study is that it does not reflect the oral environment and that it uses small animals. Further studies employing larger animals are needed to confirm our results.

We must point out that we decided not to perform a critical defect in tibia, because this would have added some complexity to the experiment. Usually, critical defects do not have a circular shape (as employed herein). The rectangular shape with a width < 2 mm is the most common, avoiding the possibility of fractures.

#### ACKNOWLEDGMENT

This study was performed with a research grant from the Asociación Odontológica Argentina.

#### REFERENCES

1. Matsumoto H, Ochi M, Abiko Y, Hirose Y, Kaku T, Sakaguchi K. Pulsed electromagnetic fields promote bone formation around dental implants inserted into the femur of rabbits. *Clin Oral Impl Res* 2000; 11:354-360.
2. Erdogan O, Esen E, Ustun Y, Kurkcu M, Akova T, Gonlusen G, Uysal H, Cevlik F. Effects of low-intensity pulsed ultrasound on healing of mandibular fractures: An experimental study in rabbits. *J Oral Maxillofac Surg* 2006; 64:180-188.
3. Fini M, Giavaresi G, Giardino R, Cavani F, Cadossi R. Histomorphometric and mechanical analysis of the hydroxyapatite-bone interface after electromagnetic stimulation. *J Bone Joint Surg (Br)* 2006; 87-B:123-128.
4. Bassett CAL, Powluk RJ, Pilla AA. Augmentation of bone repair by inductively coupled electromagnetic fields. *Science* 1974; 184:575-577.
5. Ryaby JT. Clinical effects of electromagnetic and electric fields on fracture healing. *Clin Orthop Rel Res* 1998; 355(suppl):205-215.
6. Aaron RK, Ciombor DM, Simon BJ. Treatment of nonunions with electric and electromagnetic fields. *Clin Orthop* 2004; 419:21-29.
7. Torricelli P, Fini M, Giavaresi G, Botter R, Beruto D, Giardino R. Biomimetic polymethylmethacrylate-based bone substitute: a comparative in vitro evaluation of the effects of pulsed electromagnetic field exposure. *J Biomed Mater Res A* 2003; 64:182-188.
8. Pickering SA, Bayston R, Scammel BE. Augmentation of antibiotic efficacy in infection of orthopaedic implants. *J Bone Joint Surg (Br)* 2003; 85-B:588-593.

Although the possible mechanisms underlying osteogenesis stimulated by PEMF are beyond the scope of this study, multiple biological responses such as angiogenesis, calcification, collagen production and/or osteogenic cell proliferation and differentiation, and growth factor production<sup>1,9,21</sup> would be involved. The membrane of a living cell forms an electrical as well as a chemical barrier that mediates cellular interactions with the external environment. For this reason, it is believed that cellular responses to weak electromagnetic fields are initiated by membrane interactions that serve as the primary mechanism of field transduction<sup>14</sup>.

In summary, short daily electromagnetic stimulation appears to be a promising treatment for acceleration of both bone-healing and peri-implant bone formation.

#### CORRESPONDENCE

Dr. Daniel R. Grana  
Facultad de Medicina - Universidad del Salvador  
Tucumán 1845 - piso 10 (C1050AAK)  
Ciudad Autónoma de Buenos Aires - Argentina  
e-mail: dgrana@salvador.edu.ar

9. Fredericks DC, Nepola JV, Baker JT, Abbott J, Simon B. Effects of pulsed electromagnetic fields on bone healing in a rabbit tibial osteotomy model. *J Orthop Trauma* 2000; 14:93-100.
10. Patiño O, Grana D, Bolgiani A, Prezzavento G, Merlo A. Efecto de los campos magnéticos sobre la cicatrización de la piel. Estudio experimental. *Medicina (Bs As)* 1996; 56:41-44.
11. Patiño O, Grana D, Bolgiani A, Prezzavento G, Merlo A, Miño J, Benaim F. Pulsed electromagnetic fields in experimental cutaneous wound healing in rats. *J Burn Care Rehab* 1996; 17:528-31.
12. Miño J, Tcherkansky D, Acevedo D, Patiño O, Rubio M. Campos electromagnéticos pulsantes de baja frecuencia: evaluación de sus posibles efectos sobre comportamiento, parámetros bioquímicos y enzimas microsomaes hepáticas (abstract). *Acta Physiol Pharmacol Ther Lat* 1995; 45:250.
13. Canadian Council on Animal Care (CCAC). Guide to the care and use of experimental animals. 2 vols. Ottawa, Ont.; 1980-1984.
14. Ottani V, Raspanti M, Martini D, Tretola G, Ruggeri A, Franchi M, Piccari GG, Ruggeri A. Electromagnetic stimulation on the bone growth using backscattered electron imaging. *Micron* 2002; 33:121-125.
15. Fiorelini JP, Nevins ML, Norkin A, Weber HP, Karimbux NY. The effect of insulin therapy on osseointegration in a diabetic rat model. *Clin Oral Impl Res* 1999; 10:362-368.
16. Clokie CML, Warshawsky H. Morphologic and radioautographic studies of bone formation in relation to titanium

- implants using the rat tibia as a model. *J Oral Maxillofac Implants* 1995; 10:155-165.
17. Buzzá EP, Shibli JA, Barbeiro RH, Barbosa JRA. Effects of electromagnetic field on bone healing around commercially pure titanium surface: Histologic and mechanical study in rabbits. *Implant Dent* 2003; 12:182-187.
  18. Fini M, Cadossi R, Cané V, Cavani F, Giavaresi G, Krajewski A, Martini L, Aldini NN, Ravaglioli A, Rimondini L, Torricelli P, Giardino R. The effect of pulsed electromagnetic fields on the osteointegration of hydroxyapatite implants in cancellous bone: a morphologic and microstructural in vivo study. *J Orthop Res* 2002; 20:756-763.
  19. Ijiri K, Matsunaga S, Fukuyama K, Yoshikuni N, Sakou T. The effect of pulsing electromagnetic fields on bone ingrowth into a porous coating implant. *J Jap Bioelect Res Soc* 1993; 7:79-82.
  20. Shimizu T, Zerwekh JE, Videman T, Gill K, Mooney V, Holmes RE, Hagler HK. Bone ingrowth into porous calcium phosphate ceramics: influence of pulsing electromagnetic fields *J Orthop Res* 1988; 6:248-258.
  21. Shankar VS, Simon BJ, Bax CMR, Pazianas M, Moonga BS, Adebajo OA, Zaidi M. Effects of electromagnetic stimulation on the functional responsiveness of isolated rat osteoclasts. *J Cell Physiol* 1998; 176: 537-44.