

## Dental skeletal effects of the metallic splinted Herbst appliance after growth spurt: a lateral oblique cephalometric assessment

Taisa B. Raveli, Dirceu B. Raveli, Luiz G. Gandini, Ary Santos-Pinto

Universidade Estadual Paulista - UNESP, Araraquara, São Paulo, Brazil

### ABSTRACT

The aim of this study was to evaluate dental and skeletal changes induced by the use of Herbst appliance compared to natural growth in young adults with Class II division 1 malocclusion with mandibular retrusion, by means of lateral oblique radiographs. Forty-six subjects, 14 - 18 years old, after pubertal growth peak, with Class II division 1 malocclusion were assessed. Subjects were divided into two groups: the Experimental group included 23 subjects treated with Metallic Splinted Herbst and the Control group included 23 subjects followed without treatment. The Experimental and Control groups were paired by sex and chronological age. Oblique lateral cephalometric radiographs of the left and the right side of the mandible before treatment (T1) and after 8 months' treatment (T2) were used to evaluate dental and skeletal

changes. Statistical analysis was performed with Intra Class Correlation and Student *t*-test, according to the study hypothesis. The results showed that the appliance corrected the Class II relationship in an 8-month period by mesial tipping movement of lower permanent first molars. It had little influence on mandibular structure and mandibular length and no influence on maxillary structure and upper molar. To conclude, late treatment of Class II malocclusion with the Herbst appliance was accomplished by means of dentoalveolar changes. These findings suggest that this type of treatment can be used in patients after growth has ceased because the results do not depend upon skeletal changes.

**Key words:** Angle Class II Malocclusion; Orthodontic Appliances, Activator; Orthodontics.

## Efeitos dento-esqueléticos do aparelho splint metálico de Herbst após surto de crescimento: estudo com telerradiografias em 45°

### RESUMO

O objetivo é avaliar mudanças dento esqueléticas induzidas pelo uso do aparelho de Herbst considerando crescimento natural através da telerradiografia cefalométrica em 45° em adultos jovens com Classe II divisão 1 e retrusão mandibular. Uma amostra de 46 indivíduos com idade entre 14 a 18 anos, após surto de crescimento pubertário, Classe II divisão 1 foram avaliados e divididos em dois grupos: grupo Experimental, 23 indivíduos que foram tratados com Herbst splint metálico e grupo Controle, 23 indivíduos que foram acompanhados sem tratamento. Os grupos experimental e Controle foram pareados por gênero e idade cronológica. Foram usadas telerradiografias cefalométrica em 45° dos lados esquerdo e direito da mandíbula antes do tratamento (T1) e após período

de 8 meses de tratamento e seguinte (T2) para avaliar as mudanças dento esqueléticas. Análise estatística foi realizada com o índice de Correlação Intra Classe e teste *t* de Student de acordo com a hipótese do estudo. Os resultados mostraram que houve correção da relação de Classe II no período de 8 meses por movimento mesial do primeiro molar inferior. O aparelho teve pequena influência na estrutura mandibular e comprimento mandibular e nenhuma influência na estrutura maxilar e molar superior. Em conclusão, o tratamento tardio da má-oclusão de Classe II com o aparelho MESPHER foi alcançado através de mudanças dento alveolares.

**Palavras chave:** Má oclusão de Angle Classe II; aparelhos Ativadores; ortodontia.

### INTRODUCTION

The concept of "jumping the bite" introduced by Kingsley in 1880 has been widely used by clinicians in the treatment of Angle Class II malocclusion associated with mandibular retrusion<sup>1,2</sup>. Orthopedic treatment has improved over time, leading to better removable orthopedic appliances<sup>3</sup>. In 1979 a fixed

version was reinstated by Pancherz with the name of its creator, Emil Herbst<sup>2,4</sup>.

Orthopedic appliances are usually used for correcting mandibular retrusion when the patient is still growing. It was formerly believed that it was not possible to achieve orthopedic correction Class II malocclusion with mandibular retrusion after

growth had ceased<sup>5</sup>. A review of the literature shows consensus that the best time for treatment would be immediately after the pubertal growth spurt because of the short growth period remaining. This would mean shorter retention time and immediate permanent intercuspation, which would prevent relapse<sup>5-11</sup>.

There has been increasing attention to use of the Herbst appliance not only in children and adolescents, but also for late treatment, i.e. in subjects who are at the end of their growth period or with no growth remaining<sup>5,10,12-15</sup>.

Most studies analyzing treatment with Herbst appliance use lateral radiographs. However, lateral to oblique radiographs offer the benefit of observing the mandibular structure on each side separately with no superimpositions of bone and tooth structures<sup>16,17</sup>.

The aim of this study was to evaluate changes induced by late orthopedic treatment with Herbst appliance for Class II division 1 malocclusion with mandibular retrusion in subjects with permanent dentition who were at the end of their growth period, through the use of lateral oblique cephalometric radiography.

## MATERIAL AND METHODS

This retrospective study was reviewed and approved by the Ethics Committee under number 39799514.3.0000.5416. The sample consisted of 46 patients who had Class II division 1 malocclusion with mandibular retrusion. Twenty-three consecutive patients (13 male and 10 female, mean age 15.6

years) were treated with a Metallic Splinted Herbst (MESPHER) appliance and assigned to the Experimental group. Another twenty-three patients without treatment were selected from *Burlington Growth Centre* archives and paired with the treated group by gender, age and malocclusion, and used as the Control group.

Inclusion criteria were bilateral Class II molar relationship; overjet greater than 5 mm and complete permanent dentition, except third molars. Exclusion criteria were patients with syndromes or extreme vertical growth pattern. Facial analysis consisting of convex profile, straight nasolabial angle, short mentocervical line and occlusal characteristics consisting of molar and canines in Class II (more than half cusp) and large overjet were used to determine that the subjects had skeletal Class II division 1 malocclusion.

Subjects in the Experimental group used Metallic Splinted Herbst (MESPHER) appliance (Fig.1) for eight months (mean  $8.50 \pm 0.70$  months) with one-step mandibular advancement to an incisor edge-to-edge relationship. The telescopic mechanism used was the Flip-Lock Herbst<sup>®</sup> (TP Orthodontics, Inc.) model. The upper anchorage was a metallic splint structure in which upper bicuspids and molars were held together and united by a transpalatal welded bar (Fig. 1A). The lower anchorage was a metallic splint structure in which lower bicuspids and molars were held together and united by a lingual welded bar (Fig. 1B).

Lateral oblique cephalometric radiographs of both sides of the mandible before treatment (T1) and after

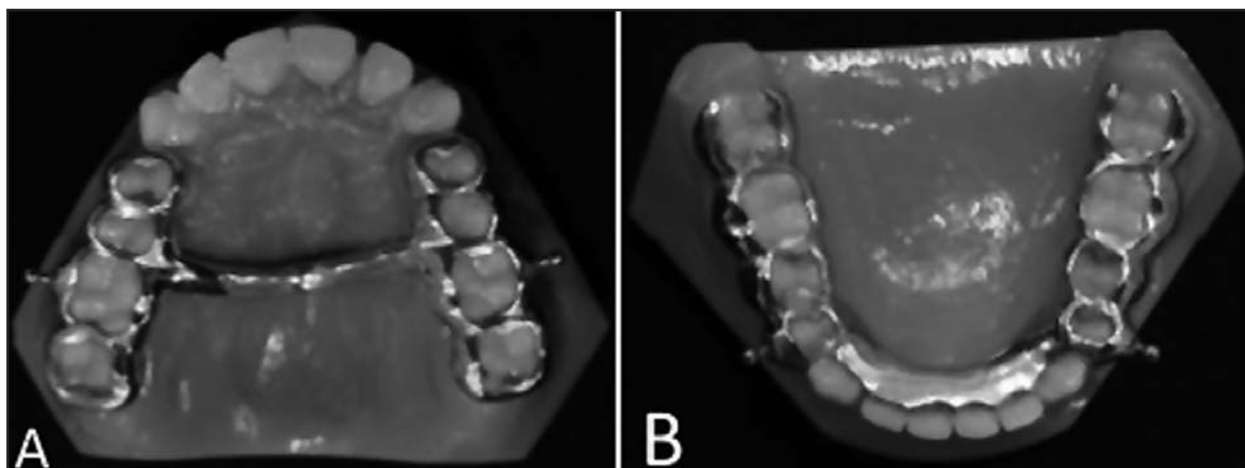


Fig. 1: Upper (1A) and lower (1B) metallic splint built as part of the anchorage system of the metallic splinted Herbst appliance (MESPHER).

treatment (T2) were used to evaluate dental skeletal changes induced by MESPHER. Radiographs were taken with a *Rotograph Plus MR05* device with 10% magnification. In the Control group, the same radiographs of both sides of the mandible of untreated patients were used to evaluate dental skeletal changes due to natural growth development at the same mean ages as subjects in the Experimental group. The radiographs were taken using a *Kelet* radiographic device with 9.84% magnification. Data from the Control and Experimental groups were adjusted to match the mean treatment time.

Skeletal age was verified in carpal radiographs by one investigator (T.B.R.), following Greulich and Pyle<sup>18</sup>, and indicated that patients were in the final pubertal growth phase.

Radiographs were digitized with *Numonics Accu Grid* table and the data were obtained using the software *Dentofacial Planner Plus 2.01*. Measurements were randomly reevaluated after two weeks by the same examiner and the error of the method was evaluated using Interclass Correlation Coefficient (ICC). Cephalometric analysis consisted of 16 points marked on right and left lateral oblique

radiographs of the mandible. A Cartesian coordinate system was used where the X-axis was defined as the horizontal line represented by the orbital plane determined in the initial radiograph (T1) and transferred to the subsequent radiograph through superimposition of the cranial stable structures<sup>19</sup>. The Y-axis was defined as the vertical line perpendicular to the orbital plane registered in a posterior fiducial point.

The distance of a perpendicular projection of selected dental and skeletal points in the T1 and T2 superimposed radiographs to the X-Axis and Y-Axis was measured to obtain horizontal and vertical dental and skeletal changes, respectively (Fig. 2), in both groups.

### Statistical Analysis

The following analyses were used to assess the study hypothesis: 1. *Interclass Correlation Coefficient* evaluate measuring method reproducibility; 2. *Student t-test* test mean equality between two independent populations, to test the hypothesis that a population's mean is equal to zero for each group separately and to test mean equality of two populations with independent samples; 3. *Student t-test* for mean equality of two populations with independent sample preceded by Levene test for variance equality. When Levene test showed different variances, Student t-test was corrected accordingly.

### RESULTS

The effects of treatment (Experimental group) compared to natural growth (Control group) showed skeletal and dental changes. Analysis of the horizontal and vertical mandibular changes on each side (Tables 1 and 2) showed that variables related to gonium (Go), mentonium (Me), mandibular length (Md length), horizontal length (Mdhor length), mandibular height (Md height) and mandibular angle (Md angle) underwent some small changes. Changes in the same variable differed on the right and left side of the mandible. Only the condyle (Co) presented no significant change. Maxilla showed no significant horizontal or vertical change regarding the points PNS and ANS (Table 1).

Regarding dental movements (Table 1), there were no significant horizontal and vertical changes for Upper First Permanent Molar, either for crown (UMC) or apex (UMA). However, Lower First Permanent Molar

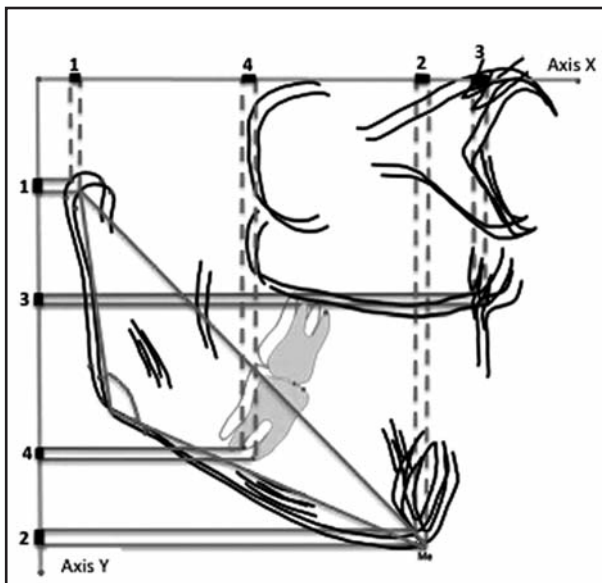


Fig. 2: Points projected on the X-axis (for horizontal changes) and Y-axis (for vertical changes). The displacement between projected points was measured. Examples for mandibular changes (1 and 2), maxillary changes (3), dental changes (4). Md length (linear distance between Condilium and Mentonium), Md height (linear distance between Condilium and Gonium), Md horizontal length (linear distance between Gonium e Mentonium), Md Angle (angle formed by intersection of the lines Co-Go and Go-Me).

**Table 1: Measurement changes over 8 months in treated and control groups. Mean difference and standard error (SE) .**

Variable	side	Horizontal				Vertical			
		Control	Experimental	difference		Control	Experimental	difference	
Co	R	1.70(1.4)	0.79(1.7)	0.91(0.5)	ns	0.33(1.8)	0.54(1.3)	0.21(0.5)	ns
	L	1.39(1.1)	2.15(1.9)	0.76(0.5)	ns	0.35(1.3)	1.43(2.7)	1.09(0.6)	ns
Go	R	1.35(1.8)	0.73(1.7)	0.62(0.5)	ns	1.32(1.7)	0.13(1.5)	1.45(0.5)	**
	L	1.61(1.4)	0.53(1.5)	1.08(0.4)	*	0.07(1.3)	0.45(1.5)	0.38(0.4)	ns
Me	R	0.24(0.7)	0.20(0.8)	0.04(0.2)	ns	0.14(0.8)	0.38(0.8)	0.53(0.2)	*
	L	0.05(0.6)	0.09(0.6)	0.14(0.2)	ns	0.34(0.6)	0.09(0.8)	0.25(0.2)	ns
ANS	R	0.15(2.6)	0.43(2.7)	0.57(0.8)	ns	0.67(2.2)	0.24(3.3)	0.43(0.8)	ns
	L	0.36(2.2)	1.05(2.5)	0.69(0.7)	ns	0.74(1.7)	0.63(3.5)	1.37(0.8)	ns
PNS	R	0.58(3.2)	1.29(4.3)	1.87(1.1)	ns	0.15(2.6)	0.43(2.7)	0.57(0.8)	ns
	L	0.66(3.6)	0.98(4.9)	0.33(0.3)	ns	0.36(2.2)	1.05(2.5)	0.69(0.7)	ns
UMC	R	0.34(3.7)	0.47(3.8)	0.13(1.1)	ns	1.12(1.8)	0.89(1.6)	0.23(0.5)	ns
	L	0.43(2.3)	1.91(4.2)	1.48(1.0)	ns	0.87(1.0)	0.04(1.9)	0.91(0.4)	ns
UMA	R	0.30(2.7)	0.97(2.6)	1.27(0.8)	ns	1.07(1.7)	0.98(1.5)	0.09(0.5)	ns
	L	0.62(2.0)	0.85(3.7)	0.23(0.9)	ns	0.89(1.0)	0.10(1.8)	0.79(0.4)	ns
LMC	R	0.32(0.9)	1.61(2.3)	1.93(0.5)	***	0.08(1.5)	0.20(1.8)	0.27(0.5)	ns
	L	0.28(1.0)	1.35(0.8)	1.63(0.3)	***	0.29(1.4)	0.00(1.6)	0.29(0.4)	ns
LMA	R	0.24(1.1)	0.57(0.2)	0.33(0.5)	ns	0.12(2.6)	0.13(4.3)	0.02(1.0)	***
	L	0.10(1.0)	0.19(1.3)	0.29(0.3)	ns	0.66(1.7)	0.12(4.6)	0.78(1.0)	ns

Student T Test:\*\*\* significant  $p < 0.001$  ; \*\* significant  $p < 0.01$  ; \* significant  $p < 0.05$  ; ns = not significant

Co (Condilium); Go (Gonium); Me (Mentoniano); ANS (anterior nasal spine); PNS (posterior nasal spine); UMC (upper molar cuspid)  
UMA (upper molar apex); LMC (lower molar cuspid); LMA (lower molar apex)

**Table 2: Mean and standard deviation of measurement changes over 8 months in treated and control groups. Mean difference and standard error (SE).**

Variable	side	Control	Experimental	difference	
Md length	R	1.75(1.8)	0.78(2.2)	0.97(0.6)	ns
	L	1.08(1.7)	2.32(2.4)	1.23(0.6)	*
Md height	R	1.69(2.0)	0.41(2.0)	1.27(0.6)	*
	L	0.47(1.7)	2.15(3.0)	1.68(0.7)	*
Md hor length	R	1.14(2.0)	0.77(1.5)	0.38(0.5)	ns
	L	1.47(1.8)	0.23(1.5)	1.23(0.5)	*
Md angle	R	0.96(2.2)	0.39(2.4)	0.57(0.7)	ns
	L	0.95(1.4)	0.69(1.9)	1.64(0.5)	**
Incl molar inf	R	0.95(6.3)	3.49(4.6)	4.44(1.6)	**
	L	0.63(3.4)	4.81(3.5)	5.44(1.0)	***

Student T test: \*\*\* significant  $p < 0.001$  ; \*\* significant  $p < 0.01$  ;

\* significant  $p < 0.05$  ; ns = not significant

Md Length (mandibular length); Md height (mandibular height); md hor length (mandibular horizontal length)  
md angle (mandibular angle); incl molar inf (inclination of lower permanent molar)

had a very significant horizontal change in crown (*LMC*) in mesial direction and showed no apex changes (*LMA*), leading to a significant increase in its inclination (*Incl Molar Inf*) as a result of the treatment (Tables 1 and 2). Additionally, there is statistical evidence that a vertical change occurred on the right side for Lower First Permanent Molar apex (*LMA*) but not on the left side.

## DISCUSSION

This lateral oblique cephalometric study evaluated dental skeletal alterations in subjects with Class II division 1 with mandibular retrusion who were treated with a metallic splinted Herbst appliance. Forty-six patients with mean age 15.6 years were analyzed and divided into treatment and control groups. Although there is an understanding that this kind of treatment would be more appropriate during the pubertal growth peak<sup>7,8,20-24</sup>, some studies have shown that treatment through mandibular advancement can be accomplished after this phase<sup>5,6,9,11-15,25</sup>.

The condyle region presented no significant vertical and horizontal changes after treatment on either side (right or left) in this sample of young adult patients. In contrast, most studies with Herbst appliance using lateral cephalometric radiographs report different results. In a systematic review, Cozza et al.<sup>8</sup> showed that supplementary condylar growth is considerably higher when orthopedic treatment is performed during adolescence. Pancherz<sup>3</sup> observed horizontal condylar growth but no vertical change in the treatment group. Ruf and Pancherz<sup>2</sup> examined two treatment groups with ages 12 and 16 years, and observed condylar changes in both groups; however, this change remained only in the 16-year-old group after appliance removal. Subsequently, the same authors<sup>10</sup> reported that patients treated 1 or 2 years after pubertal growth peak showed more horizontal condylar growth. Lateral oblique cephalometry allows more precise analysis of each side of the maxilla-mandibular structures and dental components without the disadvantage of superimposition.

Mandible remodeling could be expected as an effect of the treatment. The gonium region showed some horizontal (left side) and vertical (right side) changes. In contrast, Hägglund, Segerdal and Forsberg<sup>21</sup> (2008) observed in 14-year-old boys no difference in mandibular angle after treatment. In agreement with our results, Pancherz<sup>3</sup> reported some

resorption of the posterior part of the mandibular body that coincides with the gonial region and also observed that the gonial angle opened in patients submitted to Herbst treatment and closed in the control group. The symphysis region showed a slight vertical change on the right side. This region was used as a superimposition structure in this study because it was considered to be a stable region<sup>3,15</sup>, and was not expected to change over the 8-month period of observation. As result of this remodeling, the mandibular angle increased on the left side. Ruf and Pancherz<sup>11</sup> reported similar results, observing an increase in mandibular angle during treatment in individuals with ages ranging from 15 to 44 years, although it subsequently decreased slightly after appliance removal. Nevertheless different responses in mandibular structure were not enough to produce asymmetry in the final outcome.

Considering effective mandibular length (*Md length*), a slight difference occurred on the left side. In a systematic review<sup>22</sup>, it was reported that some studies found an increase in mandibular length whereas others reported no change. Similarly, Flores-Mir et al.<sup>23</sup>, concluded that mandibular length increased in the studies analyzed. Hägglund, Segerdal and Forsberg<sup>21</sup> found no skeletal change between treatment and control groups in a study on 14-year-old boys. Likewise, Konik, Pancherz and Hansen<sup>9</sup> reported no mandibular increase in a treatment group after pubertal growth peak. However, Pancherz<sup>3</sup> found an increase in mandibular length three times higher in the treatment group than in the control group. Subsequently, Ruf and Pancherz<sup>5</sup> reported less mandibular increase and more dental movement in 16-year-old subjects. In 2003, the same authors<sup>10</sup> reported an increase in mandibular length in patients treated 1 or 2 years after the pubertal growth peak. This inconsistency was explained by the fact that different measurements were used in each study.

Mandibular horizontal length has not been widely discussed and has only been evaluated by Pancherz<sup>3</sup>, who observed a decrease in the length of mandibular corpus after treatment. This is in agreement with our results, which showed a small change in the gonium on the left side as part of the mandible remodeling process.

Mandibular height changed significantly in the vertical direction on both sides of the mandible. In agreement with this result, the systematic review by Flores-Mir et al.<sup>23</sup> found an increase in

mandibular height in the studies analyzed. Pancherz<sup>3</sup> also reported that in a retention period after 7 years of appliance removal, treated patients presented increased mandibular height while the control group did not. Horizontal and vertical gonium remodeling must have contributed to this height change, considering that the condyle did not undergo any modification.

Information in the literature on maxillary bone only reports that there was restriction of its displacement as the effect of treatment. Only Pancherz<sup>3</sup> reported maxillary restriction during treatment. Our results show that the anterior and posterior nasal spine had the same pattern of horizontal and vertical movements as in the control group, indicating that the treatment did not change the natural displacement of the maxilla, in agreement with other studies<sup>9,11,21,22</sup>. The stability of the maxillary position may be attributed to the metallic splint utilized as anchorage.

Dental movement appeared to be more marked. High significance was observed on both sides on lower permanent first molar for crown and no significance whatsoever for apex in horizontal assessment. It is understood that mesial inclination occurred, also confirmed by a measurement that showed great significance for axial movement. Barnett et al.<sup>22</sup> also observed extrusion and mesial movement of lower first permanent molars. Most studies with Herbst appliance on subjects of the same age agree with these results<sup>3,5,22,23</sup>, confirming that Class II is corrected mostly by dental movement. With regard to vertical assessment, significance was low for the apex region on the right side. It is understood that extrusion might have occurred. This difference between sides in our study is less than 1mm, being slightly greater on right side than on the left side in absolute values. This small

sample difference between sides is what causes this apparent contradiction in the results.

Upper first permanent molars, on the other hand, showed no change, indicating positional stability which could be attributed to the metallic splint used as anchorage. This result contrasts with the literature, which reports intrusion<sup>22</sup> and distal movement<sup>3,23</sup> of the upper molar in conventional Herbst anchorage.

Overall, studies seem to be positive in relation to late treatment for Class II with mandibular retrusion. A recent study<sup>7</sup> concluded that treatment of this kind of malocclusion with the Herbst appliance is equally efficient in adolescents and adults, opening a new option even for borderline patients, because most results for late treatment are more dental than skeletal<sup>3,24</sup>. To paraphrase Pancherz<sup>3</sup>, the Herbst appliance improves mandibular positioning in the long term, but does not normalize it. Dental sagittal relation, on the other hand, is practically normalized. Therefore, in the long term, dental effects compensate an unfavorable mandibular relation.

It can be concluded from this study that the treatment of Class II with mandibular advancement using metallic splinted Herbst showed small skeletal influence on the mandible in 14- to 18-year-olds. Dental effects were more significant for the correction of Class II, emphasizing the correction by lower first molar tipping to mesial direction. There is evidence that the mandible responds differently on each side when undergoing an 8-month mandibular advancement treatment. Nevertheless, this differential response is not marked enough to produce an asymmetric final outcome or compensate some small differences between sides due to asymmetric functional masticatory balance.

#### CORRESPONDENCE

Dr. Taisa Raveli

Avenida Portugal, 887 – Centro

CEP 14.801-075 Araraquara-SP Brazil

taisaraveli@yahoo.ca

#### REFERENCES

1. Angle EH. Classification of malocclusion. *Dental Cosmos* 1899; 41: 248-264. <https://quod.lib.umich.edu/d/dencos/acf8385.0041.001/266:56?rgn=main;view=image>
2. Pancherz H. History, background and development of the Herbst appliance. *Semin Orthod* 2003; 9: 3-11.
3. Pancherz H. The effects, limitations and long-term dentofacial adaptations to treatment with the Herbst appliance. *Semin Orthod* 1997; 3: 232-243.
4. Pancherz H. Treatment of Class II malocclusions by jumping de bite with the Herbst appliance. A cephalometric investigation. *Am J Orthod Dentofacial Orthop* 1979; 76: 424-442.

5. Ruf S, Pancherz H. Dentoskeletal effects and facial profile changes in young adults treated with the Herbst appliance. *Angle Orthod* 1999; 69: 239-246.
6. Bock NC, Bremen J, Ruf S. Occlusal stability of adult Class II Division I treatment with the Herbst appliance. *Am J Orthod Dentofacial Orthop* 2010; 138: 146-151.
7. von Bremen J, Bock N, Ruf S. Is Herbst-multibracket appliance treatment more efficient in adolescents than in adults? *Angle Orthod* 2009; 79: 173-177.
8. Cozza P, Baccetti T, Franchi L, Toffol L et al. Mandibular changes produced by functional appliances in Class II malocclusion: A systematic review. *Am J Orthod Dentofacial Orthop* 2006; 129: 599.e 599-1.e12.
9. Konik M, Pancherz H, Hansen K. The mechanism of Class II correction in the late Herbst treatment. *Am J Orthod Dentofacial Orthop* 1997; 112: 87-91.
10. Ruf S, Pancherz H. When is the ideal period for the Herbst therapy-early or late? *Semin Orthod* 2003; 9: 47-56.
11. Jakobsone G, Latkauskiene D, McNamara Jr J. Mechanisms of Class II correction induced by the crown Herbst appliance as a single-phase Class II therapy: 1 year follow-up. *Prog Orthod* 2013, 14:27.
12. Pancherz H, Bjerklin K, Hashemi K. Herbst therapy: A 32-year longitudinal follow-up study. *Am J Orthod Dentofacial Orthop* 2015; 147:19-28.
13. Pancherz H, Bjerklin K, Lindskog-Stokland B, Hansen K. Thirty-two-year follow-up study of Herbst therapy: A biometric dental cast analysis. *Am J Orthod Dentofacial Orthop* 2014; 145:15-27.
14. Yang X, Zhu Y, Long H, Zhou Yet al. The effectiveness of the Herbst appliance for patients with Class II malocclusion: a meta-analysis. *Eur J Orthod* 2015, 1-10.
15. Ruf S, Pancherz H. Herbst/multibracket appliance treatment of Class II division I malocclusions in early and late adulthood. A prospective cephalometric study of consecutively treated subjects. *Eur J Orthod*.2006; 28: 352-360.
16. Cartwright LJ, Harvold E. Improved radiographic results in cephalometry through the use of high kilovoltage. *J Can Dent Assoc* 1954; 20: 261-263.
17. Posen AL. Vertical height of the body of the mandible and the occlusal level of the teeth in individuals with cleft and non-cleft palates. *J Can Dent Assoc* 1958; 1: 211-218.
18. Greulich WW, Pyle SI. Radiographic atlas of skeletal development of the hand and wrist. California: Stanford University Press; 1959.
19. Sakima MT, Sakima CG, Melsen B. The validity of superimposing oblique cephalometric radiographs to assess tooth movement: an implant study. *Am J Orthod Dentofacial Orthop* 2004; 126: 344-353.
20. Franchi L, Baccetti T, McNamara Jr JA. Treatment and posttreatment effects of acrylic splint Herbst appliance therapy. *Am J Orthod Dentofacial Orthop* 1999; 115: 429-438.
21. Hagg U, Pancherz H. Dentofacial orthopaedics in relation to chronological age, growth period and skeletal development. An analysis of 72 male patients with Class II division I malocclusion treated with the Herbst appliance. *Europ J Orthod* 1988;10:169-176.
22. Pancherz H. The effect of continuous bite jumping on the dentofacial complex: a follow-up study after Herbst appliance treatment of Class II malocclusions. *Europ J Orthod* 1981; 3: 49-60.
23. Pancherz H, Hagg U. Dentofacial orthopedics in relation to somatic maturation. An analysis of 70 consecutive cases treated with the Herbst appliance. *Am J Orthod Dentofacial Orthop* 1985; 88: 273-287.
24. Pancherz H, Hensen K. Occlusal changes during and after Herbst treatment: a cephalometric investigation. *Europ J Orthod* 1986; 8: 215-228.
25. Hägglund P, Segerdal S, Forsberg CM. The integrated Herbst appliance -treatment effects in a group of adolescent males with Class II malocclusions compared with growth changes in an untreated control group. *Europ J Orthod* 2008; 30: 120-127.