

Comparison of Mineral Density in Molar Incisor Hypomineralization applying fluoride varnishes and casein phosphopeptide-amorphous calcium phosphate

Ana M. Biondi, Silvina G. Cortese, Lucía Babino, Diana E. Fridman

Universidad De Buenos Aires, Facultad de Odontología, Cátedra Odontología Integral Niños. Buenos Aires, Argentina.

ABSTRACT

The aim of the present work was to evaluate and compare variations in mineral density (MD) using laser-induced fluorescence (LF) after applying 5% Sodium Fluoride Varnish (Duraphat®), 5% Sodium Fluoride Varnish with Tricalcium Phosphate (Clinpro®) or Casein phosphopeptide-amorphous calcium phosphate (Recaldent®) on teeth with Molar Incisor Hypomineralization (MIH). Mineral density of 92 MIH teeth with mild (Mi) and moderate (Mo) lesions was assessed using a DIAGNOdent device (KaVo, Biberach, Germany). LF values were recorded on day 0 (baseline) and on days 15, 30 and 45; the remineralizing agents were applied immediately after LF

readings at baseline and on days 15 and 30. Data corresponding to Mi and Mo lesions were analyzed separately. Significant differences were observed both in mild ($p < 0.01$) and moderate ($p < 0.000005$) lesions. Differences between Recaldent® and Clinpro®, and between Duraphat® and Clinpro® (global level 0.10) were found in Mi lesions. All 3 pairs of products differed significantly in Mo lesions (global level 0.05). The results obtained under the conditions used here allow concluding that Clinpro® was more effective in mild lesions whereas Duraphat® was more effective in moderate lesions.

Key words: Dental enamel, dental enamel hypoplasia, lasers.

Comparación de Densidad Mineral en Hipomineralización Molar Incisiva aplicando barnices fluorados y fosfopéptidos de caseína-fosfato de calcio amorfo

RESUMEN

El objetivo del trabajo fue evaluar y comparar la variación de la densidad mineral (MD) registrada con láser de fluorescencia (LF), posteriormente a la aplicación de barniz fluorado al 5% (Duraphat®), barniz fluorado al 5% con fosfato tricálcico (Clinpro®) y fosfopéptidos de caseína-fosfato de calcio amorfo (Recaldent®) en piezas con Hipomineralización Molar Incisiva (MIH). La MD de 92 piezas dentarias con MIH con lesiones leves (Mi) y moderadas (Mo) fue registrada utilizando el equipo DIAGNOdent (KaVo, Biberach, Germany). Los valores de LF fueron registrados en el día 0 (condiciones basales) y en los días 15, 30 y 45. Los agentes remineralizantes fueron aplicados inmediatamente luego de los registros de LF en condiciones

basales y en los días 15 y 30. A los 45 días se observaron diferencias significativas tanto en las lesiones leves ($p < 0,01$) como en las moderadas ($p < 0,000005$). En las lesiones leves se detectaron diferencias significativas entre los productos Recaldent® y Clinpro® y entre Duraphat® y Clinpro® a nivel global 0,10. En las lesiones moderadas los tres pares de productos resultaron significativamente diferentes a nivel global 0,05. Los resultados obtenidos permiten concluir que, en las condiciones de este estudio, Clinpro® resultó más efectivo en lesiones leves, mientras que Duraphat® lo fue en lesiones moderadas.

Palabras Clave: Esmalte dental, hipomineralización del esmalte, láseres.

INTRODUCTION

The term Molar Incisor Hypomineralization (MIH) was accepted at the Meeting of the European Academy of Pediatric Dentistry in 2003¹ to define qualitative enamel defects affecting the first permanent incisors and molars caused by an alteration during the post-secretion period of ameloblasts, and was typified as a hypocalcification defect in 2010². At present, lesions are frequently observed on second primary molars

and permanent canines, and MIH is also detected on other teeth^{3,4}.

Its etiology remains uncertain, and it has been suggested that it may not be caused by a single specific factor but that various conditions, including genetic factors, could increase the risk for MIH.

Previous studies conducted by our research group showed 15.9% prevalence of MIH in a population of 1098 children seeking dental care⁵, and 25.92% prevalence in children not seeking dental care.⁶

Mild or moderate lesions present clinically as creamy-white or yellowish-brown opacities, and severe lesions present loss of structure. As observed by scanning electron microscopy, lesions without loss of enamel substance exhibit normal, though less regular and less differentiated prism structure, with a lack of organization of the enamel crystals, greater inter-prism space, presence of pores, and sharp demarcation between the sound and the hypomineralized enamel^{7,8}. Creamy-white lesions show prisms with more rounded ends than those seen in sound enamel, and occasionally exhibit cracks. Brown lesions show larger cracks and scale-like alterations.⁹ Analysis of the mineral content of the hypomineralized areas shows a significant decrease in P and increase in C and Mg, with a lower Ca:C ratio¹⁰. Protein content is 8-fold higher in mild lesions than in sound enamel, and 15 to 21 fold higher in moderate lesions as compared to sound enamel. MIH-affected enamel has normal levels of residual amelogenins, indicating the occurrence of hypocalcification rather than hypomaturation².

In vitro studies have shown intensity of fluorescence to be inversely proportional to mineral density (MD), and propose the use of laser induced fluorescence to assess the severity of the defects¹¹. A previous work conducted by our research group showed lower MD as recorded by laser fluorescence (LF) in clinically intact enamel of MIH patients than in patients without MIH, as well as a relation between visual observation of enamel color changes and LF readings¹².

As to preventive treatment for MIH-affected teeth, there is no evidence to date regarding its efficacy. Hence, recommendations are based on studies conducted in unaffected teeth.

Based on the above, the aim of the present work was to evaluate and compare variations in mineral density recorded with laser fluorescence after applying varnishes containing 5% fluoride, 5% fluoride and tricalcium phosphate, and casein phosphopeptide-amorphous calcium phosphate in teeth with Molar Incisor Hypomineralization.

MATERIALS AND METHODS

The experimental design of the present study was approved by the Ethics Committee of the School of Dentistry, University of Buenos Aires (FOUBA) (UBACyT20720120200007BA), and the study

was conducted in compliance with the ethical principles for medical research in human beings defined in the Declaration of Helsinki (revised in 2013).

The study comprised 55 children aged 6 to 17 years seeking dental care at the Department of Pediatric Dentistry, University of Buenos Aires in 2013, 2014 and 2015, showing MIH lesions, and whose parents/legal tutors gave their informed consent for participation in the study. All the patients received indications regarding diet and oral hygiene with 1000 ppm fluoridated toothpaste. Open caries lesions were inactivated with a reinforced zinc oxide-eugenol material (IRM® Dentsply Caulk). Twenty-nine (29) children seen in 2013 were treated with 3 applications of 5% sodium fluoride varnish (Colgate Duraphat®) for 1 minute; 16 children seen in 2014 were treated with casein phosphopeptide-amorphous calcium phosphate CPP-ACP (GC America, MI Paste™ Recaldent®), and 10 children seen in 2015 were treated with 5% sodium fluoride varnish containing tricalcium phosphate (TCP) (3M ESPE, Clinpro™ White Varnish). Mineral density of 92 teeth with MIH without loss of enamel substance (37 treated with Duraphat®, 33 with Recaldent® and 22 with Clinpro™) was assessed using DIAGNOdent (KaVo, Biberach, Germany); all determinations were performed by a single operator who was calibrated in the use of the device and who calibrated the instrument prior to each reading in keeping with the manufacturer's recommendations. After drying the enamel with a triple syringe for approximately 8", laser fluorescence (LS) of smooth enamel surfaces with creamy-white (Mi) and yellowish-brown (Mo) opacities larger than 2 mm in diameter (Figs. 1 and 2) was measured. LF values were recorded on day 0 (baseline) and on days 15, 30 and 45; the remineralizing agents were applied immediately after LF readings at baseline and days 15 and 30.

Data corresponding to Mi and Mo lesions were analyzed separately; mean LF of the examined teeth at baseline and at 15, 30 and 45 days, as well as the percentage of variation in mean LF throughout the 45 day period were calculated for each patient. Percentage of variation of the three studied products was analyzed in each group using non parametric ANOVA, and among groups using Bonferroni's multiple comparison test.

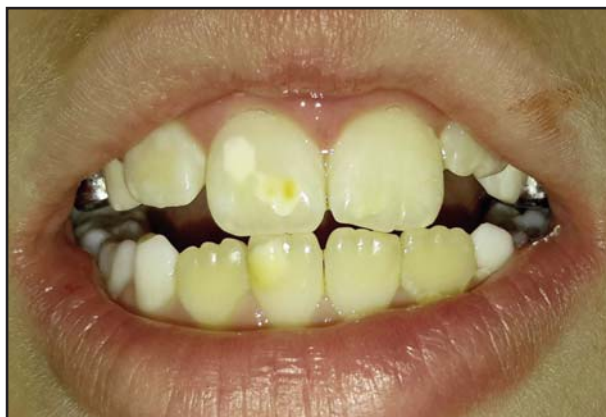

Fig. 1: Upper right incisor showing both mild and moderate MIH lesions simultaneously.

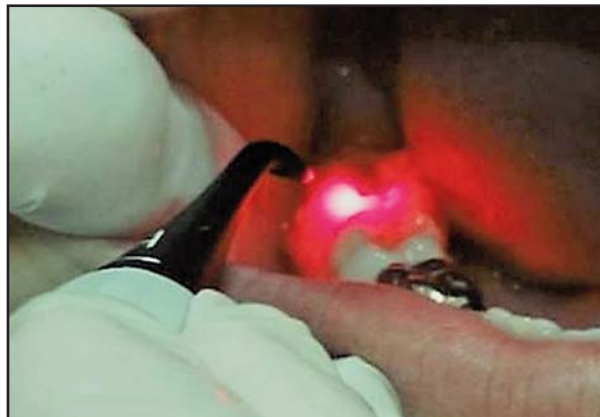

Fig. 2: Mineral Density determinations using laser induced fluorescence.

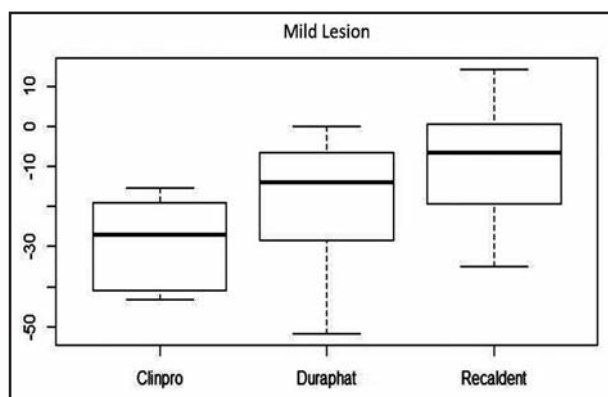


Fig. 3: Variations in LF in mild lesions MD: Mineral Density.

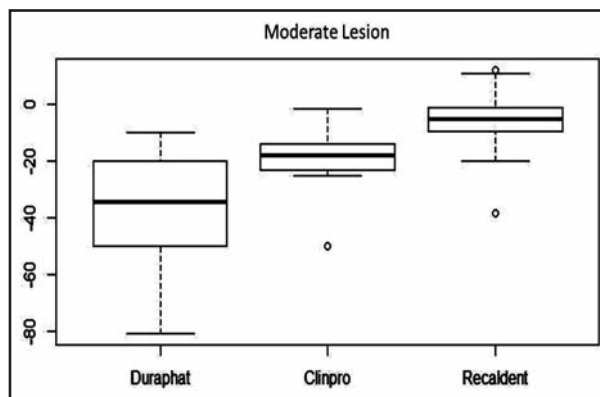


Fig. 4: Variations in LF in moderate lesions MD: Mineral Density.

RESULTS

Tables 1, 2 and 3 show mean values, standard deviation, and ranges of laser fluorescence readings for each product in each group at baseline and 15 days after each application.

Significant differences in the percentage of variation in FL were observed among the 3 products both in the mild ($p < 0.01$) and the moderate lesions groups ($p < 0.000005$) (Table 4).

Figures 3 and 4 are parallel boxplots showing the percentage of variation of the 3 products in the Mi and Mo lesions groups.

Analysis of results using multiple comparisons test showed significant differences between Recaldent® and Clinpro®, and between Duraphat® and Clinpro® in the mild lesions group, at a global level of significance of 0.10. Significant differences were observed among all 3 pairs of products in the moderate lesions group, at a global level of significance of 0.05.

DISCUSSION

Ameloblasts are not only responsible for secreting the enamel matrix proteins and proteinases, but also induce mineralization and finally organize these minerals into rod and interrod patterns¹³. Because MIH lesions do not develop during the secretion period, they are considered qualitative enamel defects; they present clinically as opacities, and can occasionally lead to enamel fracture as a consequence of mastication. To date, MIH diagnosis is performed based on the clinical appearance of the lesions. However, given the lack of defined criteria and discrepancies among authors, this method is subjective and unreliable. *In vitro* studies have concluded that the severity of the defect can be assessed using laser fluorescence as an indicator of MD¹¹. The method has been validated by a number of studies¹⁴⁻¹⁷, and has been shown to be effective for assessing remineralization on smooth enamel surfaces¹⁸. It allows quantitatively estimating MD in

Table 1: LF values corresponding to teeth treated with Colgate, Duraphat® Mean ± SD and range.

Clinical Appearance	Laser fluorescence Values				
	Baseline	Day 15	Day 30	Day 45	
Mild lesions	18.57±5.88	16.97±5.39	15.42±5.45	14.59±4.88	p<0.001
	(16.55-20.59)	(15.12-18.82)	(13.55-17.3)	(12.92-16.27)	
Moderate lesions	56.88±15.71	37.83±12.77	33.47±12.05	31±11.97	
	(45.48-56.28)	(33.45-42.23)	(29.33-37.61)	(26.87-35.11)	

Table 2: LF values corresponding to teeth treated with GC America, MI Paste™.

Clinical Appearance	Laser fluorescence Values				
	Baseline	Day 15	Day 30	Day 45	
Mild lesions	17.37±7.22	16.18±5.36	15.4±15.19	15.15±5.19	<0.001
	(12.64-22.11)	(14.22-17.77)	(13.22-16.77)	(13.22-16.77)	
Moderate lesions	29.53±17.85	28.02±15.59	26.42±15.50	27.31±15.77	
	(24.79-34.27)	(22.68-33.31)	(20.68-31.31)	(21.68-32.31)	

Mean ± SD and range

Table 3: LF values corresponding to teeth treated with 3M ESPE, Clinpro™ White Varnish.

Clinical Appearance	Laser fluorescence Values				
	Baseline	Day 15	Day 30	Day 45	
Mild lesions	20.04±5.07	18.36±4.51	15.39±3.67	14.18±3.65	p<0.005
	(13.75-27.63)	(11-24.25)	(11.25-23.38)	(10.5-22.38)	
Moderate lesions	28.85±8.99	26.8±8.16	25.2±8.83	23.1±7.74	
	(15-48.5)	(15-43.25)	(14-42.75)	(11.5-36.25)	

Mean ± SD and range

Table 4: Percentage of variation in LF values corresponding to each of the 3 studied products at 45 days.

Clinical Appearance	Laser fluorescence Values			
	Duraphat®	Recaldent®	Clinpro®	
Mild lesions	-19.61±15.02	-9.30±14.66	-28.32±10.56	p<0.01
	(-51.85;0)	(-35.09;14.29)	(-43.12;-15.45)	
Moderate lesions	-36.58±19.78	-6.60±11.69	-19.79±12.65	p<0.000005
	(-80.74;-10)	(-38.36;11.96)	(-50;-1.59)	

Mean ± SD and range

a non-invasive fashion, as well as assessing the severity of the defects on the affected teeth at baseline prior to treatment, and then evaluating the effectiveness of products commonly used to treat caries-related lesions.

The deficiency in mineral enamel in MIH occurs during amelogenesis. It is therefore not known whether the measures used to treat chemical demineralization caused by acid attack could be effective in correcting the mineralization deficiency

after tooth eruption. It is possible that the de- and re-mineralization processes occurring in sound enamel and those occurring in hypomineralized MIH enamel share comparable mechanisms. In addition, treatment of MIH may entail the same difficulties encountered in the management of dental caries to attain in-depth remineralization of enamel. Whichever way, it must be emphasized that these two pathologies differ greatly, since the enamel of teeth affected by MIH, including apparently intact areas of enamel, is sufficiently porous to allow bacterial invasion, even in areas of the tooth considered at low caries risk in non-MIH teeth.

The present study included all patients presenting MIH-affected teeth with both creamy-white and yellow-brown lesions seen at the Department of Dentistry for Children in the same period (May-July) in 2013, 2014, and 2015. All patients were assessed by the same operator with the same device. We chose to analyze the percentage of variation of average LF given the differences among the baseline ranges of the studied periods.

A 2006 review of the clinical management of MIH emphasized the need to promote an increase in mineralization and a decrease in hypersensitivity¹⁹. The present study compared three products, one of which is a fluoride varnish added with calcium ions. The addition of 5% tricalcium phosphate to fluoride containing varnishes, as is the case of Clinpro, is intended to increase the retention of fluoride and calcium ions in the oral environment, and improve mineralization of early lesions. Another of the studied products, CPP-ACP, provides bioavailable calcium and phosphate to promote remineralization. Although *in vitro* studies have shown that it interacts with hydrogen ions on the tooth surface, and can diffuse into enamel where it produces subsurface mineral gains, a recent review suggests that further controlled trials need to be conducted prior to the widespread recommendation of CPP-

ACP for the prevention and treatment of caries²⁰. The protocol used in the present study for application of CPP ACP was similar to protocols used in comparative studies on fluoridated varnishes^{21,22}. Rather than a single application, Reynolds²³ suggests it is recommendable for the product to be in contact with the tooth surface for 1 minute to 2 hours, from 5 to 60 minutes, or for 10 minutes, and that application can be repeated for 1 day or several months. In the present study, we used three 1-minute applications without pre-treating the enamel with 5% NaOCl for 5 minutes, as has been suggested.

According to the data obtained herein, Duraphat[®] showed the best results, followed by Clinpro[®] in moderate lesions. Clinpro[®] was only significantly better than Recaldent[®] and Duraphat[®] in mild lesions. Nevertheless, the present results do not allow concluding that the 5% sodium fluoride varnish without TCP (Duraphat[®]) was superior to the CPP ACP (Recaldent[®]). A survey conducted in public health professionals in Norway showed variations in their preventive approach to this pathology. Nevertheless, half the professionals applied fluoridated varnishes on lesions without loss of tissue, as were the lesions studied here²⁴. Restrepo et. al²⁵ also used laser fluorescence as an indicator of mineral density, and found no beneficial effects after 4 applications of fluoridated varnishes. However, the authors state that their results do not suggest that fluoridated varnish should not be recommended for the treatment of MIH lesions.

CONCLUSIONS

The results obtained herein allow concluding that Clinpro[®] was more effective in mild lesions, whereas Duraphat[®] proved to be more effective in moderate lesions. Further studies in a larger number of patients need to be conducted to corroborate the present findings.

ACKNOWLEDGMENTS

The authors thank Prof Ricardo Luis Macchi PhD for his valuable methodological advice and support.

The authors have no conflict of interest to declare with regard to the present study. The project was funded by the University of Buenos Aires (UBACyT 20720120200007BA).

CORRESPONDENCE

Dr. Ana María Biondi
M.T. de Alvear 2142. Piso 15 Sector A
5287-6000 Int: 76434
+54 911 479 1283
anamariabiondi@hotmail.com

REFERENCES

- Weerheijm KL. Molar Incisor Hypomineralisation (MIH). *Eur J Paed Dent* 2003; 4: 115-120.
- Mangum JE, Crombie FA, Kilpatrick N, Manton DJ, Hubbard MJ. Surface integrity governs the proteome of hypomineralized enamel. *J Dent Res* 2010;89:1160-1165.
- Toscano M, Ortolani A, Cortese S, Biondi AM. Hipomine-ralización Molar Incisiva: Factor de Riesgo de Opacidades en Caninos Permanentes XLVII Reunión de la Sociedad Argentina de Investigación Odontológica, 2014 Disponible en http://www.saio.org.ar/XLVII_REUNION_ANUAL.pdf.
- Ortolani A, Cortese S, Biondi AM. Hipomine-ralización Molar Incisiva: Riesgo de Opacidades en otras Piezas Dentarias. 17º Congreso Latinoamericano-ALOP 6º Congreso Paulista-APO. San Pablo, 2014 URL: <https://www.revistaodonto-pediatria.org/ediciones/2014/2/art-10/>
- Biondi AM, Cortese SG, Martínez K, Ortolani AM et al. Prevalence of molar incisor hypomineralization in the city of Buenos Aires. *Acta Odontol Latinoam* 2011;24:81-85.
- Biondi AM, Cortese SG, Ortolani AM, Ienco M, Argentieri AB. Prevalencia de hipomine-ralización molar incisiva en niños con y sin demanda de atención. *Rev Asoc Odontol Argentina* 2013; 101:139-145
- Fagrell TG, Dietz W, Jälevik B, Norén JG. Chemical, mechanical and morphological properties of hypomine-ralized enamel of permanent first molars *Acta Odontol. Scand* 2010; 68: 215-222.
- Crombie FA, Manton DJ, Palamara JE, Zalzniaik I, Cochrane NJ, Reynolds EC. Characterisation of developmentally hypomine-ralised human enamel *J Dent.* 2013;41:611-618.
- Bozal CB, Kaplan A, Ortolani A, Cortese GS, Biondi AM. Ultrastructure of the Surface of Dental Enamel with Molar Incisor Hypomineralization with and without acid etching. *Acta Odontol Latinoam* 2015; 28:192-198.
- Jälevik B, Odelius H, Dietz W, Noren J. Secondary ion mass spectrometry and X-ray microanalysis of hypomine-ralized enamel in human permanent first molars. *Arch Oral Biol* 2001; 46: 239-247.
- Farah R, Drummond B, Swain M, Williams S. Linking the clinical presentation of molar-incisor hypomine-ralisation to its mineral density. *Int J Paed Dent* 2010; 20:353-360.
- Fridman D, Cortese SG, Biondi AM. Clinical Aspect and Reduction in Mineral Density using Laser Fluorescence in Hypomine-ralization. *J Dent Res Abstract Archives. Argentine Division Meeting (Argentina):* 95, 2013. URL: <https://iadr.abstractarchives.com/abstract/argentine13-193288/clinical-aspect-and-reduction-in-mineral-density-u-sing-laser-fluorescence-in-hypomine-ralization>
- Abou Neel EA, Aljabo A, Strange A, Ibrahim S et al. Demine-ralization–remineralization dynamics in teeth and bone. *Int J Nanomedicine* 2016;11:4743-4763.
- Gambetta-Tessini K, Mariño R, Ghanim A, Adams GG, Manton DJ. Validation of quantitative light-induced fluorescence-digital in the quantification of demarcated hypomine-ralized lesions of enamel. *J Investig Clin Dent* 2017;00: e12259. URL: <https://doi.org/10.1111/jicd.12259>
- Bahrololoomi Z, Musavi SA, Kabudan M. In vitro evaluation of the efficacy of laser fluorescence (DIAGNOdent) to detect demine-ralization and remineralization of smooth enamel lesions. *JCD* 2013; 16:362-366.
- Diniz M.B, Campos PH, Sanabe ME, Duarte DA et al. Effectiveness of fluorescence-based methods in monitoring progression of noncavitated caries-like lesions on smooth surfaces. *Oper Dent* 2015; 40:230-241.
- Van der Veen MH, de Josselin de Jong E. Application of quantitative light-induced fluorescence for assessing early caries lesions. *Monogr Oral Sci* 2000; 17:144-162.
- Moriyama CM, Rodrigues JA, Lussi A, Diniz MB. Effectiveness of fluorescence-based methods to detect in situ demine-ralization and remineralization on smooth surfaces. *Caries Res* 2014;48:507-514.
- William V, Messer LB, Burrow MF. Molar incisor hypomi-neralization: review and recommendations for clinical management. *Pediatr Dent* 2006;28:224-232.
- Raphael S, Blinkhorn A. Is there a place for Tooth Mousse® in the prevention and treatment of early dental caries? A systematic review *BMC Oral Health* 2015;15:1-13.
- Al-Suleiman M, Silikas N, Watts D Effects of procedures of remineralization around orthodontics bracket bonded by self-etching primer on its shear bond strength *J Orthod Sci* 2012; 1: 63-68.
- Uysal T, Amasyali M, Koyuturk AE, OzcanS. Effects of different topical agents on enamel demine-ralization around orthodontic brackets: an in vivo and in vitro study. *Aust Dent J* 2010 55: 268-274.
- Reynolds EC. Dental mineralization US 8673363 B2. URL: <https://www.google.ch/patents/US8673363>
- Kopperud S, Gravdahl Pedersen C, Espelid I. Treatment decisions on Molar-Incisor Hypomine-ralization (MIH) by Norwegian dentists– a questionnaire study *BMC Oral Health* 2016; 17:3.
- Restrepo M, Jeremias F, Santos-Pinto L, Cordeiro R, Zuanon A. Effect of Fluoride Varnish on Enamel Remine-ralization in Anterior Teeth with Molar Incisor Hypomi-neralization *J Clin Pediatr Dent* 2016; 40: 207-210.