ISSN 1852-4834 on line version
versión electrónica

ACTA ODONTOLOGICA LATINOAMERICANA

Vol. 34 Nº 2 2021

aol

Colgate® PerioGard®

Recomiende nuestra mejor tecnología contra la gingivitis, el sangrado gingival y el cálculo dental

Reduce las bacterias que causan la gingivitis y otras enfermedades periodontales[1]

Ayuda a reducir **el sangrado gingival**[2]

Actúa sobre la causa del problema, no solo en los síntomas[3]. Actúa contra la: **recolonización de las bacterias**

Referencias: (1) de Albuquerque RF Jr., Head TW, Mian H, Muller K, Sanches K. Ito IY. Reduction of salivary S. Aureus and mutans group streptococci by a preprocedural chlorexidine rinse and maximal inhibitiry dilutions of chlorexidine and cetylpyridinium, Quitessence Int. 2004 Sept; 35 (8): 635-40. (2) Willians C, Mostler K, Simone AJ, Crawford R, Patel S, Petrone Me, Chakins P. Devizio W, volpe AR, Proskin HM. Efficacy of a dentrifice containing zinc citrate for the control of plaque and gengivitis: A 6-month clinical study in adults. Compendium. 19 (Suppl):4-15. (3) Antibacterial effects of a 2% zinc citrate toothpaste versus a regular toothpaste with fluoride alone on the supragengival plaque bacteria after múltiple use. Data on Flie; Colgate Palmolive Company Study design: 6 months, double blind clinucal study in harmony with ADA guidelines with 99 subjects completed the study.

Publisher
Producción Gráfica: Panorama gráfica & diseño
e-mail: panoramagyd@gmail.com

Acta Odontológica Latinoamericana is the official publication of the Argentine Division of the International Association for Dental Research.

Revista de edición argentina inscripta en el Registro Nacional de la Propiedad Intelectual bajo el N° 284335.

POLÍTICA EDITORIAL

El objetivo de **Acta Odontológica Latinoamericana** (AOL) es ofrecer a la comunidad científica un medio adecuado para la difusión internacional de los trabajos de investigación, realizados preferentemente en Latinoamérica, dentro del campo odontológico y áreas estrechamente relacionadas. Publicará trabajos originales de investigación básica, clínica y epidemiológica, tanto del campo biológico como del área de materiales dentales y técnicas especiales. La publicación de trabajos clínicos será considerada siempre que tengan contenido original y no sean meras presentaciones de casos o series. En principio, no se aceptarán trabajos de revisión bibliográfica, si bien los editores podrán solicitar revisiones de temas de particular interés. Las comunicaciones breves, dentro del área de interés de AOL, serán consideradas para su publicación. Solamente se aceptarán trabajos no publicados anteriormente, los cuales no podrán ser luego publicados en otro medio sin expreso consentimiento de los editores.

Dos revisores, seleccionados por la mesa editorial dentro de especialistas en cada tema, harán el estudio crítico de los manuscritos presentados, a fin de lograr el mejor nivel posible del contenido científico de la revista.

Para facilitar la difusión internacional, se publicarán los trabajos escritos en inglés, con un resumen en castellano o portugués. La revista publicará, dentro de las limitaciones presupuestarias, toda información considerada de interés que se le haga llegar relativa a actividades conexas a la investigación odontológica del área latinoamericana.

EDITORIAL POLICY

Although **Acta Odontológica Latinoamericana (**AOL) will accept original papers from around the world, the principal aim of this journal is to be an instrument of communication for and among Latin American investigators in the field of dental research and closely related areas.

AOL will be devoted to original articles dealing with basic, clinic and epidemiological research in biological areas or those connected with dental materials and/or special techniques.

Clinical papers will be published as long as their content is original and not restricted to the presentation of single cases or series.

Bibliographic reviews on subjects of special interest will only be published by special request of the journal.

Short communications which fall within the scope of the journal may also be submitted. Submission of a paper to the journal will be taken to imply that it presents original unpublished work, not under consideration for publication elsewhere.

By submitting a manuscript the authors agree that the copyright for their article is transferred to the publisher if and when the article is accepted for publication. To achieve the highest possible standard in scientific content, all articles will be refereed by two specialists appointed by the Editorial Board. To favour international diffusion of the journal, articles will be published in English with an abstract in Spanish or Portuguese.

The journal will publish, within budget limitations, any data of interest in fields connected with basic or clinical odontological research in the Latin America area.

Acta Odontológica Latinoamericana: an international journal of applied and basic dental research. – Vol. 1, no. 1 (1984) -
Buenos Aires

Cuatrimestral, 1984-1986; irregular, 1987-1993, semestral, 1996-2008, cuatrimestral, 2009-
Artículos en inglés, sumarios en inglés y castellano o portugués.
Variante de título: AOL.
Título clave abreviado: Acta Odontol. Latinoam.
Directores: Rómulo Luis Cabrini (1984-2015); María E. Itoiz (2015-2018); María E. Itoiz y Ricardo Macchi (2018-
Indizada en **MEDLINE/PubMed** : Vol. 1, nº 1 (1984) – ; **SciELO:** Vol 22 (2009)-
Se encuentra incorporada a **Latindex** (categoría 1, directorio y catálogo), y **Núcleo Básico de Revistas Científicas Argentinas** (2007-)por Resolución nº 1071/07 CONICET
Registrada en: *The Serials Directory, Ulrich's Periodicals Directory* y *SCImago Journal.*
Dirección electrónica: http://www.actaodontologicalat.com/
ISSN 1852-4834 versión electrónica

Este número se terminó de editar el mes de Agosto de 2021

CONTENTS / *ÍNDICE*

Acta Odontológica Latinoamericana
A partir del Volumen 27 (2014) AOL se edita en formato digital con el *Sistema de Gestión de Revistas Electrónicas* (Open Journal System, OJS). La revista es de acceso abierto (Open Access). Esta nueva modalidad no implica un aumento en los costos de publicación para los autores.

Comité Editorial

Acta Odontológica Latinoamericana
From volume 27 (2014) AOL is published in digital format with the *Open Journal System* (OJS). The journal is Open Access. This new modality does not imply an increase in the publication fees.

Editorial Board

Contact us / Contactos: Cátedra de Anatomía Patológica, Facultad de Odontología, Universidad de Buenos Aires.
M.T. de Alvear 2142 (C1122AAH) Buenos Aires, Argentina.
http://www.actaodontologicalat.com/contacto.html
actaodontologicalat@gmail.com

Hexavalent chromium exposure alters bone remodeling in the developing tooth alveolus and delays tooth eruption

Luciana M. Sánchez, Ángela M. Ubios

Universidad de Buenos Aires, Facultad de Odontología, Cátedra de Histología y Embriología, Buenos Aires, Argentina

ABSTRACT

Although it has been demonstrated that exposure of lactating rats to CrVI delays tooth eruption, the effects of CrVI exposure on bone remodeling in the developing alveolus during tooth eruption remain unknown. Our purpose was to analyze the effect of CrVI in the alveolus of the first lower molar of rats. Thirty-two suckling Wistar rats were divided into two groups. The experimental group received 12.5 mg/kg body weight/day of potassium dichromate dissolved in saline solution by oral gavage as of day 4 of the experiment; the control group received an equal dose of saline solution. Each group was divided into two sub-sets and euthanized at the ages of 9 and 15 days, respectively. Histochemical and histomorphometric studies of the bone surfaces of the developing tooth alveolus were performed. The percentage of bone formation surfaces was lower in experimental animals than in age-matched controls. The percentage of bone resorption surfaces was significantly lower in 9-day-old experimental rats than in controls and significantly higher in 15-day-old experimental rats than in controls. Exposure to CrVI during lactation alters the sequence of bone resorption and formation in the walls of the developing alveolus, both of which are necessary for tooth eruption, thus causing a delay.

Received: March 2021; Accepted: June 2021.

Keywords: *CrVI - tooth eruption - bone remodeling - tooth socket - rat.*

La exposición a cromo hexavalente altera la remodelación ósea del alvéolo dental en desarrollo y retarda la erupción dentaria

RESUMEN

Si bien ya ha sido demostrado que la exposición a CrVI de ratas lactantes retrasa la erupción dentaria, aún se desconocen los efectos de la exposición a CrVI que se producen sobre la modelación y remodelación de las paredes del alvéolo en formación que ocurren en los diferentes estadios de la erupción dentaria. Por tal motivo, el propósito de este trabajo fue estudiar el efecto del CrVI sobre la formación y la reabsorción óseas del alvéolo del primer molar inferior en desarrollo en ratas, a los 9 y a los 15 días de edad, que corresponden a los estadios intraóseo y de penetración mucosa de la erupción dentaria, respectivamente. El grupo experimental recibió una dosis diaria de 12,5 mg/kg de peso corporal de dicromato de potasio disuelto en solución salina por sonda bucal a partir del 4° día; mientras que el grupo control, un volumen equivalente de solución salina. Cada grupo fue dividido en 2 subgrupos de acuerdo al tiempo experimental en el que se llevó a cabo la eutanasia: 9 y 15 días de edad. Se llevaron a cabo estudios histoquímicos e histomorfométricos de las superficies óseas de los alveólos dentarios en formación. Los datos fueron analizados estadísticamente utilizando la prueba t de Student; estableciéndose un valor de p<0,05 como estadísticamente significativo. El porcentaje de superficies en formación fue menor en los animales experimentales de 9 y de 15 días de edad que en los respectivos controles. El porcentaje de superficies en reabsorción en los animales experimentales de 9 días de edad fue significativamente menor y en los animales de 15 días de edad fue significativamente mayor con respecto a sus controles. La exposición al cromo hexavalente durante la lactancia altera la secuencia de la reabsorción y la formación ósea de las paredes del alvéolo en desarrollo necesarias para que la pieza dentaria erupcione, causando su retraso. Los hallazgos obtenidos muestran la importancia del control de sustancias tóxicas en el agua potable, ya que sus efectos pueden alterar la remodelación ósea y por ende, el crecimiento y el desarrollo de los individuos que fueron expuestos durante la infancia temprana.

Palabras clave: *CrVI - erupción dentaria - remodelación ósea - alvéolo dentario - rata.*

INTRODUCTION

The heavy metal hexavalent chromium (CrVI), which can be found in the soil, air and water in industrial areas in large cities around the world, is very dangerous to human health[1-3]. Hexavalent chromium has been found in inadequately treated wastes from petrochemical and leather industries that are discharged into rivers[4]. Exposure to CrVI can affect the population at large[5,6] and children in particular[7]. In lactating infants, exposure can occur through breast milk from contaminated mothers[8] or by ingesting infant formula prepared with contaminated water[9,10]. A child's behavior and life-style also influence exposure. Children crawl on the floor, put things in their mouths, and eat inappropriate things such as dirt or paint chips. It has been reported that materials containing CrVI (plastics, dyes and paints) used to manufacture toys can be another source of exposure[11].

Dental eruption involves the movement of a tooth from its site of development in the jaw bone to its functional position in the oral cavity. Andreasen et al.[12] divided this continuous process into five stages: preeruptive movements, intraosseous eruption, mucosal penetration, preocclusal eruption, and postocclusal eruption. Each stage involves interactions between the developing tooth and the surrounding periodontal tissues, and it is temporally and spatially controlled to coordinate the growth of the jaws and the position of other adjacent and antagonist teeth[13]. The most widely accepted theory at present explaining the tooth eruption process under normal physiological conditions involves the action of bone modeling and remodeling[14]. The mechanism of bone modeling involves formation and resorption processes of different and often opposite bone surfaces. Bone formation occurs at the base of the developing alveolus, facilitating tooth eruption, whereas bone resorption occurs at the lateral walls and especially the bone overlying the crown of the tooth[15]. Simultaneously, the developing alveolar bone begins to undergo a remodeling process[16]. Bone remodeling involves the coordinated and coupled action of osteoclasts and osteoblasts at specific sites on the bone surface with the final aim of replacing and renewing the bone matrix[17]. Pathological conditions, as is CrVI exposure, impair the tooth eruption process[18,19]. The effects of CrVI exposure on bone tissue in rats include alterations in bone formation[20] and resorption[21], and in bone growth[22,23]. Moreover, defects in skeletal development in children born in contaminated areas close to leather tanning processing plants have been reported[24].

Previous studies conducted by our research group have shown that tooth eruption is delayed in suckling rats exposed to hexavalent chromium[18,19].

Nevertheless, the effects of CrVI exposure on modeling and remodeling of the walls of the developing alveolus at the different stages of tooth eruption remain unknown. Therefore, the aim of the present work was to study the effects of CrVI on bone formation and resorption of the alveolus of the developing first lower molar of 9- and 15-day-old rats, which correspond to rats in the intraosseous and mucosa penetration stages of tooth eruption, respectively.

MATERIALS AND METHODS

Thirty-two suckling Wistar rats aged 4 days at the onset of the experiment were used. Experimental animals received daily 12.5 mg/kg of body weight of potassium dichromate (Biopack, Argentina) dissolved in saline solution by oral gavage until the day prior to euthanasia. Both the experimental and control groups were divided into two sub-sets of eight animals each according to age at euthanasia: 9 and 15 days, which correspond to the intraosseous and mucosa penetration stages of tooth eruption, respectively.

All the animals were housed throughout the experiment with their corresponding dam (8 pups/dam) in individual metal cages 30 cm high, 40 cm wide, 40 cm deep, with wood chip bedding. The animals were kept under controlled housing conditions: 7-hour light/dark cycles, 20 to 26ºC temperature, and 40 to 70% humidity. The dams were allowed free access to solid chow pellets and water *ad libitum*. The pups were returned to their cage with their dam after each procedure.

This study was approved by the Institutional Ethics Committee for the Care and Use of Laboratory Animals of the School of Dentistry of the University of Buenos Aires (Res. No. 27/03/2013-51), and all the experiments were conducted in keeping with The National Institutes of Health Guidelines for the Care and Use of Laboratory Animals (NIH publication 85-123 Rev. 2010).

Immediately after euthanasia, the mandibles were resected and fixed in 4% formaldehyde in PBS at 4°C for 48 hours, decalcified in 10% EDTA, and

embedded in paraffin. Buccolingually oriented sections were obtained at the level of the mesial root of the first lower molars under a stereoscopic microscope (Nikon, Japan). Serial sections were stained with routine H&E and alkaline phosphatase (ALP) and tartrate-resistant acid phosphatase (TRAP) histochemical techniques, used as markers of bone formation and bone resorption, respectively. Photomicrographs of the histologic sections were taken using a light field microscope (Axioskop 2; Carl Zeiss, Jena, Germany) and a digital camera (Nikon CoolPix 12 Mp). The images were used to perform the histomorphometric analysis of the developing alveolus using Image Pro® Plus software, version 5.1 (Media Cybernetics), following the stereological principles described by Weibel and Elias[25], and using the nomenclature employed by Parfitt et al.[26] and revised by Depster et al.[27].

Histomorphometric Analysis

Digital images of the TRAP-stained sections were used to assess the resorption activity of the inner wall of the forming socket. During tooth eruption, bone resorption occurs only in the most superficial third. Therefore, TRAP+ edges were measured at a length of 500 µm from the point closest to the tip of the crown in both the buccal and lingual directions (See Fig. 1 for orientation), and expressed as percentage. Digital images of ALP-stained sections were used to measure the percentage of ALP+ bone formation in the total bone edge of the developing alveolus.

Data were analyzed statistically using Student's t test, setting statistical significance at $p<0.05$.

RESULTS

The histologic features of the first molars in the intraosseous and mucosa penetration stages of both experimental and control animals are shown in Fig. 1.

At age 9 days, the tooth germs of both groups were covered with bone and oral mucosa. The distance between the tooth germs and the surface of the oral mucosa was greater in CrVI-exposed animals, which thus showed a decreased eruption rate. Thickness of developing dental tissues was less and the entire germ was smaller and less developed. The walls of the developing alveolus were thinner and showed lower bone density than in controls.

At 15 days of age, the first molars were in the mucosa penetration stage, in which the crown is only covered by the oral mucosa and the bone overlying the crown has resorbed completely so that the tooth can open its eruption pathway. The upper portion of the cortical plates of the alveolus was separated from the enamel organ remnant by primitive connective tissue. Periodontal ligament fibers were inserted in the cortical bone plate and in the developing tooth root. The first molars of animals exposed to CrVI, however, had erupted less and were less developed,

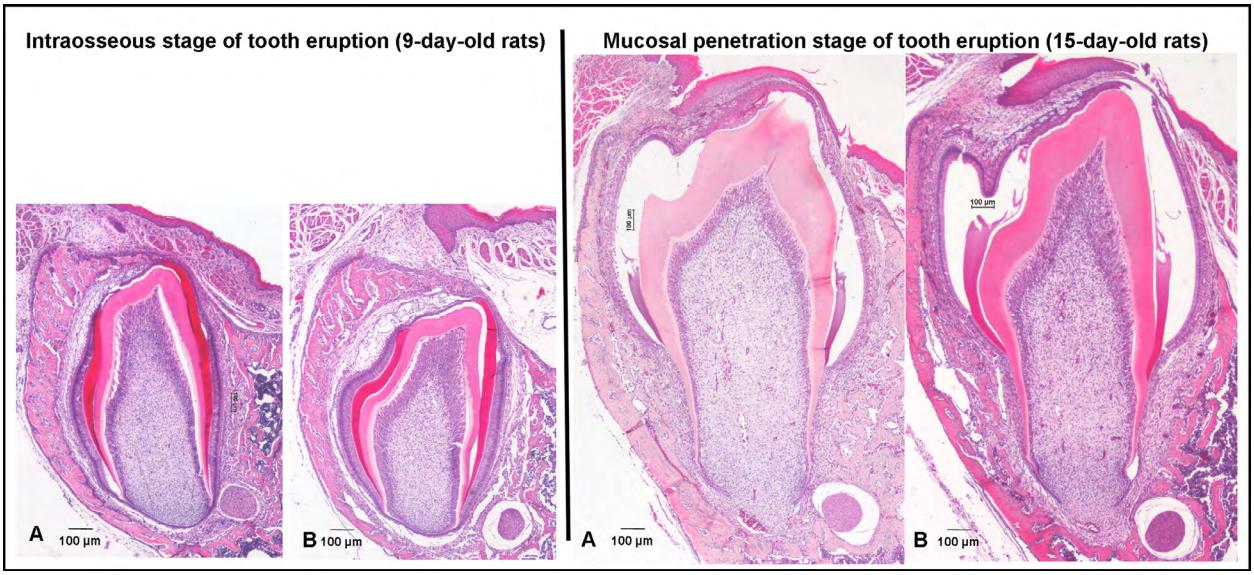

Fig.1: Buccolingual sections at the level of the mesial root of the first lower molar of 9- and 15-day-old animals. A. Control animals. B. CrVI-exposed animals. Nine-day-old exposed animals showed a less erupted tooth germ covered with thicker bone and less developed crown tissues than controls. Molars of 15-day-old exposed animals were less erupted with less developed crown tissues and less developed roots than control molars.

and the periodontal space around both the developing crown and root was smaller than in controls. The crown and roots were smaller, the Hertwig's sheath was longer, and the bone volume of the developing bony crypt was lower.

Nine-day-old experimental animals showed fewer erosion surfaces on the buccal and lingual sides of the developing alveolus than their age-matched controls. Conversely, 15-day-old experimental animals showed more erosion surfaces at the aforementioned sites than their matched controls (Fig. 2). In addition, the trabeculae of the walls of the developing alveolus of experimental animals were thicker and larger than those of controls at both stages of tooth eruption studied.

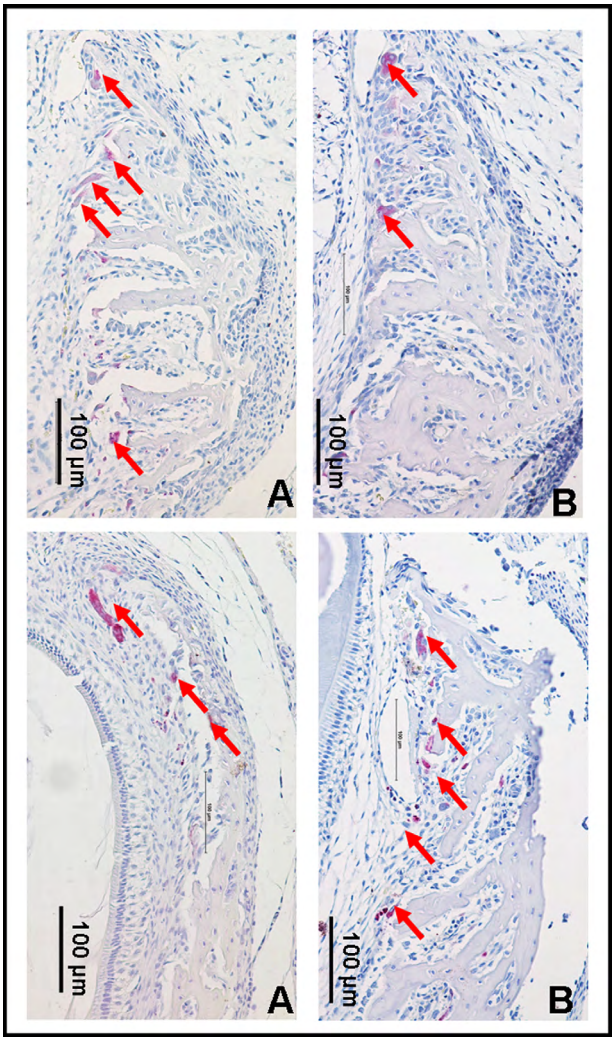

Fig 2: Buccolingual sections at the level of the mesial root of the first lower molar of 9- and 15-day-old rats. TRAP detection, hematoxylin counterstained. The upper and lower images correspond to 9- and 15-day-old animals, respectively. A. Control rat. B. CrVI-exposed rat. Nine-day-old CrVI animals showed fewer TRAP+ resorption surfaces (red arrows) than their age-matched controls. Conversely, 15-day-old CrVI animals showed more TRAP+ resorption surfaces (red arrows) than their matched controls. In addition, bone trabeculae of both 9- and 15-day-old CrVI animals were thicker and larger.

Table 1: Percentage of bone resorption surfaces in 9- and 15-day-old animals

	Control Group	Experimental Group
Buccal side		
Intraosseous stage/ age 9 days	50.81±2.68	36.98±3.21*
Mucosal penetration stage /age 15 days	39.05±3.01	60.91±9.7*
Lingual side		
Intraosseous stage/ age 9 days	69.66±5.81	29.58±5.81*
Mucosal penetration stage/age 15 days	39.58±6.32	62.95±8.34

Results are expressed as mean and standard deviation, *p<0.05.

Table 2: Percentage of bone formation surfaces in 9- and 15-day-old animals.

	Control Group	Experimental Group
Buccal side		
Intraosseous stage/ age 9 days	65.55±2.91	29.07±2.31*
Mucosal penetration/ age 15 days	51.34±3.91	43.07±11.22
Lingual side		
Intraosseous stage/ age 9 days	60.97±2.91	49.08±5.88*
Mucosal penetration/ age 15 days	30.71±2.89	45.64±8.52

Results are expressed as mean and standard deviation, *p<0.05

The histomorphometric study showed that the percentage of TRAP+ surfaces at the study sites was significantly lower in 9-day-old experimental animals and significantly higher in 15-day-old animals than in the corresponding sites in their age-matched controls (Table 1).

The buccal and the lingual sides of the developing alveolus of 9- and 15-day-old CrVI-exposed animals showed fewer osteoblast-covered bone surfaces than controls. The histomorphometric study showed that the percentage of ALP+ surfaces was lower in controls than in the corresponding sites of age-matched experimental rats. The differences observed between groups at the intraosseous stage of tooth eruption were statistically significant (Table 2).

DISCUSSION

To our knowledge, this is the first experimental study to analyze the effects of CrVI on tooth eruption. Our results showed that exposing suckling rats to CrVI delays resorption of the bone overlying the crown and bone formation on the lateral walls of the developing alveolus, delaying tooth eruption.

Bone resorption must take place for the tooth to move through the eruption pathway in all three spatial planes. Marks and Cahill[28] reported that the dental follicle plays an essential role in regulating this process. It has been shown that the dental follicle produces chemotactic molecules, such as MCP-1 (Monocyte chemotactic protein-1) and CSF-1 (Colony stimulating factor-1), responsible for recruiting mononuclear cells that fuse to form osteoclasts, which are necessary for the alveolar bone to resorb[29]. According to reports in the literature, osteoclastogenesis in the developing alveolus of the first molar of rats increases towards day three after birth and then decreases towards 10 – 16 age period [30,31].

Our results in the control group agree with these data. In the CrVI group, we found a significantly lower percentage of TRAP+ bone resorption surfaces in 9-day-old rats and a higher percentage of bone resorption surfaces in 15-day-old rats. This indicates alteration of the sequence of bone resorption in the walls of the developing alveolus that is necessary for the tooth to move through the eruption pathway. Exposure to CrVI is likely to affect the regulating function of the dental follicle, altering monocyte recruitment and fusion, consequently altering osteoclastogenesis and resorption of the developing alveolus, and causing a delay in the eruption.

Our observations are in agreement with studies reported in the literature. CrVI affects osteoclastogenesis and osteoclast function *in vivo* in rats[32] and in humans[33], since chromium interferes with monocyte differentiation into osteoclasts and inhibits the Ca^{2+} receptors in the osteoclast cell membrane. The binding site of the receptor is highly sensitive to divalent and trivalent cations, and because CrVI reduces to trivalent chromium, the latter could bind to the receptor, increasing the cytosolic concentration of calcium and decreasing bone resorption. In an *in vivo* study, Sankaramanivel et al.[20] showed a significant decrease in TRAP activity in the skull of exposed rats, which undergoes the same ossification mechanism as the jaws.

In addition, we found a lower percentage of ALP+ formation surfaces on the lateral walls of the developing alveolus of the first molar of CrVI-exposed animals as compared to controls at both experimental times. The lower degree of bone formation in the walls of the tooth alveolus observed in our study are in agreement with the effects of CrVI exposure on osteoblasts described by other authors. Reports on in vitro cytotoxic effects of CrVI on mature osteoblasts include alterations in their synthesis function, cell morphology, and capacity to differentiate into osteocytes and bone lining cells[34-36] as well as inhibition of bone mineralization[37].

An interesting finding of the present study is that CrVI-exposed animals exhibited thicker and larger bone trabeculae than their matched controls at both experimental times. There are no reports in the literature to date on intoxication with CrVI or other heavy metals showing this very particular alveolar histoarchitecture, which may occur as a consequence of an alteration of the bone remodeling process with the ensuing delay in alveolar bone resorption during tooth eruption.

Although the dose of 12.5 mg/kg of body weight used in our study is lower than the median lethal CrVI dose (LD50) for rats, it is higher than the maximum allowed dose (0.1 mg/kg) for humans[38]. Environmental levels of CrVI in some large cities around the world are higher than the dose used here[1-3]. In fact, the daily dose of CrVI administered to the experimental animals in this study was similar to the dose that growing children are exposed to through drinking formula prepared with contaminated water. By delaying tooth eruption, exposure to CrVI could cause impaired occlusion and facial growth and development in exposed children. All dentists should therefore be well informed about these CrVI exposure-related disorders for early detection and prompt referral to the corresponding specialist. In addition, having information about the environment in which their patients have grown up helps dentists to diagnose these alterations accurately.

ACKNOWLEDGMENTS
The authors thank Ht. Ivana Sánchez Rojas and Mariela Lacave for their technical assistance.

FUNDING
This study was supported by a grant from University of Buenos Aires, UBACyT program. Number 2014-2017 20020130100270.

CORRESPONDENCE
Dr. Luciana Marina Sánchez
Cátedra de Histología y Embriología, Facultad de Odontología, Universidad de Buenos Aires
Marcelo T. De Alvear 2142 1° "A". CP: 1122AAH.
Buenos Aires, Argentina.
luciana.sanchez@odontologia.uba.ar

References

1. Tziritis E, Kelepertis E, Korres G, Perivolaris D, Repani S. Hexavalent Chromium Contamination in Groundwaters of Thiva Basin, Central Greece. Bull Environ Contam Toxicol 2012, 89: 1073-1077.
2. Banu S, Stanley J, Taylor R, Sivakumar KK et al. Sexually Dimorphic Impact of Chromium Accumulation on Human Placental Oxidative Stress and Apoptosis. Toxicol Sci 2018;161: 375-387.
3. Stanislawska M, Janasik B, Kuras R, Malachowska B, Halatek T, Wasowicz W. Assessment of occupational exposure to stainless steel welding fumes - A human biomonitoring study. Toxicol Lett 2020;329:47-55.
4. Yang X, Duan J, Wang L, Li W, Guan J, Beecham S et al. Heavy metal pollution and health risk assessment in the Wei River in China. Environ Monit Assess. 2015,187:111.
5. Sun H, Brocato J, Costa M. Oral Chromium Exposure and Toxicity. Curr Environ Health Rep. 2015,2:295-303.
6. Kirman CR, Suh M, Proctor DM, Hays SM. Improved physiologically based pharmacokinetic model for oral exposures to chromium in mice, rats, and humans to address temporal variation and sensitive populations. Toxicol Sci 2017 15;325:9-17.
7. Izhar S, Goel A, Chakraborty A, Gupta T. Annual trends in occurrence of submicron particles in ambient air and health risk posed by particle bound metals. Chemosphere 2016;146:582-590.
8. Casey CE, Hambidge KM. Chromium in human milk from American mothers. Br J Nutr 1984, 52: 73-77.
9. Hernandez F, Bemrah N. Séby F, Noel L, Guérin T. Cr(VI) and Cr(III) in milk, dairy and cereal products and dietary exposure assessment. Food Addit Contam Part B Surveill 2019;12:209-215.
10. Kerger BD, Paustenbach DJ, Corbett GE, Finley BL. Absorption and elimination of trivalent and hexavalent chromium in humans following ingestion of a bolus dose in drinking water. Toxicol Appl Pharmacol. 1996;141:145-158.
11. Scientific Committee Health and Environmental Risks (SCHER). "Chromium VI in toys", 2015. https://ec.europa.eu/health/sites/health/files/scientific_committees/environmental_risks/docs/scher_o_167.pdf
12. Andreasen JO. Normal and disturbed tooth eruption in humans. In: Andreasen Jo, Petersen JK, Laskin DM, eds. Textbook and color atlas of tooth impactions. Diagnosis, treatment and prevention. Copenhagen: Munkksgaard, 1997; 19-47.
13. Wang XP. Tooth eruption without roots. J Dent Res. 2013, 92:212-214.
14. Marks SC Jr, Schroeder HE. Tooth eruption: theories and facts. Anat Rec. 1996, 245:374-393.
15. Merzel J, Salmon CR. Growth and the modeling/remodeling of the alveolar bone of the rat incisor. Anat Rec (Hoboken). 2008, 291:827-834.
16. Wise GE, King GJ. Mechanisms of tooth eruption and orthodontic tooth movement. J Dent Res 2008, 87:414-434.
17. Henriksen K, Neutzky-Wulff AV, Bonewald LF, Karsdal MA. Local communication on and within bone controls bone remodeling. Bone 2009, 44: 1026-1033.
18. De Lucca RC, Dutrey PL, Villarino ME, Ubios AM. Effect of different doses of hexavalent chromium on mandibular growth and tooth eruption in juvenile Wistar rats. Exp Toxicol Pathol 2009, 61:347-352.
19. Sánchez LM, Lewicki M, De Lucca RC, Ubios AM. Impairment of bony crypt development associated with hexavalent chromium exposure during tooth eruption. Acta Odontol Latinoam 2015, 28: 203-209.
20. Sankaramanivel S, Jeyapriya R, Hemalatha D, Djody S, Arunakaran J, Srinivasan N. Effect of chromium on vertebrae, femur and calvaria of adult male rats. Hum Exp Toxicol 2006, 25: 311-318.
21. Howie DW, Rogers SD, Mc Gee MA, Haynes DR. Biologic effects of cobalt chrome in cell and animal models. Clin Orthop Relat Res 1996, 329 Suppl: S217-32.
22. Bailey MM, Boohaker JG, Sawyer RD, Behling JE et al. Exposure of pregnant mice to chromium picolinate results in skeletal defects in their offspring. Birth Defects Res B Dev Toxicol 2006, 77: 244-249.
23. Soudani N, Ben Amara I, Troudi A, Bouaziz H, Boudawara T, Zeghal N. Oxidative stress induced by chromium (VI) in bone of suckling rats. Toxicol Ind Health. 2011, 27:724-734.
24. Blacksmith Institute (2007) Polluted Places- India. Final report January 2005- December 2007. Project implemented by Blacksmith Institute. Supported under Poverty and Environment Program (PEP), Asian Development Bank.
25. Weibel E, Elias H. Quantitative methods in morphology. In: Weibel ER, Elias H (eds). Introduction to stereology and morphology. 1967, Springer Verlag, Berlin, 3-19.
26. Parfitt AM. Bone histomorphometry: standardization of nomenclature, symbols and units (summary of proposed system). Bone 1987, 9:67-69.
27. Dempster DW, Compston JE, Drezner MK, Glorieux FH et al. Standardized Nomenclature, Symbols, and Units for Bone Histomorphometry: A 2012 Update of the Report of the ASBMR Histomorphometry Nomenclature Committee. J Bone Miner Res 2013, 28: 2–17.
28. Marks SC Jr, Cahill DR. Regional control by the dental follicle of alterations in alveolar bone metabolism during tooth eruption. J Oral Pathol. 1987, 16: 164–169.

29. Liu D, Wise GE. A DNA microarray analysis of chemokine and receptor genes in the rat dental follicle-rol of secreted frizzled- related protein- 1 in osteoclastogenesis. Bone 2007, 41: 266-272.
30. Wise GE. Cellular and molecular basis of tooth eruption. Orthod Craniofac Res 2009, 12: 67-73.
31. Wise GE, Fan W. Changes in the tartrate-resistant acid phosphatase cell population in dental follicles and bony crypts of rat molars during tooth eruption. J Dent Res. 1989,68: 150–156.
32. Nichols KG, Puleo DA. Effect of metal ions on the formation and function of osteoclastic cells in vitro. J Biomed Mater Res 1997, 35: 265-271.
33. Neale S, Haynes D, Howie D, Murray D, Athanasou N. The effect of particle phagocytosis and metallic wear particles on osteoclast formation and bone resorption In Vitro. J Arthroplasty 2000, 15: 654-662.
34. Lohmann CH, Schwartz Z, Köster G, Jahn U et al. Phagocytosis of wear debris by osteoblasts affects differentiation and local factor production in a manner dependent on particle composition. Biomaterials 2000, 21:551-561.
35. Anissian L, Stark A, Dahistrand H, Granberg B, Good V, Bucht E. Cobalt ions influence proliferation and function of human osteoblast-like cells. Acta Orthop Scand 2002, 73: 369-374.
36. Monteiro C, Santos C, Bastos V, Oliveira H. Cr(VI)-induced genotoxicity and cell cycle arrest in human osteoblast cell line MG-63. J Appl Toxicol 2019; 39:1057-1065.
37. Andrews RE, Shah KM, Wilinson JM, Gartland A. Effects of cobalt and chromium ions at clinically equivalent concentrations after metal-on-metal hip replacement on human osteoblast and osteoclasts: implications for skeletal health. Bone 2011, 49: 717- 723.
38. Toxicological profile for chromium. U.S. department of health and human services, Public Health Service Agency for Toxic Substances and Disease Registry, 2012. URL: https://www.atsdr.cdc.gov/toxprofiles/tp7.pdf

Cytotoxic and anti-inflammatory effects of chitosan and hemostatic gelatin in oral cell culture

Jessica J. Narvaez-Flores[1], Gabriela Vilar-Pineda[2], Laura S. Acosta-Torres[1], Rene Garcia-Contreras[1]

1. Universidad Nacional Autónoma de México, Escuela Nacional de Estudios Superiores Unidad León, Laboratorio de Investigación Interdisciplinaria, Área de Nanoestructuras y Biomateriales, León, Guanajuato, México
2. Universidad Nacional Autónoma de México, Escuela Nacional de Estudios Superiores Unidad León, Área de Cirugía Oral y Maxilofacial, León, Guanajuato, México

ABSTRACT
Chitosan is a biopolymer with bactericidal/bacteriostatic effect, biocompatible and biodegradable. It has been used in tissue engineering to replace tissues partially or completely by releasing bioactive materials or influencing cell growth, usually in regenerative medicine and dentistry. The aim of this study was to evaluate the cytotoxic and anti-inflammatory effect of chitosan alone or with hemostatic gelatin (Spongostand®) in cultures of human pulp cells (HPC), human gingival fibroblasts (HGF) and mouse pre-osteoblasts (MC3T3-E1, ATCC). HPC and HGF were isolated from patients. Cells were subcultured in DMEM. Chitosan was inoculated at different concentrations (0-0.5%) and hemostatic gelatins impregnated with chitosan (0.19%) were placed directly in the presence of cells and incubated for 24 hours. Cell viability was determined by MTT method and mean cytotoxic concentration (CC_{50}) was calculated from the dose-response curve. Anti-inflammatory effect was calculated from the in vitro gingivitis model induced with interleukin 1beta (IL-1β) in HGF and protein detection. The data were subjected to Shapiro-Wilk, Kruskal-Wallis and Mann-Whitney tests. Experiments were performed in triplicate of three independent assays. Cell viability of HPC, HGF and MC3T3-E1 in contact with chitosan decreased significantly ($p<0.05$). The HPC were the most sensitive (CC_{50}= 0.18%), followed by HGF (CC_{50}= 0.18%) and MC3T3-E1 (CC_{50}= 0.19%). The cytotoxicity of gelatins impregnated with chitosan decreased cell viability of HGF and HPC by 11% and 5%, respectively. The pro-inflammatory effect was reduced significantly in the gingivitis model. To conclude, chitosan induces moderate cytotoxic effects alone or with hemostatic gelatin at 0.19%, in dose-dependent manner, with anti-inflammatory effects on human gingival fibroblasts. The use of chitosan as a biomaterial can be an excellent choice for use in regenerative dentistry.
Received: March 2021; Accepted: July 2021.

Keywords: *chitosan - gingivitis - anti-inflammatory agents - prostaglandin-E synthases - regenerative medicine.*

Efectos citotóxicos y antiinflamatorios del quitosano y la gelatina hemostática en cultivo celular oral

RESUMEN
El quitosano es un biopolímero con efecto bactericida/bacteriostático, biocompatible y biodegradable. Se ha utilizado en ingeniería de tejidos con el fin de reemplazar parcial o completamente los tejidos como material bioactivo o influyendo en el crecimiento celular, comúnmente, para medicina y odontología regenerativa. Evaluar el efecto citotóxico y antiinflamatorio del quitosano solo o con gelatina hemostática (Spongostand®) en cultivos con células pulpares humanas (HPC), fibroblastos gingivales humanos (HGF) y preosteoblastos de ratón (MC3T3-E1, ATCC). HPC, HGF se aislaron de pacientes. Las células se subcultivaron en DMEM. Se inoculó quitosano a diferentes concentraciones (0-0,5%) y se colocaron gelatinas hemostáticas impregnadas con quitosano (0,19%) directamente en presencia de células y se incubaron durante 24 horas. La viabilidad celular se determinó mediante el método MTT y se calculó la concentración citotóxica media (CC_{50}) a partir de la curva dosis-respuesta. El efecto antiinflamatorio se calculó a partir del modelo de gingivitis in vitro inducido con interleucina 1β (IL-1β) en HGF. Los datos se sometieron a las pruebas de Shapiro-Wilk, Kruskal-Wallis y Mann-Whitney. Los experimentos se realizaron por triplicado de tres ensayos independientes. La viabilidad celular de HPC, HGF y MC3T3-E1 en contacto con el quitosano disminuyó significativamente la viabilidad celular ($p <0.05$). Las HPC fueron las más sensibles (CC_{50}= 0,18%) seguido de HGF (CC_{50}= 0,18%) y MC3T3-E1 (CC_{50}= 0,19%). Las gelatinas impregnadas con quitosano mostraron una disminución en la viabilidad celular para HGF, HPC de 11% y 5% respectivamente y se redujo significativamente el efecto pro-inflamatorio en el modelo de gingivitis humano. El quitosano induce efectos citotóxicos moderados solo o con gelatina hemostática a 0,19% de forma dosis-dependiente con efectos antiinflamatorios en fibroblastos gingivales humanos. El uso de quitosano como biomaterial puede ser una excelente opción para su uso en odontología regenerativa.
Palabras clave: *quitosano - gingivitis - agentes antiinflamatorios - prostaglandina-E sintasas - medicina regenerativa.*

INTRODUCTION

State-of-the-art science promotes constant experimentation with different materials that are biocompatible with the human body, because innovation in dental biomaterials is essential to improving the practice of medicine and regenerative dentistry[1-3]. Dental biomaterials are those materials used in regenerative[4], prosthetic and reconstructive dentistry with the goal of replacing missing tissue as closely as possible to the original. To be considered acceptable, a biomaterial must be biocompatible, have good adhesion, have natural appearance similar to that of the missing tissue, be bioinert, bacteriostatic, bactericidal, and importantly, not cause toxic damage to the cells surrounding the tissue to be treated[5,6]. Chitosan is a biopolymer with bactericidal/bacteriostatic effects, biodegradable and biocompatible[7], which has been used in tissue engineering to replace tissues partially or completely by releasing bioactive materials or influencing cell growth[7,8].

Tissue regeneration is the answer for comprehensive restitution of body tissue after injury, unlike repair, where the scar tissue is formed with different features from the original tissue[9]. Every year, over 500,000 grafting procedures are performed to restore functionality following injuries such as bone fractures, injuries resulting from a variety of surgical, degenerative disease and traumatic causes that can be disabling or even cause loss of stability[9,10]. Bone and other tissue grafts have been an essential tool for rehabilitation in oral mucosa and other body parts because of their inductive capacity to regenerate damaged tissue caused by trauma or surgical treatment. Tissue engineering creates artificial grafts that are able to induce new-formation and regeneration of soft and hard tissues through natural regeneration processes[11].

Hemostatic gelatin is a product obtained during the degradation of collagen triple helical structure into single molecules. For years, gelatin has received much attention as a hemostatic material due to its excellent properties such as low antigenicity, biocompatibility, biodegradability and relatively low cost. Gelatins are also widely used in the sustained release of drugs and tissue engineering applications with bone, cartilage and skin[12,13]. It has been reported that gelatin can activate platelet aggregation and it is also used as an absorbable hemostatic agent[14]. The mixture of gelatin and polymers increases its chemical stability, improves mechanical properties and bioactive properties such as biocompatibility and antimicrobial effects. Chitosan has good filming and viscosity, contains free amino groups and can cross-link with gelatin[15]. These characteristics of gelatin and chitosan enable them to form a natural semi-interpenetrating polymer network among molecules and acquire porous properties similar to biological scaffolds[15,16]. However, few studies have been performed on the combination of chitosan and gelatin[17].

Although some studies have been conducted on the cell cytotoxicity of chitosan[7,18], the current study includes three different types of cell cultures. The objective of this research was to determine the cytotoxic and anti-inflammatory effects of chitosan alone or with an impregnated hemostatic gelatin scaffold (Spongostand®) in culture on human gingival fibroblasts (HGF), human pulp cells (HPC) and mouse pre-osteoblasts (MC3T3-E1), through a series of experiments of dose-response curve and expression of prostaglandin E_2 (PGE_2) with MTT and ELISA assays[19,20]. All assays were conducted at the Interdisciplinary Research Laboratory; Nanostructures and Biomaterials Area of the National School of Higher Studies, Unit León UNAM.

MATERIAL AND METHODS

Cell culture

The protocol was reviewed by the institution's bioethics committee for the patients' cell isolates and accepted under number CE_16/004_SN. All patients gave their permission for their extracted teeth to be used in this research.

To obtain human pulp cells (HPC) and human gingival fibroblast (HGF), non-pathologically damaged erupted third molars and gingival tissue were collected from healthy patients who underwent surgical odontectomy of third molars. After extraction, the samples were stored in Falcon® tubes with 10 mL of phosphate buffer saline (PBS, pH 7.4) and 1% antibiotic (Gibco®, Grand Island, NY, EU). Each molar was cut at the cementoenamel junction with a carbide disc using a low-speed turbine under constant irrigation. The pulp and gingival tissue were obtained inside a laminar flow chamber (Lumistell®, Celaya Gto., Mexico) and explants of about 1x1 mm were performed with scalpel blade #20 in 60x15mm culture dishes (Thermo Fisher

Scientific, Rochester, NY, EUA). The explants were inoculated into sterile 100x15mm culture dishes (Thermo Fisher Scientific) with DMEM culture medium supplemented with 20% Fetal Bovine Serum (FBS, Gibco®), 1% antibiotic (10,000 UI/mL penicillin G and 10,000 µM/mL streptomycin sulfate, Gibco®), and 1% Glutamax (Gibco®). They were incubated at 37 ºC with 5% CO_2 and 95% humidity (Binder, Tuttlingen, Germany) for 3 weeks until a cellular confluence monolayer of 80% was obtained. The culture medium was replaced every third day after the first week. Mouse pre-osteoblast cells (MC3T3-E1, mouse C57BL/6 calvaria) were obtained from a certified strain (ATCC® CRL-2593) and sub-cultured in DMEM culture medium added with 10% FBS, 1% antibiotic and 1% Glutamax. Cells were sub-cultured in a range of $2x10^5$ cells/mL for each experiment.

Chitosan and gelatin preparation

Chitosan was prepared from shrimp shells 0.1gr/10mL (<75% deacetylation, Sigma Aldrich, Toluca, Mexico), mixed and stirred with 1% acetic acid. The mixture was left stirring on the heating and stirring grill at room temperature for 24 hours until it was homogenized and viscous-looking. The chitosan was prepared at 0.19% and the hemostatic gelatin (Spongostan®, Ethicon, Johnson-Johnson, Belgium) was impregnated.

Cell Viability

HPC, HGF and MC3T3-E1 were sub-cultured in DMEM medium at $2x10^5$ cells/mL in 96-well dishes and incubated for 48 h at 37ºC with 5% CO_2 and 95% humidity. Chitosan was inoculated at different concentrations in a range of 0-0.5% and incubated for 24 hrs. In case of hemostatic gelatin impregnated with 0.19% chitosan, the cells (HPC and HGF) were inoculated in a 24-well plate and the scaffolds were placed in direct contact for 24 hours. A control group of scaffolds was mixed with saline solution. Finally, the culture medium was removed and replaced by MTT reagent (0.2 mg/mL, thiazolyl Blue Tetrazolium Bromide, 98% Sigma Aldrich), incubated for 7 hours, and the crystals of formazan were dissolved with dimethyl sulfoxide [$(CH_3)_2SO$, DMSO, J.T Baker, USA]. The plate was analyzed in a microplate spectrophotometer (Thermo Scientific Multiskan GO) at 570 nm wavelength. The cells of the 24-well plate were transferred to 96-well plates to analyze mitochondrial metabolic activity. Each test was performed in triplicate for each of the three independent experiments.

Anti-inflammatory activity

HGF was sub-cultured as described above in 24-well plates. Interleukin-1β (recombinant human IL-1β, >97% Purity, R&D Systems, Minneapolis, MN, USA) reconstituted with albumin (Bovine Albumin Solution, 22%, IMMUCOR GAMMA, Norcross, GA, USA) was used to induce cells to a pro-inflammatory state (3 ng/mL) and use them as a positive control for 3 h[19, 20]. Then, the hemostatic gelatin scaffolds impregnated with chitosan at 0.19%, 1% and saline solution were inoculated in 24-well plates and incubated for a further 24 hours. The culture medium supernatant was stored in Eppendorf tubes, and prostaglandin E_2 (PGE_2) expression was analyzed with an expression kit (R&D Systems) with ELISA tests, following the manufacturer's instructions.

Statistical analysis and data expression

Means, standard deviations and percentages were calculated. The data were analyzed with Shapiro-Wilks normality test, paired Student t-test to compare incubation times of cell proliferation, and ANOVA *post hoc* Tukey test. Significance was set at 0.05 and reliability coefficient 95%.

RESULTS

All the data were adjusted to normal distribution. Fig. 1 summarizes the dose-response curve of the cytotoxic activity of chitosan from 0 to 0.5%. The viable cell number was reduced significantly. The results from most to least sensitive to contact with chitosan were HPC(CC_{50}=0.11±0.04%) <HGF(CC_{50}=0.19±0.02%) <MC3T3-E1(CC_{50}=0.19±0.03%).

The direct contact of hemostatic gelatin scaffolds impregnated with chitosan at 0.19% showed a cell viability as follows: HPC: Control (Saline solution)=94.98±1.55%, Chitosan 0.19%=89.14±0.57%; HGF: Control (Saline solution)=61.43±2.98%, Chitosan 0.19%=11.90±0.04%. The contact with HGF significantly reduced the viable cell number ($p<0.05$, Student-t test, n=9).

The individual cell viability tests were conducted using MTT on the HGF with hemostatic scaffolds (Fig. 2A) impregnated with chitosan or physiological solution for the control group, with and without

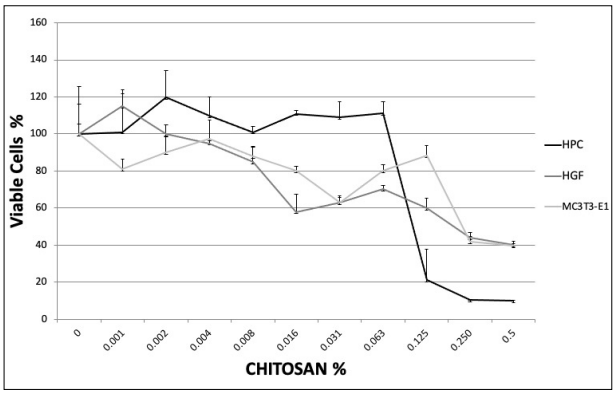

*Fig. 1: Cytotoxic activity of chitosan in culture with HGF, HPC, MC3T3-E1 for 24 hours of incubation. The relative viable cell number was determined by the 3-[4,5-dimethylthiazol-2yl]-2,5-diphenyltetrazolium bromide assay. Each value represents the mean±S.D. of triplicate assays, *p<0.05 paired Student-t test (Intragroup), ANOVA Tukey test (Intergroup), n=9.*

IL-1β. An increase in cell viability of 106.91% was observed in chitosan with IL-1β. Then, a test was performed with prostaglandin E_2 and ELISA analysis. The following results were observed with the tests used to measure the pro-inflammatory effects using Prostaglandin E_2 (PGE_2): the cells that were inflammed with IL-1β expressed a greater amount of PGE_2 alone and with physiological solution, while in contact with Chitosan 0.19% and 1%, PGE_2 expression was reduced significantly ($p<0.05$) (Fig. 2B).

DISCUSSION

Other studies prior to ours have shown that chitosan has healing and antimicrobial effects. A systemic study conducted in Madrid on its cytotoxicity established that the lethal dose in rats (LD50) was 16g/kg. The healing and bactericidal effect of chitosan has also been proven in studies conducted in Peru and Mexico[2,6,21].

There is a need for new regeneration techniques for the oral mucosa –different from the tissue grafts used currently– which would be suitable for use in humans and applicable in restorative dentistry and oral surgery. The natural biopolymer chitosan satisfies these needs. Mexico is one of the countries with the most coasts and production of crustaceans from which chitosan can be obtained[2], opening a broad panorama in terms of producing chitosan for regeneration techniques.

Our research team at the ENES Leon of the UNAM set itself the task of testing, standardizing and investigating the cytotoxic effects of chitosan in contact with human gingival fibroblasts (HGF), human pulp cells (HPC) and mouse osteoblasts (MC3T3.E1). HGF and HPC are common in the oral cavity. When they were placed in contact with chitosan –both in solution and in hemostatic sponges– *in vitro*, mean cytotoxicity concentration (CC_{50}) was found to be 0.19%. It has been shown that Schwann cells and endothelial cells enhance attachment, proliferation, and survival rates[22].

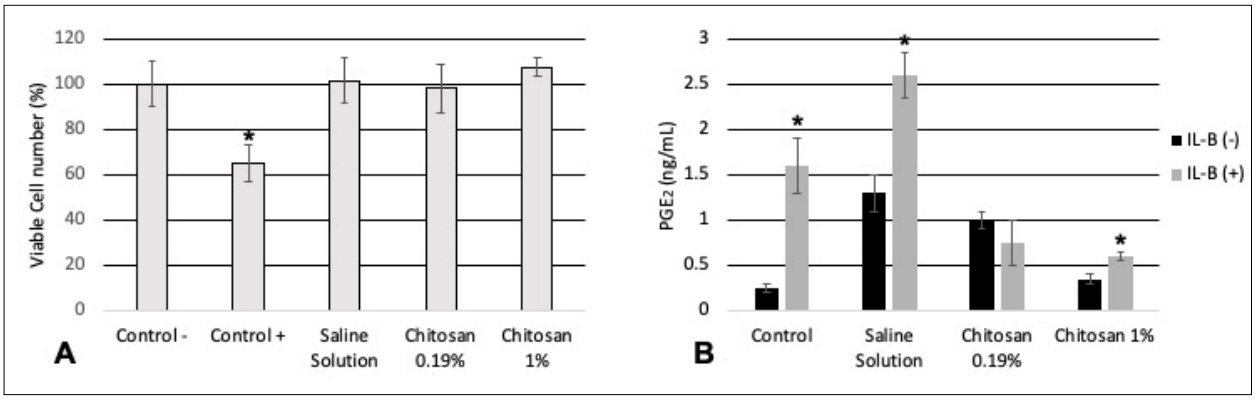

Fig. 2: Anti-inflammatory effect of hemostatic gelatin (Spongostand®) impregnated with chitosan by the synergistic stimulation of PGE_2 production with IL-1β. **A)** *Near confluent HGF cells were pre-treated to induce inflammation for 3 h with IL-1β (3 ng/mL) and incubated for a further 24 hours. The relative viable cell number was determined by the 3-[4,5-dimethylthiazol-2yl]-2,5-diphenyltetrazolium bromide assay.* **B)** *The concentration of PGE_2 in the culture medium was determined by ELISA, to induce cells to a pro-inflammatory state (3 ng/mL) and use it as a positive control for three hours. Each value represents the mean±S.D. by triplicate assays. *p<0.05, **p<0.01 paired t-test, n=9.*

With regard to anti-inflammatory effect, it has been shown that chondrocytes cultured in chitosan alginate beads reduce the expression of inflammatory cytokines (IL-6 and IL-8) and increase cartilage matrix component (hyaluronan and aggrecan) synthesis *in vitro*, in comparison to alginate beads alone[23]. Moreover, chitosan scaffolds have been found to inhibit the release of IL-1β and thus the formation of inflammasomes in mouse and human macrophages *in vitro*[24]. Here, we reported the potential anti-inflammatory effect by reducing the PGE_2 released form human gingival fibroblast previously induced to gingivitis.

As mentioned in our hypotheses, at chitosan concentrations greater than 0.19% in contact with human pulp cells (HPC), human gingival fibroblasts (HGF) and mouse osteoblasts (MC3T3-E1), chitosan produces cytotoxic effects; however, at concentrations <0.19%, cell viability is higher in these cell lines, where at the same time their natural biopolymer characteristics continue to be maintained, as well as their recently known anti-inflammatory effect. The current research studied properties of chitosan related to uses in medicine, and now dentistry. In the future, formulations could be based on the knowledge gained. Chitosan as a single biomaterial or in combination with other polymers could provide great improvements in tissue engineering and regenerative medicine, by providing a safe, affordable alternative for any type of condition, and helping to improve healing in situations such as oral surgery, periodontics, implantology, or any other requiring optimal, safe grafts. In the future, more studies will focus on the preparation of chitosan scaffolds via 3D printing and cryogelation methods to facilitate the application of chitosan in biomedicine. Chitosan, as a part of any material, could introduce valuable properties such as antimicrobial activity, mucoadhesion, and biocompatibility, which are required properties for a regenerative biomaterial.

Our results indicate that chitosan at concentrations above 0.19% can induce cell death or decrease cell viability when in direct contact with human pulp cells (HPC), human gingival fibroblasts (HGF) and MC3T3-E2. However, at concentrations lower than or equal to 0.19%, it induces cell viability and does not cause cytotoxicity, at the same time having a significant anti-inflammatory effect. Considering both the findings and the limitations, a new potential application of chitosan using a hemostatic gelatin scaffold for formulations in regenerative dentistry is proposed.

DECLARATION OF CONFLICTING INTERESTS

The authors declare no potential conflicts of interest regarding the research, authorship, and/or publication of this article

FUNDING

This work was supported by Grants from PAPIIT-UNAM-DGAPA: IA204516

CORRESPONDENCE

Dr. Rene Garcia-Contreras
Área de Nanoestructuras y Biomateriales
Escuela Nacional de Estudios Superiores, Unidad León
Universidad Nacional Autónoma de México
Boulevard UNAM No 2011, Predio el Saucillo y el Potrero, 36969
León, Guanajuato, México.
rgarciac@enes.unam.mx

REFERENCES

1. Agulló E, Mato R, Peniche C, Tapia C, et al. Quitina y Quitosano: obtención, caracterización y aplicaciones. Fondo editorial de la Pontificia Universidad Católica del Perú, Lima, Perú, Plenum Press, 2004.
2. Martinez-Sanchez. H, Escobedo A, Vazquez A. Elaboración de un gel biodegradable a base de quitosano con efecto cicatrizante. Virtualpro:Biopláticos 2013; 138:1-10.
3. Hirano H, Seino Y, Akiyama Y, Nonaka Y. Chitosan: a biocompatible material for oral and intravenous administration. In: Gebelein C.G., Dunn R.L. (eds) Progress in Biomedical Polymers, Springer, Boston, USA. 1990.
4. Ophof R, Van Reheden REM, Von den Hoff JW, Schalkwijk J, Kuiipers-Jagtman AM. Oral keratinocytes cultured on dermal matrices form a mucosa-like tissue. Biomaterials. 2002;23:3741-3748.
5. Ueda M, Ebata K, Kaneda T. In vitro fabrication of bioartificial mucosa for reconstruction of oral mucosa: Basic research and clinical application. Ann Plast Surg. 1991;27:540-549.
6. Harris R, Quitosano. Un biopolímero con aplicaciones en sistemas de liberación controlada de fármacos. Universidad Complutense de Madrid. Madrid, España 2009.
7. Aranaz I, Mengibar M, Harris R, Paños I, Miralles B, Acosta N, Galed G, Heras A. Functional characterization of chitin and chitosan. Current Chemical Biology. 2009;3:203-230.
8. Khan A, Wang B, Ni Y. Chitosan-nanocellulose composites

for regenerative medicine applications. Curr Med Chem. 2020;27:4584-4592.
9. Garner WL. Epidermal regulation of dermal fibroblast activity. Plast Reconst Sur. 1998;102:135-139.
10. Civitelli R, Beyer EC, Warlow PM, Robertson AJ, Geist ST, Steinberg TH. Conexin 43 mediates direct intercellular communication in human osteoblastic cells networks. J Clin Invest. 1993;91:1888-1896.
11. Sultankulov B, Berillo D, Sultankulova K, Tokay T, Saparov A. Progress in the development of chitosan-based biomaterials for tissue engineering and regenerative medicine. Biomolecules. 2019;9:470.
12. Dolci E, Gay EC, Arnabat DJ. La prevención de la Alveolitis seca. Rev Eur Odontol Estomatol. 1992;5:261-270.
13. Liu Y, Shu XS, Prestwich GD. Osteochondral defect repair with autologous bone marrow-derived mesenchymal stem cells in an injectable, in situ, cross-linked synthetic extracellular matrix**.** Tissue Eng. 2006;12:3405-3416.
14. Alizadeh A, Abbasi F, Khoshfetratc AB, Ghaleha H. Microstructure and characteristic properties of gelatin/chitosan scaffold prepared by a combined freeze-drying/leaching method. Mater Sci Eng C. 2013;33:3958-3967.
15. Wang T, Turhan M, Gunasekaran S. Selected properties of pH-sensitive, biodegradable chitosan–poly (vinyl alcohol) hydrogel. Polym Int. 2004;53:911-918.
16. Sarem M, Moztarzadeh F, Mozafari M. How can genipin assist gelatin/carbohydrate chitosan scaffolds to act as replacements of load-bearing soft tissues? Carbohydr Polym. 2013;93:635-643.
17. Lan G, Lu B, Wang T, Wang L, Chen J, Yu K, Liu J, Dai F, Wu D. Chitosan/gelatin composite sponge is an absorbable surgical hemostatic agent. Colloids Surfaces B: Biointerfaces. 2015;136:1026-1034.
18. Kunkel SL, Wiggins RC, Chensue SW, Larrick J. Regulation of macrophage tumor necrosis factor production by prostaglandin E2. Biochem Biophys Res Commun. 1986;137:404-410.
19. Garcia-Contreras R, Scougall-Vilchis RJ, Contreras-Bulnes R, Kanda Y, Nakajima H, Sakagami H. Induction of prostaglandin E_2 production by TiO_2 nanoparticles in human gingival fibroblast. In Vivo. 2014;28:217-22.
20. Garcia-Contreras R, Sugimoto M, Umemura N, Kaneko M, Hatakeyama Y, Soga T, Tomita M, Scougall-Vilchis RJ, Contreras-Bulnes R, Nakajima H, Sakagami H. Alteration of metabolomic profiles by titanium dioxide nanoparticles in human gingivitis model. Biomaterials. 2015;57:33-40.
21. Leon K, Santiago J. Propiedades antimicrobianas de películas de quitosano-alcohol polivinilico embebidas en extracto de sangre de grado. Rev Soc Quim Perú. 2005;71:185-192.
22. Li G, Han Q, Lu P, Zhang L, Zhang Y, Chen S, Zhang P, Zhang L, Cui W, Wang H, Zhang H. Construction of Dual-Biofunctionalized Chitosan/Collagen Scaffolds for Simultaneous Neovascularization and Nerve Regeneration. Research (Wash D C). 2020:2603048.
23. Oprenyeszk F, Sanchez C, Dubuc J-E, Maquet V, Henrist C, Compère P, Henrotin Y. Chitosan enriched three-dimensional matrix reduces inflammatory and catabolic mediators production by human chondrocytes. PLoS ONE. 2015; 10:e0128362
24. Vasconcelos DP, de Torre-Minguela C, Gomez AI, Águas AP, Barbosa MA, Pelegrín P, Barbosa JN. 3D chitosan scaffolds impair NLRP3 inflammasome response in macrophages. Acta Biomater. 2019;91:123-134

Prevalence and Distribution of Molar Incisor Hypomineralization in children receiving dental care in Caracas Metropolitan Area, Venezuela

Mónica Rodríguez-Rodríguez[1], William Carrasco-Colmenares[1], Aghareed Ghanim[2], Alfredo Natera[1], María Gabriela Acosta- Camargo[3]

1. Universidad Central de Venezuela, Facultad de Odontología, Caracas, Venezuela
2. University of Melbourne, Melbourne Dental School, Victoria, Australia
3. Universidad de Carabobo. Facultad de Odontología. Valencia, Venezuela

ABSTRACT

Great variation has been reported in worldwide prevalence of Molar Incisor Hypomineralization (MIH) and Hypomineralized Second Primary Molar (HSPM). South America has the highest regional prevalence. The aim of this study was to determine the prevalence and distribution of MIH HSPM in 6- to 12-year-old children who received care at two dental healthcare services (public and private) in Caracas Metropolitan Area, Venezuela. A cross-sectional prospective study was conducted on 145 children, of whom 121 were selected in the stratified random sample. A calibrated examiner (Kappa=0.878/0.831) evaluated all patients following the MIH diagnosis criteria established by the European Academy of Paediatric Dentistry and using a valid and reliable instrument. Data were analyzed with a significance level of 5%. Of the 121 children, 46.28% (56) were male and 53.72% (65) female, average age 8.83 ± 1.61. The prevalence of MIH/HSPM was 25.6%/20%. Both enamel defects were more prevalent in females (p-value=0.026/0.005). Severe MIH/HSPM was present in 21.8%/31.2% of cases. Average number of affected teeth was 4.16 ± 2.19/1.68 ± 0.74; and the condition was more frequent in upper molars (67.7%/51.4%). It was concluded that prevalence of MIH in 6- to 12-year-old Venezuelan children who received care in Caracas Metropolitan Area was higher than the previously estimated prevalence for South America, with predominance of mild affectation and more frequently occurring in upper molars.

Received: April 2021; Accepted July 2021.

Keywords: *molar - incisor - prevalence - dental - children.*

Prevalencia y distribución de Hipomineralización Incisivo-Molar en niños atendidos en el Área Metropolitana de Caracas, Venezuela

RESUMEN

Una gran variabilidad ha sido reportada en la prevalencia mundial de Hipomineralización Incisivo-Molar (HIM) y de Hipomineralización del segundo molar primario (HSMP). América del Sur presenta la prevalencia regional más alta. El objetivo de este estudio fue determinar la prevalencia y distribución de HIM y HSMP en niños entre 6 y 12 años atendidos en dos servicios de atención odontológica (público y privado) en el Área Metropolitana de Caracas, Venezuela. Se realizó un estudio prospectivo transversal en 145 niños. Se seleccionaron 121 niños en la muestra aleatoria estratificada. Un examinador calibrado (Kappa=0,878/0,831) evaluó a todos los pacientes siguiendo los criterios de diagnóstico de HIM establecidos por la Academia Europea de Odontología Pediátrica y utilizando un instrumento válido y confiable. Los datos se analizaron con un nivel de significancia del 5%. De los 121 niños, el 46,28% (56) eran varones y el 53,72% (65) mujeres con una edad media de 8,83 ± 1,61. La prevalencia de HIM/HSMP fue del 25,6%/20%. Ambos defectos del esmalte fueron más prevalentes en el grupo de niñas (valor de p-valor=0,026/0,005). La forma severa de HIM/HSMP estuvo presente en el 21,8%/31,2% de los casos. El promedio de número de dientes afectados por paciente fue de 4,16 ± 2,19/1,68 ± 0,74, siendo más frecuente en los molares superiores (67,7%/51,4%). Se concluyó que la prevalencia de HIM en niños venezolanos entre 6 y 12 años atendidos en el Área Metropolitana de Caracas fue superior a la prevalencia estimada previamente para Sudamérica, con predominio de afectación leve y más frecuente en molares superiores.

Palabras clave: *molar - incisivo - prevalencia - dental - niños.*

INTRODUCTION

Molar Incisor Hypomineralization (MIH) is defined as a qualitative enamel developmental defect, presumably multifactorial in origin, characterized by demarcated opacities in one to four first permanent molars (FPMs), with or without involvement of permanent incisors (PI). In weak and porous FPMs, enamel rapidly progresses to post-eruptive breakdown (PEB) and caries[1-3]. Reports have shown that second primary molars (SPMs), mineralized at a similar time as the FPMs, can also be affected, with the condition defined as Hypomineralized Second Primary Molar (HSPM)[4].

The global prevalence of MIH has been estimated as 11.24% to 14.2%, despite the wide variability in prevalence studies that highlighted the need for standardized procedures and clinical assessment in order to reduce the heterogeneity. South America has been identified as the most affected region, with an estimated prevalence of 18%[5,6]. A systematic review and meta-regression analysis estimated MIH prevalent cases and incident cases in countries with no database. In Venezuela, prevalent cases were estimated at 4,120,887 in 2015, and incident cases were estimated at 86,782 in 2016 [7]. In 2019, an MIH index was tested, providing confidence as a reliable and valid instrument for use in population-based studies, and it was recommended to determine MIH prevalence in epidemiological research [8].

Only three studies have reported demarcated opacities in Venezuelan children (local school population and renal disease group) using DDE and mDDE Index from 2010 to 2018 [9-11]. To our knowledge, no research has been conducted following standardized procedures and using EAPD criteria to determine MIH prevalence in Venezuela's pediatric population. The aim of this study was to determine the prevalence and distribution of MIH and HSPM in children who received dental care at two health services (one public and one private) in Caracas Metropolitan Area, Venezuela, and to compare the results with global epidemiological data.

MATERIALS AND METHODS

Study population

A cross-sectional prospective study was conducted on 6- to 12-year-old children who received care at the School of Dentistry at Universidad Central de Venezuela or at a private dental care center, from May 2019 to March 2020. The classification of health sectors was based on a previous report[12]. The study was designed according to the checklist described in a systematic review of MIH prevalence studies in order to ensure proper quality[5]. Sample size was calculated using the formula: sample size (n) = [Z2 × *P* (1-*P*)]/d2, where Z is the statistical level of confidence [95% confidence interval (CI) > Z = 1.96], and *P* is the expected prevalence and d the precision[13], assuming 18% for expected prevalence and 7.5% as precision level. Twenty percent was added to the minimum sample to account for possible negative responses. The calculated sample size was 121 patients. All positive respondents were included in the total sample (n). A stratified randomized sample (n_1) was calculated according to the size of each health sector group (positive respondents from the public and private sectors), using percentages and considering strong limitations in the previous randomized procedure, especially in the public sector. No official data is available about fluoride consumption level in salt or water.

The initial and final ethical approvals were secured from the Bioethics Committee, School of Dentistry, Universidad Central de Venezuela (CB-091-2019/ CB-133-2020). Parents or legal guardians signed informed consent before the clinical evaluation. Pursuant to national regulations, children also needed to assent to their participation in the study. Inclusion criteria were children seeking dental care (no general anesthesia or sedation required) with all first permanent molars fully erupted. Exclusion criteria were children using fixed orthodontic appliances, with special needs, disabilities, or contagious infectious diseases.

Clinical assessment

A valid and reliable instrument for MIH-index scoring was used for clinical evaluation[8,14] (Table 1). Index teeth were FPMs, PI and SPMs.

All patients were examined while seated in a dental chair by a calibrated examiner, using a dental light source and a flat mirror number 5. The examiner adhered to standard infection control protocol, using single vision lenses +2.5. Subjects were positioned to receive maximum illumination. Before examination, all teeth were cleaned and dried with gauze. The evaluation of index teeth was initiated in the right maxillary region (Quadrant 1), followed by the left maxillary index teeth (Quadrant 2), then the

Table 1. Codes and Clinical Status Criteria for MIH assessment[14]

Code	Clinical Status Criteria	
A	Not visible or less than 1/3 of the occlusal surface or of the crown length of incisor is visible.	
0	No visible enamel defect	
1	Enamel defect, not MIH/HSPM	11= diffuse opacities
		12=hypoplasia
		13=amelogenesis imperfecta
		14=hypomineralization defect (not MIH/HSPM)
2	21=Demarcated opacities white/creamy > 1 mm	
	22=Demarcated opacities yellow/brown > 1mm	
3	Post-eruptive enamel breakdown	
4	Atypical Restoration	
5	Atypical Caries Lesion	
6	Missing due to MIH	
7	Cannot be scored (extensive breakdown with cause impossible to determine)	

mandibular arch, beginning with the most posterior index tooth in the left quadrant (Quadrant 3), and finally moved around to the last index tooth in the right mandibular quadrant (Quadrant 4). A sequential code registration was carried out in a written form. Severity was classified as mild (Codes 21 and 22) or severe (Codes 3, 4, 5 and 6).

Calibration exercise

A pediatric dentist was calibrated in EAPD diagnosis criteria for the MIH index, using clinical photographs collected from patients who had previously been examined for the presence/absence of tooth developmental defects of enamel and following the MIH training manual for clinical field surveys and practice[14]. Three calibration sessions for clinical status were held. Intra-examiner reliability Kappa value was 0.878 and Inter-examiner reliability Kappa value was 0.831.

Statistical analyses

Data were collected and tabulated using Microsoft Excel 2010 (Microsoft Corp., Washington, USA) and analyzed using Statistical Package for Social Sciences version 20 for Windows (SPSS Inc., Chicago, IL, USA) software. The MIH group included cases with codes 2, 3, 4, 5 or 6 in at least one FPM. The NO-MIH group included cases without codes 2, 3, 4, 5 or 6 in at least one FPM. The prevalence of MIH/HSPM was calculated by frequencies, confidence interval (95%). Descriptive statistics were used to calculate frequency of affectation in index teeth. The chi-square test was used for association between MIH or HSPM and sex. The odds ratio (OR) was calculated to quantify the risk of presenting MIH according to presence of HSPM. The HSPM group included cases with codes 2, 3, 4, 5 or 6 in at least one SPM. The NO-HSPM group included cases without codes 2, 3, 4, 5 or 6 in at least one SPM. Adjusted SPM samples were made according to dental age (for total and randomized stratified sample), cases with no possible evaluation of all SPMs were excluded from the HSPM group. Cases in the MIH group with at least one affected SPM were included, although in some cases it was not possible to evaluate all SPMs. To calculate the number of MIH-affected teeth, affected SPMs were not considered, affected PIs were included. To calculate the number of HSPM-affected teeth, FPMs affected were not considered. The Mann Whitney U-test was used to evaluate the association between number of affected teeth and sex. Severity was calculated with respect to the total cases included in MIH and HSPM groups and to the total number of affected teeth in the MIH and HSPM groups, respectively. For this research, in case of a tooth with severe and mild presentation on different surfaces, the most severe form was considered and tabulated. Four dental groups were included in the analyses of the most affected tooth: FPM group (first permanent molars group), UPI group (upper permanent incisor group), LPI (lower permanent incisor group), SPM group (second primary molar group). Percentages were calculated with respect to the number of teeth evaluated in each group.

RESULTS

Sample distribution, MIH/HSPM prevalence and Odds Ratio.

One hundred and forty five 6- to 12-year-old children seeking dental care were invited and accepted to participate in this study. Three children were excluded according to selection criteria. The total sample (n=142) was distributed as follows: 80 children (56.33%) from a private center and 62 children (43.67%) from a public center. Of the total sample, 65 children (45.78%) were male and 77 (54.22%) female. Average age of the total sample was 8.85 ±1.63 years. A randomized stratified sample was calculated using SPSS® program according to health sector group size and the minimum sample size previously determined (n_1=121). Of the randomized stratified sample, 56 children (46.28%) were male and 65 (53.72%) female. Average age of the randomized stratified sample was 8.83 ± 1.61. MIH prevalence was 25.35% (n=36) (CI 95%= 18.11%-32.59%) for the total sample, and 25.62% (n=31) (CI 95%=17.73%-33.51%) for randomized stratified sample. Regarding health sector groups, 68 (56%) children were examined in the private sector and 53 (44%) children in the public sector for the randomized stratified sample. MIH prevalence was 30.88% in the private sector (n=21) (CI 95%= 19.62%-42.15%) and 18.87% in the public sector (n=10) (CI 95%= 7.98%-29.76%), Chi square p-value= 0.133 for randomized stratified sample.

One hundred and ten children were included in the SPM total sample: 47 (42.73%) were male and 63 (57.27%) female. Average of age was 8.38±1.44 for the SPM total sample, and 8.35±1.41 for the SPM randomized stratified sample. Ninety-four children were included in the SPM randomized stratified sample: 42 (44.68%) were male and 52 (55.32%) were female. HSPM prevalence was 18% (n=20) (CI 95%= 11%-26%) for the SPM total sample and 20% (n=19) (CI 95%= 12%-28%) for the SPM randomized stratified sample. The co-occurrence of MIH and HSPM was 25.80% (n=8) in the stratified randomized sample. The Odds Ratio used to calculate the risk of presenting MIH according to presence of HSPM was 2.86 (CI 95% = 1.04-7.87) for the SPM total sample and 2.48 (CI 95%= 0.86-7.15) for the SPM randomized stratified sample.

Distribution in the MIH group

The distribution of MIH prevalence according to sex was determined using the Chi square test with 5% significance level (Table 2). Severity was determined according to the total cases included in the MIH group and the total number of affected teeth in the MIH group (Table 3). Mild cases represented 78.2% of the cases in the stratified randomized sample and 77.5% in total sample. The number of affected teeth in each dental group for both MIH samples was calculated (Table 4). The upper left FPM, central right UPI and lateral right LPI were the most affected teeth. For the stratified randomized sample, average affected upper/lower teeth was 67.7%/58% for the FPM group. Average affected right/left teeth was 34.5%/27.6% for the UPI group and 26.4%/ 16% for the LPI group. Average affected teeth in the MIH group of the total sample was 4.19 ±2.17 and 4.16 ± 2.19 for stratified randomized sample. Girls had higher number of affected teeth than boys; U Mann Whitney p-value=0.947 for stratified randomized sample and p-value= 1.000 for total sample. Of the 31 children with MIH included

Table 2. Distribution according to sex in MIH and NO-MIH groups

Variable	MIH group F	MIH group %	NO-MIH group F	NO-MIH group %	X^2 p-value
Total sample (n=142)					
Male	11	7.7	54	36.6	0.034
Female	25	17.6	52	38	
Stratified randomized sample (n_1=121)					
Male	9	7.5	43	35.5	0.026
Female	22	18.2	47	38.8	

Table 3. Severity of MIH in samples for all cases and affected teeth

MIH Severity	For all cases MIH group Total sample	For affected teeth MIH group Total sample	For all cases MIH group Stratified randomized sample	For affected teeth MIH group Stratified randomized sample
Code 21: Opacities white/creamy > 1mm	83.3%	45.7%	80.6%	44.1%
Code 22: Opacities yellow/brown > 1mm	75%	31.8%	71.9%	34.1%
Code 3: Post-eruptive enamel breakdown	25%	10.6%	25.8%	10.9%
Code 4: Atypical Restoration	25%	7.3%	22.6%	6.2%
Code 5: Atypical Caries Lesion	11.1%	4.6%	9.67%	4.7%
Code 6: Missing due to MIH	0%	0%	0%	0%

Table 4. Distribution of MIH-affected teeth according to dental group and number of evaluated teeth

Dental Group	Tooth	Number of affected teeth Total sample n (%)	Number of evaluated teeth in group Total sample	Number of affected teeth Stratified randomized sample n (%)	Number of evaluated teeth in group Stratified randomized sample
FPM	16	23 (63.8%)	36	19 (61.2%)	31
	26	27 (75%)	36	23 (74.2%)	31
	36	25 (69.4%)	36	21 (67.7%)	31
	46	16 (44.4%)	36	15 (48.3%)	31
UPI	11	18 (54.5%)	33	17 (60.7%)	28
	12	5 (19.2%)	26	2 (8.6%)	23
	21	14 (42.4%)	33	12 (42.8%)	28
	22	6 (22.2%)	27	3 (12.5%)	24
LPI	31	3 (8.3%)	36	3 (9.6%)	31
	32	4 (11.4%)	35	4 (12.9%)	31
	41	5 (13.8%)	36	5 (17.2%)	29
	42	5 (15.6%)	32	5 (18.5%)	27

in stratified randomized sample, 5 (16.1%) patients also presented hypomineralization defect (Code 14), 3 (9.6%) patients showed diffuse opacities (Code 11) and only 1 patient (3.2%) presented both (Codes 11 and 14).

Distribution in the HSPM group

The distribution of HSPM prevalence according to sex was determined using Chi square test results with 5% significance (Table 5). Severity according to the total cases included in the HSPM group and to the total number of affected teeth in the HSPM group was determined (Table 6). Mild cases represented 69.8% of cases in the stratified randomized sample and 68.8% in the total sample. The number of affected teeth for both SPM samples was calculated. The upper right SPM was the most affected tooth (55.5%). For the HSPM randomized sample, average affected upper/lower teeth was 51.4%/45% for the HSPM group and 48.3%/42.4% for the HSPM total sample

Average affected teeth in the HSPM group of the SPM total sample was 1.65 ±0.74 and 1.68 ± 0.74 for the SPM randomized sample. Girls had a higher number of affected teeth than boys; U Mann Whitney test p-value=0.903 for stratified randomized sample and p-value=0.816 for the SPM total sample.

Table 5. Distribution according to sex in HSPM and NO-HSPM groups

Variable	HSPM total adjusted sample (n=110)				X^2
	HSPM		NO HSPM		
	F	%	F	%	p-value
Male	3	2.7	44	40	0.006
Female	17	15.5	46	41.8	
	HSPM randomized stratified adjusted sample (n=94)				
Male	3	3.2	39	41.5	0.005
Female	16	17	36	38.3	

Table 6. Severity of HSPM in samples for all cases and affected teeth.

HSPM Severity	For all cases HSPM group Total sample	For affected teeth HSPM group Total sample	For all cases MIH group Stratified randomized sample	For affected teeth MIH group Stratified randomized sample
Code 21: Opacities white/creamy > 1mm	60%	45.6%	57.84%	43.8%
Code 22: Opacities yellow/brown > 1mm	40%	24.2%	42.1%	25%
Code 3: Post-eruptive enamel breakdown	25%	15.1%	26.3%	15.6%
Code 4: Atypical Restoration	20%	15.1%	21%	15.6%
Code 5: Atypical Caries Lesion	0%	0%	0%	0%
Code 6: Missing due to MIH	0%	0%	0%	0%

DISCUSSION

A prevalence of MIH of 25.62% was determined in a random sample of 6- to 12-year-old children who received dental care in Caracas Metropolitan Area. The number reported here is higher than the estimated prevalence for South America (18%)[6]. It is very difficult to make comparisons of epidemiological interest between studies on MIH prevalence. Reports vary widely depending on population age, instrument, index used (DDE, mDDE, EAPD criteria), researcher calibration, evaluation technique and the setting, severity classification, research objectives and associated studies with other variables such as systemic conditions, etiological factors or dental caries.

Considering studies in which subjects were examined in a dental chair, MIH prevalence of 17.8% was found in a group of Spanish children using transillumination technique for dental surface evaluation[15]. A study conducted in private dental offices and university hospitals (specialized in pediatric dentistry) in eight regions of Japan reported a global prevalence of 19.8% [16]. In Latin America, a study conducted in a dental chair setting on Argentinean children determined MIH prevalence of 15.9% with significant differences according to health sector (private sector: 24.40% and public sector: 6.4%)[17]. Similar results were reported for Uruguayan children with MIH prevalence of 12.3% (private sector: 26.99% and public sector: 7.13%)[18]. These authors suggested that differences between health sectors could be attributed to local factors related to access to dental healthcare.

The prevalence reported in the current study is higher, but similar to previously reported prevalence for private sectors in Argentina and Uruguay. Also in this report, MIH prevalence in the private sector is higher than in public sector, but without significant difference. These findings suggest that comorbidities and complications associated to MIH lead parents to seek private services, considering that retreatments are often required, and the great demand for public services due to the economic crisis in Venezuela.

Clinical assessment conducted at schools may result in underestimation of positive cases because of limited viewing conditions, such as patient and operator position, or inappropriate light source. Some studies on Latin American schoolchildren have reported MIH prevalence of 40.4% in Mexico, 40.2%-18.4% in Brazil and 15.8% in Chile[19-22].

Also, 12.3% MIH prevalence was reported in schoolchildren in Brazil, but only opacities greater than 2 mm were recorded (outdoor setting) so there may have been underestimation[23]. Recently, Colombian schoolchildren were evaluated using portable dental equipment, with artificial light, and MIH prevalence was determined to be 11.2%[24]. This wide variability in results and assessment highlights the need for standardized procedures, considering that opacities greater than 1 mm should be recorded[14].

Regarding sex, significant difference in MIH prevalence has been found between Venezuelan girls and boys. Although systematic reviews had not determined this difference[6,7], prevalence studies from Jordan and Iran have reported similar results[25,26]. In the current report, girls are more affected than boys, but the number of affected teeth does not differ significantly according to sex.

Clearly, MIH is more frequent in first permanent molars than in permanent incisors, with reports of molar involvement of 68.5%-58.9% in Argentina and 59.58% in a multicenter study in Argentina and Uruguay[17,27]. Those numbers are similar to our findings with an average of 67.7% for upper FPM and 56.45% for lower FPM. Small but significant differences have been previously reported between percentages of maxillary and mandibular affected teeth in Argentina[28]. Fortunately, the defect is mildly expressed in most cases, and severely affected teeth have been determined with values of 14.8% enamel breakdown and 9.1% atypical restorations in Brazilian schoolchildren[23]; 15% in Colombia (including cases of opacities with loss of structure, atypical restorations, and/or exodontia due to hypomineralization)[24], and 21.8% of loss of enamel in affected teeth in Argentina[17]. Findings in the current study also suggest that MIH can be found simultaneously with demarcated opacities in premolars and canines, and/or diffuse opacities compatible with dental fluorosis. The co-occurrence of MIH and dental fluorosis has also been reported recently in schoolchildren in Brazil[29].

In this study, a 20% prevalence of HSPM was determined in a random and adjusted (to dental age) sample of 6- to 12-year-old children who received dental care in Caracas Metropolitan Area, with significant difference between sexes, girls being more affected than boys. The prevalence of HSPM is highly variable worldwide and has been reported between 2.7% and 21.8% [30]. The result found in the current study is within this range. The odds ratio determined in this study was 2.48, lower than previously reported between 4.6 and 4.4[4,31]. However, it is still relevant for pediatric dentists, so that they can provide current information to parents or guardians and promote adequate follow-up.

Finally, the current study was conducted in dental chair setting, and prevalence observed in this setting could be higher than prevalence in the general population. MIH produces associated comorbidities such as dental hypersensitivity, caries lesions, frequent loss of restorations, aesthetic complaint and affectation of self-esteem and self-image, which are frequent reasons for consultation. Thus, these results must be properly interpreted and used as a reference for similar dental healthcare services.

Limitations

A recent publication has emphasized that the Venezuelan economic crisis has shattered the healthcare system and basic public services, threatening health in the country[32]. Strong limitations were faced during this investigation related to conditions in public service and general living conditions. Also, by national legislation, informed consent must be signed by a legal guardian and two witnesses, after the proper information has been provided by the researcher. It was therefore not considered feasible to perform a study in a school setting. Furthermore, the COVID-19 pandemic forced us to stop collecting data, though fortunately, the minimum sample size had been reached by March 2020 and the number of positive respondents enabled random selection.

CONCLUSIONS

The prevalence of MIH in 6- to 12-year-old Venezuelan children who received dental care in Caracas Metropolitan Area was higher than global prevalence and previously estimated prevalence for South America, with a predominance of mild affectation, and more frequent in upper molars. These results have major similarities with reports from Argentina, Uruguay and Brazil, and emphasize the significant number of children affected in Latin America.

ACKNOWLEDGMENTS
The authors are grateful to those professors of Department of Orthodontic and Pediatric Dentistry who supported the research, and to parents and patients of the School of Dentistry of Central University of Venezuela who kindly agreed to participate in this study.

DECLARATION OF CONFLICTING INTERESTS
The authors declare no potential conflicts of interest regarding the research, authorship, and/or publication of this article

FUNDING
None

CORRESPONDENCE
MSc. Mónica Rodríguez Rodríguez
Av. Circunvalación del Sol. Centro Profesional Santa Paula
Santa Paula, Caracas. ZIP 1061
mrodriguezUCV.20@gmail.com

REFERENCES

1. Weerheijm KL, Jälevik B, Alaluusua S. Molar-Incisor Hypomineralisation. Caries Res 2001;35:390-391.
2. Silva MJ, Scurrah KJ, Craig JM, Manton DJ, Kilpatrick N. Etiology of molar incisor hypomineralization - A systematic review. Community Dent Oral Epidemiol 2016;44:342-353.
3. Garg N, Jain AK, Saha S, Singh J. Essentiality of Early Diagnosis of Molar Incisor Hypomineralization in Children and Review of its Clinical Presentation, Etiology and Management. Int J Clin Pediatr Dent 2012;5:190-196.
4. Elfrink MEC, ten Cate JM, Jaddoe VWV, Hoffman A, Moll A, Veerkamp JSJ. Deciduous Molar Hypomineralization and Molar Incisor Hypomineralization. J Dent Res 2012;91:551-565.
5. Pentapati KC, Yeturu SK, Siddiq H. Systematic review and meta-analysis of the prevalence of molar-incisor hypomineralization. J Int Oral Health 2017;9:243-250.
6. Zhao D, Dong B, Yu D, Ren Q, Sun Y. The prevalence of molar incisor hypomineralization: evidence from 70 studies. Int J Paediatr Dent 2018;28:170-179.
7. Schwendicke F, Elhennawy K, Reda S, Bekes K, Manton DJ, Krois J. Global burden of molar incisor hypomineralization. J Dent 2018;68:10-18.
8. Ghanim A, Mariño R, Manton D. Validity and reproducibility testing of the Molar Incisor Hypomineralisation (MIH) Index. Int J Paediatr Dent 2019;29:6-13.
9. Medina Y, Agreda M, Simancas Y, Salas ME. Prevalencia de Fluorosis Dental, Opacidades e Hipoplasia del esmalte en niños en edad escolar. Acta Odontol Venez 2010;48:1-10. URL: https://www.actaodontologica.com/ediciones/2010/3/art-11/
10. Agreda M, Simancas Y, Salas ME. Prevalencia de Fluorosis dental y anomalías de desarrollo del esmalte en los niños de la Escuela Bolivariana "Juan Ruiz Fajardo" del Estado Mérida, Venezuela. Acta Odontol Venez 2012;50:10. URL: https://www.actaodontologica.com/ediciones/2012/4/art-12/
11. Acosta MG, Oliveros J, Coronel V, Tamy-Maury I. Association between oral finding and renal disease among pediatric patients in Venezuela. Rev ADM 2018;75:71-79. URL: https://www.medigraphic.com/cgi-bin/new/resumenI.cgi?IDARTICULO=79059
12. Bonvecchio A, Becerril-Montekio V, Carriedo-Lutzenkirchen Á, Landaeta-Jiménez MC. Sistema de salud de Venezuela. Salud Pública de México 2011;53:S275-S286. URL: https://www.scielosp.org/article/ssm/content/raw/?resource_ssm_path=/media/assets/spm/v53s2/22.pdf
13. Elfrink MEC, Ghanim A, Manton DJ, Weerheijm KL. Standardised studies on Molar Incisor Hypomineralisation (MIH) and Hypomineralised Second Primary Molars (HSPM): a need. Eur Arch Paediatr Dent 2015;16:247-255.
14. Ghanim A, Silva MJ, Elfrink MEC, Lygidakis NA, Mariño RJ, Weerheijm KL, Manton DJ. Molar incisor hypomineralisation (MIH) training manual for clinical field surveys and practice. Eur Arch Paediatr Dent 2017;18: 225-242.
15. Martinez Gomez TP, Guinot JimenoF, Bellet Dalmau LJ, Giner Tarrida L. Prevalence of molar-incisor hypomineralisation observed using transillumination in a group of children from Barcelona (Spain). Int J Paediatr Dent 2012;22:100–109.
16. Saitoh M, Nakamura Y, Hanasaki M, Saitoh I, Murai Y, Kurashige Y, Fukumoto S, Asaka Y et al. Prevalence of molar incisor hypomineralization and regional differences throughout Japan. Environ Health Prev Med 2018;23:55-61.
17. Biondi AM, Cortese SG, Martínez K, Ortolani AM, Sebelli PM, Ienco M, Paván VH, Mendel N et al. Prevalence of molar incisor hypomineralization in the city of Buenos Aires. Acta Odontol Latinoam 2011;24:81-85. URL: http://www.scielo.org.ar/pdf/aol/v24n1/v24n1a13.pdf
18. López-Jordi M, Cortese SG, Álvarez L, Salveraglio I, Ortolani AM, Biondi AM. Comparison of the prevalence of molar incisor hypomineralization among children with different health care coverage in the cities of Buenos Aires (Argentina) and Montevideo (Uruguay) Salud Colect 2014;10:243-251. doi: 10.1590/S1851-82652014000200008
19. Villanueva Gutiérrez T, Barrera Ortega CC, Pérez Pérez N, García Pérez A. Impact of Molar Incisor Hypomineralization on Oral Health-Related Quality of Life in Mexican Schoolchildren. J Clinic Pediatr Dent 2019;43:324-330.
20. Soviero V, Haubek D, Trindade C, Da Matta T, Poulsen S. Prevalence and distribution of demarcated opacities and their sequelae in permanent 1st molars and incisors in 7 to 13-year-old Brazilian children. Acta Odontol Scan 2009;67:170-175.
21. Moura de Lima MD, Barroso Andrade MJ, Dantas-Neta NB, Andrade NS, Barbosa Teixeira RJ, Silva de Moura M, de Deus Moura Lde F. Epidemiologic Study of Molar-incisor Hypomineralization in Schoolchildren in North-eastern Brazil. Pediatr Dent 2015; 37:513-519.

22. Gambetta-Tessini K, Mariño R, Ghanim A, Calache H, Manton DJ. The impact of MIH/HSPM on the carious lesion severity of schoolchildren from Talca, Chile. Eur Arch Paediatr Dent 2019;20:417-423.
23. Jeremias F, Feltrini de Souza J, da Costa Silva CM, Loiola Cordeiro R C, Cilense Zuanon AC, Santos-Pinto L. Dental caries experience and molar incisor hypomineralization. Acta Odontol Scand 2013;71:870–876.
24. Mejía JD, Restrepo M, González S, Álvarez LG, Santos-Pinto L, Escobar A. Molar Incisor Hypomineralization in Colombia: Prevalence, Severity And Associated Risk Factors. J Clinic Pediatr Dent 2019;43:185-189.
25. Zawaideh FI, Al-Jundi SH, Al-Jaljoli MH. Molar incisor hypomineralisation: prevalence in Jordanian children and clinical characteristics. Eur Arch Paediatr Dent 2011;12:31-36.
26. Ghanim A, Bagheri R, Golkari A, Manton D. Molar-incisor hypomineralisation: a prevalence study amongst primary schoolchildren of Shiraz, Iran. Eur Arch Paediatr Dent 2014;15:75-82.
27. Biondi AM, López.Jordi M, Cortese SG, Alvarez L, Salveraglio I, Ortolani AM. Prevalence of molar-incisor hypomineralization (MIH) in children seeking dental care at the Schools of Dentistry of the University of Buenos Aires (Argentina) and University of la Republica (Uruguay). Acta Odontol Latinoam 2012;25:224-230. URL: http://actaodontologicalat.com/wp-content/uploads/2017/07/12.pdf
28. Biondi AM, Córtese SG, Babino L, Toscano MA. Molar incisor hypomineralization: Analysis of asymmetry of lesions. Acta Odontol Latinoam 2019;32:44-48. URL: http://www.scielo.org.ar/pdf/aol/v32n1/v32n1a07.pdf
29. Cartaxo Fernandes I, Soares Forte FD, Correia Sampaio F. Molar-incisor hypomineralization (MIH), dental fluorosis, and caries in rural areas with different fluoride levels in the drinking water. Int J Paediatr Dent 2020;31:475-482.
30. Owen ML, Ghanim A, Elsby D, Manton DJ. Hypomineralized second primary molars: prevalence, defect characteristics and relationship with dental caries in Melbourne preschool children. Aust Dent J 2018;63:72-80.
31. Garot E, Denis A, Delbos Y, Manton D, Silva M, Rouas P. Are hypomineralised lesions on second primary molars (HSPM) a predictive sign of molar incisor hypomineralisation (MIH)? A systematic review and a meta-analysis. J Dent 2018;72:8-13.
32. Page KR, Doocy S, Reyna Ganteaume F, Castro JS, Spiegel P, Beyrer C. Venezuela's public health crisis: a regional emergency. Lancet 2019;393:1254-1260.

Central incisors shape and proportions prevalence in Argentinian university students: by visual assessment and a new standardized method

María M. Trigo-Humaran[1], Alan B. Agüero-Romero[1], Marcela Lespade[1], Juan M. García-Cuerva[1], María E. Iglesias[2]

1. Universidad de Buenos Aires, Facultad de Odontología, Cátedra de Odontología Restauradora, Buenos Aires, Argentina
2. Universidad de Buenos Aires, Facultad de Odontología, Cátedra de Materiales Dentales, Buenos Aires, Argentina

ABSTRACT

The aim of this study was to analyze the dimensions of the clinical crown of upper central incisors and the prevalence of tooth shapes by two different protocols. Assessment was performed on each of the 111 dental stone type V maxillae models of students of dentistry from Buenos Aires University [93 females and 18 males, mean age 23.70 (± 2.26) years] The mesial and distal-vestibular angles were defined on each right upper incisor, and the following segments were defined: AB (zenith - incisal edge), CD, EF, GH (apical, middle, and incisal thirds - vestibule - mesial and vestibule-distal angles) and their lengths were determined with a precision caliper. Then, the CD/AB, EF/AB and mean CD-EF/AB ratios were calculated. Shapes were assessed by four independent observers, three of whom evaluated digital images of the models, while the fourth had no access to the images, and determined the shapes using an algorithm developed from the dimensions of the studied segments. Rates and confidence intervals were determined, and Fleiss' Kappa was calculated to assess the agreement among the evaluators who worked with the images and among all of them.

Average incisor length was 10 mm, and widths at CD and EF were 7.35 mm (0.65) and 8.27 mm (0.58), respectively. Regarding shapes, 51.58% (47.90-55.20) of the incisors were identified as square, 18.02% (14.50-21.90) as ovoid and 30.41% (30.00-30.90) as triangular. Fleiss' Kappa agreement was 0.71 (0.62-0.80). The application of the proposed algorithm provided a considerable level of agreement among the observers. Regarding tooth size, both the average segment length and the proportions were similar to those reported by various authors.

Received: January 2021; Accepted: April 2021.

Keywords: *incisors - dental esthetic - tooth, anatomy.*

Prevalencia de forma y tamaño de los incisivos centrales en estudiantes universitarios argentinos: determinación visual y mediante un nuevo método estandarizado

RESUMEN

El objetivo de este trabajo fue analizar las dimensiones de las coronas clínicas de incisivos centrales superiores, y la prevalencia de cada una de las formas dentarias según diferentes formas de determinación. Se utilizaron modelos de yeso tipo V de 111 estudiantes (93 mujeres y 18 varones) con una media de edad de 23,70 (± 2,26) años. Se definieron los ángulos vestíbulo - mesial y distal para los incisivos centrales superiores derechos (1.1), se definieron los siguientes segmentos: AB (cenit - borde incisal), CD, EF, GH (tercios apical, medio e incisal - ángulos vestíbulo - mesial y vestíbulo- distal) y se determinaron sus longitudes con un calibre de precisión. Se calcularon las proporciones CD/AB, EF/AB y media CD-EF/AB. Las formas de las piezas dentarias fueron identificadas por cuatro observadores independientes, tres lo hicieron mediante la evaluación de imágenes digitales de los modelos confeccionados. El cuarto observador, sin acceso a las imágenes, asignó a cada pieza una de las formas determinadas mediante la aplicación de un algoritmo elaborado ad-hoc. Se obtuvieron tasas e intervalos de confianza y se calculó Kappa de Fleiss para valorar la concordancia entre evaluadores.

La longitud promedio fue de 10 mm y el ancho en los segmentos CD y EF fueron de 7.35 mm (0.65) y 8.27 mm (0.58) respectivamente. En cuanto a formas el 51,58% (47.90-55.20) de los incisivos estudiados fueron identificados como cuadrados, el 18.02% (14.50-21.90) como ovoides y el 30,41% (30.00-30.90) triangulares. La concordancia de Kappa de Fleiss fue de 0.71 (0.62-0.80). La aplicación del algoritmo propuesto alcanzó un nivel de concordancia considerable entre los evaluadores. En cuanto al tamaño dentario, tanto la longitud promedio de los segmentos estudiados como las proporciones halladas son similares a las reportadas por diversos autores.

Palabras clave: *incisivos - estética dental - anatomía dentaria.*

INTRODUCTION

The search for an attractive smile has become an increasingly frequent demand in dental practice. This has motivated material development and knowledge creation in the field of restorative dentistry[1].

Over the years, dentists have planned cosmetic treatments based on a set of parameters, such as size, shape, color, alignment, and lines of symmetry of teeth[2-5]. As early as 1815, Schimmelpennick[6] established the existence of five shapes for facial contours, upon which Williams relied in 1915 to define the three fundamentals of the vestibular faces of the upper central incisors as triangular, ovoid and square. Fradeani[4] stated that triangular-shaped incisors are those in which the outer limits of the contour of the buccal aspect diverge towards the incisal, creating a narrow cervical area; ovoid incisors have external limits that tend to be curved and rounded and show a gradual reduction of the cervical area and the incisal edge, and square incisors have more or less straight, parallel external limits and therefore a wide cervical area and wide incisal edge.

Lombardi[7] was one of the first authors to note the importance of tooth dimensions in relation to the sequence in which they are seen, from the central incisor to the first premolar, and established the upper central incisor as the dominant tooth by virtue of size and order of appearance in the smile. In terms of proportion, Davis[8] noted that the generally accepted range for the width of the central incisor is 75-80% of its height.

Some authors have mentioned that tooth size and shape differ according to ethnicity, gender and dietary habits[9], and others have even found apparent differences between individuals of the same ethnicity[10-13]. Sterrett et al.[14], for example, analyzed the size of the antero-superior teeth with a caliper applied to dental gypsum models of Caucasians and found significant differences in the width and height of all the teeth studied. Chou et al.[15] found that the vertical and horizontal dimensions of clinical crowns were significantly higher in men than in women. On the other hand, Tsukiyama et al.[16] found that maxillary teeth appeared to be narrower in Asians than in Caucasian Swiss individuals.

Regarding evaluation of tooth dimensions, Olsson et al.[17], in a study based on clinical photographs, established the length of the clinical crown as the distance between the gingival margin and the incisal edge, and after dividing this segment in three equal portions (cervical, middle and incisal), established the mesiodistal distance by assessing the height of the union of the cervical and middle portions as the width of the crown and, finally, they calculated the width/height ratio from the obtained data. All these parameters were applied by Chou et al.[15] to determine the size of teeth on diagnostic stone models using a Mitutoyo caliper. Tsukiyama et al.[16] and Olsson el al.[17] used standardized high-resolution images of ex-vivo teeth from white and Asian subjects on which they registered the widest section of the mesiodistal plane of the anatomical crown (perpendicular to the longitudinal axis of the tooth) and the greatest cervico-incisal distance of the anatomical crown (parallel to the longitudinal axis of the tooth). In the same way, Sandeep et al.[18] used both resources (dental stone models and digital photographs) from a South Indian population, and using a digital caliper, defined crown width as the widest distance between the mesial and distal contact points (perpendicular to the axis longitudinal of the tooth), and crown length as the longest distance between the cervical margin and the incisal edge (parallel to the longitudinal axis of the tooth). The literature contains studies by different authors evaluating tooth shape, some of which have used the Kappa concordance test, which provided values that could be considered as moderate concordance according to the studies by Landis and Koch[19-21].

To date, no publication has been found regarding the size and shape of the maxillary anterior tooth segment in the population of Argentina.

The aim of this study was to analyze the dimensions of the clinical crown of upper central incisors and the prevalence of each tooth shape described according to different methods of determination, in models from fourth-year dentistry students from Buenos Aires University, Argentina.

MATERIALS AND METHODS

This study was conducted on models of the upper jaw of 111 students [93 female and 18 male, mean age 23.70 (SD 2.26) years], at Buenos Aires University. Exclusion criteria were presence of total or partial peripheral restorations, fractures or carious and non-carious lesions in upper central incisors, and absence of any of the central incisors.

Models made of dental stone type V (Prima Rock; WhipMix Corp., Louisville, KY, USA) were used.

Frontal images were taken of each model and sent to three observers (O1, O2 and O3), who assigned one of the following shapes to each incisor: square (S), ovoid (O) or triangular (T), in an Excel (Microsoft) spreadsheet. After the photographic record, the following were identified in each model: the vestibule-mesial and vestibule-distal angles (with a homogeneous line (L) obtained by sliding an automatic pencil tangent to the respective proximal faces. Fig. 1 shows the zenith (A) and the midpoint of the incisal edge (B) of the right central incisor. Once segment A-B had been traced on each tooth, its length (AB) was determined and divided into three equal parts; cervical (C), middle (M) and incisal (I), with two segments whose external limits were defined by their intersection with L. In this way, CD (middle limit of the cervical third) and EF (incisal limit of the middle third) were established, as shown in Fig. 2.

A precision gauge (Compas Castroviejo; Ref. 3337.04, Prodont Holliger, La Marnasse, Olliergues, France) was used to determine the lengths of segments AB, CD, EF and GH for each upper right central incisor (1.1) in each model[15]. Then the ratios CD/AB, EF/AB and mean CD-EF/AB were calculated. The information was sent to a fourth observer (O4), who had no access to the images of the models and was asked to assess the shape of each incisor according to the algorithm shown in Fig. 3, for which basic criteria are summarized in Table 1.

The dimensions of segments and proportions of the incisors were statistically analyzed with descriptive statistics: mean, median, mode, minimum and maximum values and range. The prevalence rates (CI 95%) of each shape were calculated according to each form of determination. Agreement among observers 1, 2 and 3, and among observers 1, 2, 3 and 4 was assessed using Fleiss' Kappa. Comparison between sexes was made using 1-way ANOVA with a significance level of 0.05.

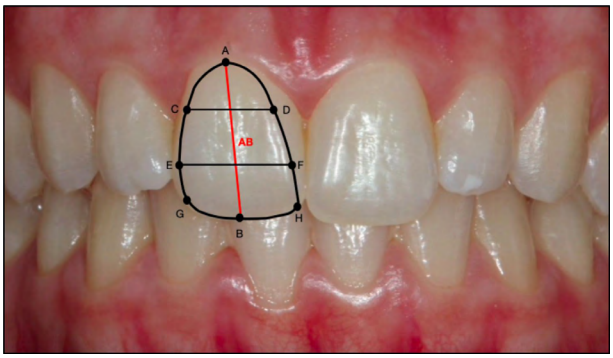

Fig. 1: The image shows segment AB, formed by points A and B, which determines the upper crown. Segments CD, EF and GH define the dimensions of the cervical, middle and incisal thirds.

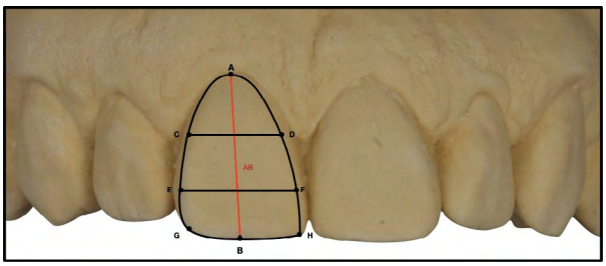

Fig. 2: Gypsum model with delimited segments.

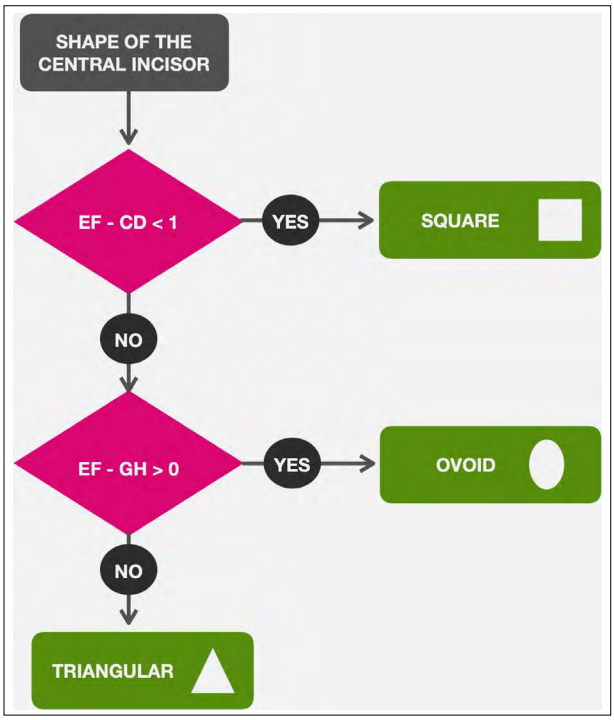

Fig. 3: Algorithm to standardize the assessment of tooth shape.

Table 1. Criteria for assigning tooth shape

Square	EF-CD < 1
Ovoid	EF-CD ≥ 1 and EF-GH > 0
Triangular	EF-CD ≥ 1 and EF-GH ≤ 0

RESULTS

The mean (SD) of segment AB (length) of the incisors studied was 10 (0.97) mm with a range of 5.80 mm, while the means (SD) of the three width segments CD, EF and GH were 7.35 (0.65) mm, 8.27 (0.58) mm, and 8.20 (0.55) mm, respectively (Table 2).

Mean proportions (SD) were 0.74 (0.08) for CD/AB, 0.83 (0.08) for EF/AB, and 0.79 (0.08) for CD-EF/AB (Table 3).

Table 2. Descriptive statistics of lengths of segments AB, CD, EF and GH

	Mean (SD)	Median	Mode	Minimum	Maximum	Range
AB	10.00 (0.97)	10.00	10.40	7.40	13.20	5.80
CD	7.35 (0.65)	7.30	7.00	6.00	9.10	3.10
EF	8.27 (0.58)	8.20	8.20	6.90	9.60	2.70
GH	8.20 (0.55)	8.20	8.00	6.50	9.80	3.30

Table 3. Descriptive statistics of the proportions between AB and CD, EF and the mean CD-EF

	Mean (ds)	Median	Mode	Minimum	Maximum
CD/AB	0.74 (0.08)	0.74	0.85	0.55	0.98
EF/AB	0.83 (0.08)	0.84	0.84	0.66	1.08
CDEF/AB	0.79 (0.08)	0.79	0.79	0.61	1.03

Regarding the prevalence (CI 95%) of the different shapes, on average, 51.58% (47.90 - 55.20) of the incisors studied were identified as square, 18.02% (14.50 - 21.90) as ovoid, and 30.41% (30.00 - 30.90) as triangular (Fig. 4). In terms of the agreement among the different observers and the different assessment modes, the three observers who assessed incisor shape through photographs reached an agreement of 80.48% with a Fleiss' kappa of 0.71 (0.62-0.80). When the fourth observer, who assigned the shape by applying the proposed algorithm, was included in the analyses, the overall agreement was 71.77%, Fleiss' kappa: 0.58 (0.50-0.66) (Table 4).
In terms of effect of sex on the dimensions of incisor 1.1, after data analysis, statistical difference (P<0.05) was found only in segment AB (Table 5).

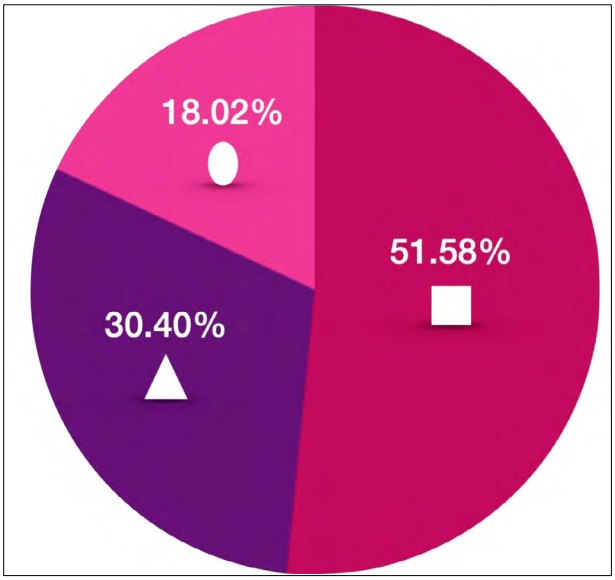

Fig. 4: Prevalence of different tooth shapes

Table 4. Prevalence of shapes assigned by the different observers and agreement rate between them (CI 95%)

	Observer 1	Observer 2	Observer 3	Observer 4
Square	46.85 (37.31 - 56.55)	50.45 (40.80 - 60.80)	54.95 (45.22 - 64.41)	54.05 (44.33 - 63.55)
Ovoid	22.52 (15.14 - 31.43)	19.82 (12.86 - 28.46)	14.41 (8.47 - 22.35)	15.32 (9.18 - 23.39)
Triangular	30.63 (22.26 - 40.09)	29.73 (21.43 - 39.15)	30.63 (22.23 - 40.09)	30.63 (22.23 - 40.09)
Fleiss' kappa (free marginal (CI95%)	Overall agreement: 80.48% Fleiss' kappa: 0.71 (0.62-0.80)			
	Overall agreement: 71.77% Fleiss' kappa: 0.58 (0.50-0.66)			

Table 5. Mean (SD) of dimensions and proportions according to sex

Sex	AB	CD	EF	CD/AB	EF/AB
Female (n=93) 84%	9.90 (0.93)	7.33 (0.65)	8.24 (0.56)	0.75 (0.08)	0.84 (0.08)
Male (n=18) 16%	10.52 (1.01)	7.47 (0.62)	8.41 (0.64)	0.71 (0.05)	0.80 (0.06)
P	0.01	0.40	0.25	0.11	0.08

DISCUSSION

One of the greatest difficulties in the oral rehabilitation process is the successful restoration of aesthetics and function, for which the correct determination of the dimension and shape of the teeth is a key factor. Therefore, the finding of certain anatomical references in terms of tooth size and shape in order to standardize their assessment, could be relevant[19].

Although various authors have studied the morphology and tooth size of the upper central incisor in different ethnic groups over the years, no publication referring to inhabitants of Argentina has been found.

According to tooth size, the values obtained in the current study for segment AB (crown length) are similar to the results reported by authors who studied populations from Asia (Taiwan), in which 52% males and 48% females were evaluated[15]. This similarity could be due to the proportion of females in the cohort of in the present study (84% females and 16% males). Different results were obtained by other authors who compared an Asian population (Japan) to a Caucasian population (Switzerland), without specifying sex, on ex-vivo teeth, for which the reference points used for the determination of crown length were not the same[16]. Various reference points have been used for the determination of the crown length and mean width in different publications. Several authors found similar results in Asian populations, but they differ from the Caucasian populations studied in their publications[15,16]. This discrepancy could be due to the higher percentage of females in the current study.

Regarding the width/height ratio of the clinical crown of the upper central incisor, our study found similar results to those reported for Asian (Japan, Taiwan), Caucasian (Switzerland, Sweden) and southern Indian populations, so it would seem that although the absolute dimensions vary among ethnic groups, the proportions appear to differ to a lesser extent[15-18].

On the other hand, the results of the crown width/height ratio found in the current study are within the 75-80% percentage described by Davis as aesthetically pleasing values. [8]

Several studies report that the mean width and height of the clinical crowns of front upper teeth were significantly greater in males than in females of the study populations[11-15]. In the current study, the only dimension that was found to be significantly greater in males than in females was crown length (AB). This may be due to the low proportion of males in the study population, so future research should consider a population with higher proportion of males.

Regarding the prevalence of upper central incisor shapes, all the observers reported highest frequency for square shape (51.58%) (47.90 - 55.20) followed by triangular (30.41%) (30.00 - 30.90), and lastly, ovoid (18.02%) (14.50 - 21.90). Paranhos et al. obtained different results, with a higher prevalence of ovoid teeth, followed by quadrangular and triangular teeth, in a study on a Caucasian population in Brazil[20].

The concordance among the different observers who assigned the tooth shapes was evaluated using Fleiss' Kappa test. Paranhos et al. and Furtado et al. found k values of 0.52 and 0.42, respectively[19,20]. In the present study, values of 0.58 (0.50-0.66) were found among the four observers, three of whom had access to images of the incisors, while the fourth assigned the shapes only by applying the proposed algorithm, without access to images of the models. This level of agreement is considerable, based on the studies by Landis and Koch[21], so we can say that the application of the proposed algorithm to standardize the assessment of tooth shape enabled agreement values among evaluators that were similar to or higher than those obtained in studies in which all observers had visual access to models or images of the teeth studied.

CONCLUSION

Evaluation of shapes by means of the proposed algorithm agreed with evaluation of shapes by means of direct observation.

Within the limitations of the present study, it can be concluded that the most prevalent shape in the study population is square, followed by triangular and then ovoid.

Regarding tooth size, both the average length of the segments studied, and the proportions found are similar to those reported by various authors.

DECLARATION OF CONFLICTING INTERESTS
The authors declared no potential conflicts of interest with respect to the research, authorship, and/or publication of this article.

FUNDING
None

CORRESPONDENCE
Dr. Maria M. Trigo-Humaran
Cátedra de Odontología Restauradora,
Facultad de Odontología, UBA
Marcelo T. de Alvear 2142 9A, C1122AAH,
Ciudad Autónoma de Buenos Aires, Argentina
milagros.trigo@odontologia.uba.ar

REFERENCES

1. Gurel G, Sesma N, Calamita MA, Coachman C, Morimoto S. Influence of Enamel Preservation on Failure Rates of Porcelain Laminate Veneers. Int J Periodontics Restorative Dent 2013;33:31–39.
2. Belser UC. Esthetics checklist for the fixed prosthesis. Part II: Biscuit-bake try-in. In: Scharer P, Rinn LA, Kopp FR, editors. Esthetic guidelines for restorative dentistry. Chicago: Quintessence; 1982. p. 188-192.
3. Magne P, Belser U, Natural oral esthetics. In: Magne P, Belser U, editors. Bonded porcelain restorations in the anterior dentition: a biomimetic approach. Chicago: Quintessence; 2002. p. 57-96.
4. Fradeani M.; Rehabilitación Estética en Prostodoncia Fija. Vol.1; Ed. Quintessence. 1ed.,2006.
5. Kina S., Bruguera A; Invisible. Restauraciones Estéticas Cerámicas. Vol.1; Ed. Panamericana, 2008.
6. Aprile H, Figum ME, Garino R. Anatomía Odontológica funcional y aplicada. Ed El Ateneo.5 ed.,1971.
7. Lombardi RE. The principles of visual perception and their clinical application to denture esthetics. J Prosthet Dent 1973; 23:358-382.
8. Davis NC. Smile design. Dent Clin North Am 2007;51:299-318.
9. Olsson M, Lindhe J. Periodontal characteristics in individuals with varying form of the upper central incisors. J Clin Periodontol 1991; 18:78-82.
10. Townsend GC, Brown T. Heritability of permanent tooth size. Am J Phys Anthropol 1978 49:497- 504.
11. Lavelle CL. Maxillary and mandibular tooth size in different racial groups and in different occlusal categories. Am J Orthod 1972; 61: 29-37.
12. Doris JM, Bernard BW, Kuftinec MM, Stom D. A biometric study of tooth size and dental crowding. Am J Orthod 1981; 79: 326-336.
13. Gillen RJ, Schwartz RS, Hilton TJ, Evans DB. An analysis of selected normative tooth proportions. Int J Prosthodont 1994; 7: 410- 417.
14. Sterrett JD, Oliver T, Robinson F, Fortson W, Knaak B, Russell CM. Width/length ratios of normal clinical crowns of the maxillary anterior dentition in man. J Clin Periodontol 1999; 26: 153-157.
15. Chou Yu- Hsiang, Chi-cheng TsaiJen-Chyan Wang, Ya-Ping Ho, Kun-Yen Ho, Chuen-Chyi Tseng. New classification of crown forms and gingiva characteristics in Taiwanese. Open Dent J 2008; 2:114-119.
16. Tsukiyama T, Marcushamer E, Griffin TJ, Arguello E, Magne P, Gallucci GO, Comparison of the anatomic crown width/length ratios of unworn and worn maxillary teeth in Asian and white subjects. J Prosthet Dent 2012;107:11-16.
17. Olsson M, Lindhe J, Marinello CP: On the relationship between crown form and clinical features of the gingiva in adolescents. J Clin Periodontol 1993; 20: 570-577.
18. Sandeep N, Satwalekar P, Srinivas S, Reddy CS, Reddy GR, Reddy BA. An analysis of maxillary anterior teeth dimensions for the existence of golden proportion: clinical study. JInt oral health 2015; 7:18-21.
19. Furtado GC, Furtado A, El Haje OA, Butignon LE, Pesqueira AA, Paranhos LR. Relationship between the morphology of the maxillary central incisor and horizontal and vertical measurements of the face. Indian J Dent Res. 2020 25: 178-183.
20. Paranhos LR, Souto Lima C, Alves da Silva RH, Daruge Júnior E, Torres FC. Correlation between maxillary central incisor crown corphology and candibular dentala form in normal occlusion subjects. Braz Dent J 2012; 23: 149-153.
21. Landis JR, Koch GG. The measurement of observer agreement for categorical data. Biometrics 33, 159-174.

Impact of soft tissue graft on the preservation of compromised sockets: a randomized controlled clinical pilot study

Bruno Segnini[1], Fausto F. F. Borges-Filho[2], Lélis G.Nicoli[1], Marcelo Gonçalves[1], Cláudio Marcantonio[3], Guilherme J.P.L. Oliveira[4], Elcio Jr. Marcantonio[1,5]

1. Universidade Estadual Paulista, Faculdade de Odontologia de Araraquara, Departamento de Diagnostico e Cirurgia, Araraquara, Brasil.
2. Faculdades Integradas Espírito-Santenses, Faculdade de Odontologia, Departamento de Clínica Odontológica, Vitória, Brasil.
3. Universidade de Araraquara, Faculdade de Odontologia, Departamento de Implantodontia, Araraquara, Brasil
4. Universidade Federal de Uberlândia, Faculdade de Odontologia , Departamento de Periodontia e Implantodontia , Uberlândia, Brasil
5. Faculdade Ilapeo, Faculdade de Odontologia , Departamento de Implantodontia, Curitiba, Brasil

ABSTRACT

The aim of this pilot study was to evaluate the impact of the association of free gingival graft (FGG) or collagen-matrix xenograft (CMX) to deproteinized bovine bone graft (DBBG) on the preservation of post-extraction sockets with facial-wall defects. Sixteen patients who presented a maxillary tooth with a facial bone defect and indication of extraction were selected. After the surgical procedure, all the post-extraction sockets were filled with DBBG and covered with a collagen membrane. The cervical part of the socket was then sealed with either FGG or CMX. Clinical and tomographic analyses were performed at baseline and 4 months after the grafting procedure. The FGG sockets showed higher values for the width of the bone ridge than the CMX sockets at 4 months. There was no difference regarding biopsy composition. In conclusion, regardless of the type of soft tissue graft used, socket preservation with DBBG at sites presenting facial bone defects enabled implant placement without further guided bone regeneration, whether the sockets were sealed with FGG or CMX.

Received: March 2021; Accepted: May 2021.

Keywords: *bone substitutes - dental materials - bone replacement - guided tissue regeneration.*

Impacto do enxerto de tecido mole na preservação de alvéolos comprometidos: um estudo piloto clínico controlado randomizado

RESUMO

O objetivo deste estudo piloto foi avaliar o impacto da associação de enxerto gengival livre (FGG) ou xenoenxerto de matriz de colágeno (CMX) ao enxerto ósseo bovino desproteinizado (DBBG) na preservação de alvéolos pós-extração com defeitos da parede óssea vestibular. Foram selecionados 16 pacientes que apresentavam dente superior com defeito ósseo vestibular e indicação de extração. Após o procedimento cirúrgico, todos os alvéolos pós-extração foram preenchidos com DBBG e recobertos por membrana de colágeno. A parte cervical dos alvéolos foi então selada com FGG ou CMX. As análises clínicas e tomográficas foram realizadas no início do estudo e 4 meses após o procedimento de enxerto. Os alvéolos pós-extração tratados com FGG apresentaram maiores valores para a largura da crista óssea do que os alvéolos tratados com CMX na avaliação de 4 meses. Não houve diferenças em relação à composição da biópsia. Em conclusão, independentemente do tipo de enxerto de tecido mole utilizado, a preservação dos alvéolos com DBBG em locais com defeitos ósseos faciais permitiu a colocação do implante sem regeneração óssea guiada.

Palavras-chave: *substitutos ósseos - materiais dentários - substituição ósea - regeneração óssea guiada.*

INTRODUCTION

Despite the rapid evolution of dentistry in recent years, tooth loss is still a public health issue around the world[1], and a considerable part of the population may still need rehabilitation with dental implants and prostheses to replace lost teeth. Unless sufficient bone is available, placing a dental implant in an adequate position for successful prosthetic rehabilitation may require guided bone regeneration (GBR) procedures[2,3]. Therefore, preservation of the ridge volume should be considered whenever a tooth is extracted.

After tooth extraction, the socket undergoes several biological events leading to bone formation in its internal portion, and bone loss, especially on the facial aspect[4] of the socket. Ridge dimensions are reduced after extraction and it may not be possible to install a dental implant without GBR procedures, particularly in critical aesthetic areas. Several studies have demonstrated the uneventful bone-remodeling pattern in intact extraction sockets and reported a loss of approximately 50% of its original width[5-8], which represents an absolute loss of 2.6-4.6 mm[9-12]. In such situations, socket preservation with slow-resorbing osteoconductive biomaterials can reduce this loss to values of about 0.5-1.5 mm[9,11,13,14].

Teeth that are indicated for extraction normally present complications such as fracture, extensive decay, root resorption or bone loss[1,15]. The dynamics of bone remodeling is impaired when bone defect in the socket is present[3]. If one of the socket walls is damaged, more bone resorption can be expected after tooth extraction, even when socket preservation is performed. The osteoconductive properties of the biomaterial and its role in maintaining space is hindered in compromised sockets[13,16].

While bone grafts such as deproteinized bovine bone graft (DBBG) must be placed within the remaining bone walls, a soft tissue graft can also be used to seal the socket surface[3,17]. Autologous free gingival graft, sub-epithelial connective tissue graft, or a soft tissue substitute can all be used as socket sealers to prevent contamination, outer migration of bone particles, and flap advancement and displacement of the mucogingival junction. Post-operative discomfort, bleeding, and increased surgery time are among the drawbacks encountered when autologous free gingival grafts are employed[18,19].

The use soft tissue substitutes (STS) prevents morbidity at the harvesting site and enables the match of tissue texture and color[20,21]. The heterologous 3-dimensional collagen matrix is an STS that presents two layers: a compact layer that enables sutures and provides stability; and a spongy layer that increases blood absorption, clot organization and integration of the graft to the recipient site[22]. This kind of substitute is usually recommended in intact sockets, which restricts its use in clinical practice. In order to evaluate its performance in more challenging situations, the aim of this randomized controlled clinical pilot study was to evaluate the impact of the association of free gingival graft (FGG) or collagen-matrix xenograft (CMX) to deproteinized bovine bone graft (DBBG) on the preservation of post-extraction sockets with facial-wall defects. The null hypothesis tested in this study was that FGG and CMX present the same clinical, tomographic and histomorphometric outcomes.

MATERIAL AND METHODS

Study Design

For this trial, 16 patients were selected who had a maxillary premolar, a canine, or an incisor with a facial bone defect and indicated to be extracted. The sample consisted of patients who sought care at the School of Dentistry of Araraquara (FOAr-UNESP). The study was approved by the Ethics Committee on Human Studies: 32432714.3.0000.5416. Clinical and tomographic examinations were performed on the region to be intervened in each patient. Patients were selected according to the following criteria:

- Inclusion criteria: good oral hygiene with a plaque index below 20%; presence of teeth adjacent to the tooth to be extracted with harmonious gingival architecture; age 18-65 years; level of clinical insertion on the labial surface > 3 mm.
- Exclusion criteria: history of periodontal surgical procedures in the region to be operated; systemic disorders that would make them ineligible for surgical procedures; presence of infection involving the gingival margin; history of radiotherapy treatment in the head and neck region; bruxism; individuals considered to be smokers; alcoholics; drug users; diabetics; pregnant; users of medications that might interfere with bone remodeling; and individuals affected by any pathology that could alter bone metabolism.

The surgical procedure was characterized by the removal of the compromised tooth under an atraumatic technique, which employs a periotome

or residual root extractor in an attempt to preserve any remaining labial bone or adjacent bone plates. After extraction, each socket was thoroughly curetted, cleaned and inspected. All post-extraction sockets were filled with deproteinized bovine bone graft (DBBG) associated with 10% collagen (approximately 0.5g per post-extraction socket). Then patients were allocated to two groups according the type of STS used to cover the upper portions of the sockets: CMX –The sockets were covered with a collagen matrix xenograft (Mucograft Seal®, Geistlich Pharmaceutical, Wolhausen, Switzerland); FGG– The sockets were covered with an autologous free gingival graft. The area corresponding to the facial bone wall was covered with an extension of a resorbable collagen membrane (Bio-Gide®, Geistlich Pharmaceutical, Wolhausen, Switzerland). In all patients, the internal epithelium of the gingival margin was initially removed before insertion of the CMX or the FGG, which was fitted and sutured in the recipient site with a 5-0 resorbable thread.

At the end of the surgical procedure, each patient received a removable or adhesive provisional prosthesis, installed over the adjacent teeth for greater aesthetic comfort until the healing phase was completed. Patients were instructed on postoperative care and diet restrictions. For postoperative medications, patients were prescribed oral use of 500 mg of amoxicillin every 8 hours for 7 days, and 200 mg of Ibuprofen every 6 hours in case of pain. Sutures were removed seven days after the surgical procedure.

After 120 days, a new surgical procedure was performed to install a cone-Morse taper implant, (Drive CM®, Acqua surface, Neodent, Curitiba-Brazil) in adequate position for successful prosthetic rehabilitation. In 10 of the patients, 5 from each group, after the flap was elevated and the surgical guide was positioned, the bone edge was first slightly marked with the tip of the spear cutter, which had a median diameter of 2 mm. Drilling for implant installation was initiated with a 2 mm diameter trephine bur, in order to obtain a biopsy of the bone tissue (5-7

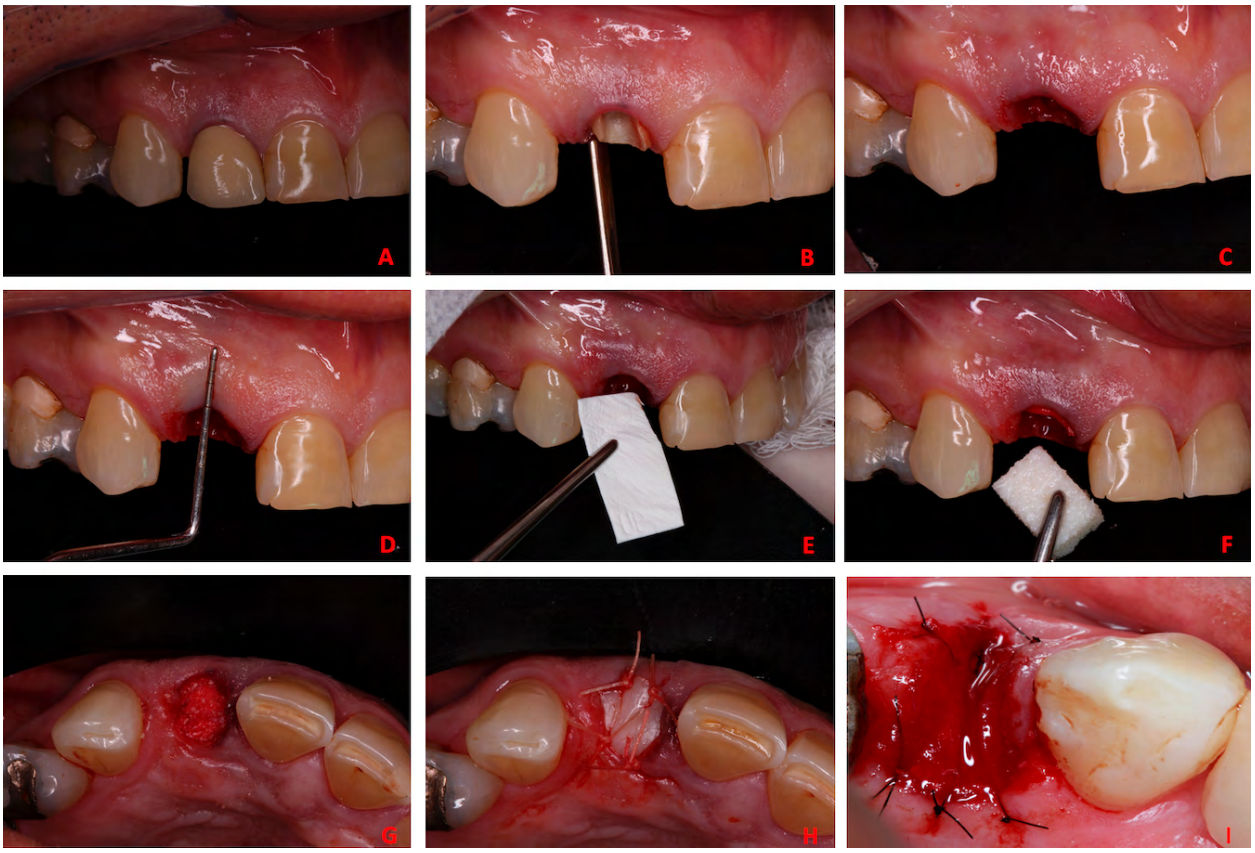

Fig. 1: Surgical procedure. A) The anterior upper tooth indicated for extraction (12); B) Removing the compromised tooth using an atraumatic technique; C) Clinical condition of the post-extraction socket; D) The diagnosis of the reduced labial bone; E) Insertion of the collagen membrane; F) Placement of the DBBG; G) The post-extraction socket filled with DBBG; H) Occlusion of the upper portion of the post-extraction socket with FGG; I) Occlusion of the upper portion of the post-extraction socket with CMX

mm long). For all implants, the bone site was under-drilled in an attempt to increase primary stability values. Following the second surgical procedure, patients received the same provisional prosthesis that had initially been installed, or a new one if any color alteration, cracking or damage was detected. Two months later, the implants were exposed for the installation of a healing abutment and the patients were referred for completion of the restorative treatment. The images of the surgical procedures are provided in Fig.1.

Clinical analysis

Clinical data were recorded at the beginning of the study and 120 days after the grafting procedure, with 16 patients completing this analysis, of whom 7 were from the CMX group and 9 from the FGG (control) group. The height and thickness of keratinized gingiva, gingival margin level, and gingival biotype were measured with the aid of a PCP-UNC 15 millimeter-gauged probe (Millennium-Golgran, São Caetano do Sul, Brazil). The following clinical analyses were performed at baseline and at 120 days after the grafting procedure: height of keratinized gingiva, distance from the gingival margin to the facial (vestibular) crestal bone (GM-VCB) and the palatine crestal bone (GM-PCB); and distance from the distal and mesial papilla to the top of the ridge of the interproximal bone (GM-DIB and GM-MIB). Soft tissue thickness was measured with a caliper, 2 mm apical from the gingival margin. When present, any complications from the surgical procedures were recorded at this stage.

Cone Beam Computed Tomography analysis

Two patients from the FGG group were excluded from tomographic analysis because the final tomography could not be performed. Thus, 7 patients per group were included in this analysis. The patients underwent cone beam computed tomography for dental, bone and gingival evaluation of the surgical area at baseline and 120 days after the surgical procedure, with a Newtom QR-DVT scanner (QR-Verona, Verona, Italy). The following parameters were measured: distance from the top to the base of the facial (vestibular) bone (TB-V); distance from the top to the base of the palatine bone (TB-P); and width of the bone at 2.5mm and 9 mm from the top of the bone ridge. All the measurements were performed with the software Osirix (Pixmeo, Geneva, Switzerland).

Histological analysis and histomorphometric evaluation

The harvested biopsies were decalcified in 7% EDTA for 3 months and then processed to obtain histological sections, and stained with Masson's trichrome. The section was obtained from the central portion of the biopsies, and two sections of each biopsy were analyzed. The entire biopsies were photograph at 25X magnification with the aid of an optical microscope. Then, the images were analyzed to detect the composition of the newly formed tissues as a percentage of the total area of the biopsies (bone, biomaterial and soft tissue). The histological description of the biopsies assessed the quality of the new bone, the appearance of the bone substitute remnants, the interface between the bone substitutes particle and bone, and the inflammatory response.

Statistical Analysis

All the data generated by this study had normal distribution, confirmed by the Kolgomorov-Smirnov normality test; so parametric models were used for inferential data analysis ($p > 0.05$). The comparison within each group between experimental times was performed using the paired t-test, while the comparison between groups within each experimental time was performed using the unpaired t-test. Graphpad Prism 6 software (San Diego, CA, USA) was used to perform the statistical analysis and all tests were applied at a significance level of 5%.

RESULTS

Computed Tomography Analysis

Both treatments were found to promote an increase in TB-V values by the end of 4 months compared to baseline. Sites treated with FGG showed higher values in the L-2mm and L-5mm regions than the CMX sites at 4 months (Table 1).

Clinical analysis

The surgical procedure was observed to promote a decrease in the values of GM-VCB over the 4-month period in both groups. At 4 months, defects treated with CMX showed higher values of GM-PCB than those treated with FGG (Table 2).

Histological analysis

Histometric analysis of biopsy composition showed little presence of biomaterial, and strong presence of bone and soft tissue, with no difference between

Table 1. Mean and standard deviation data on tomographic analysis in both evaluation times

Parameters/ Time	Baseline		4 months	
	FGG	XCM	FGG	XCM
TB-V	10.03±4.52	8.85±3.77	17.52±3.91***	15.60±2.05*
TB-P	16.53±4.56	15.13±3.52	16.82±5.10	17.12±0.93
W-2mm	8.17±0.87	7.45±1.25	7.88±1.03δ	6.21±1.42
W-5mm	9.41±1.65	8.06±1.34	8.78±0.93δ	7.25±1.14
W-9mm	10.10±2.50	9.18±1.55	9.84±2.46	8.86±1.21

TB-V- Distance from the top to the base of the vestibular bone; TB-P- Distance from the top to the base of the palatine bone; W-Width. *p<0.05; **p<0.01- Higher values than at baseline – Paired t-test; δp<0.05- Higher values than the XCM at 4 months – Unpaired t-test.

Table 2. Mean and standard deviation data from the clinical analyses at baseline and 4 months.

Parameters/ Time	Baseline		4 months	
	FGG	XCM	FGG	XCM
GM-VCB	5.66±0.81	8.16±1.47δδ	4.50±1.04#	5.33±1.03##
GM-PCB	3.33±1.03	3.16±0.75	3.33±1.03	3.66±1.03*
GM-MIB	3.33±0.81	3.58±0.49	3.16±0.40	3.83±0.75
GM-DIB	3.33±0.81	3.16±0.75	3.00±0.00	3.50±0.54
GT	2.41±0.49	2.08±0.49	2.16±0.40	2.25±0.41

GM-VCB: Distance from gingival margin to the vestibular crestal bone; GM-PCB: Distance from gingival margin to the palatine crestal bone; GM-MIB: Distance from gingival margin to the mesial interproximal bone; GM-DIB: Distance from gingival margin to the distal interproximal bone; GT-Gingival thickness. *p<0.05 – Higher values than at baseline - Paired t-test; #p<0.05; ##p<0.01 – Lower values than at baseline - Paired t-test. δp<0.01- Higher values than the FGG at baseline - Unpaired t-test.

groups. The grafted areas presented bone with high degree of maturation, organized in concentric lamellae, with bone formed in close contact with the remaining DBBG particles without major inflammatory findings (Fig. 2).

Histomorphometic Evaluation

The CMX group showed 34.08 ± 5.12 % of bone, 4.98 ± 2.45% of remnants of biomaterial and 60.94 ± 8.14% of soft tissue. The FGG group showed 32.60 ± 6.05 % of bone, 7.93 ± 4.31% of bioma-

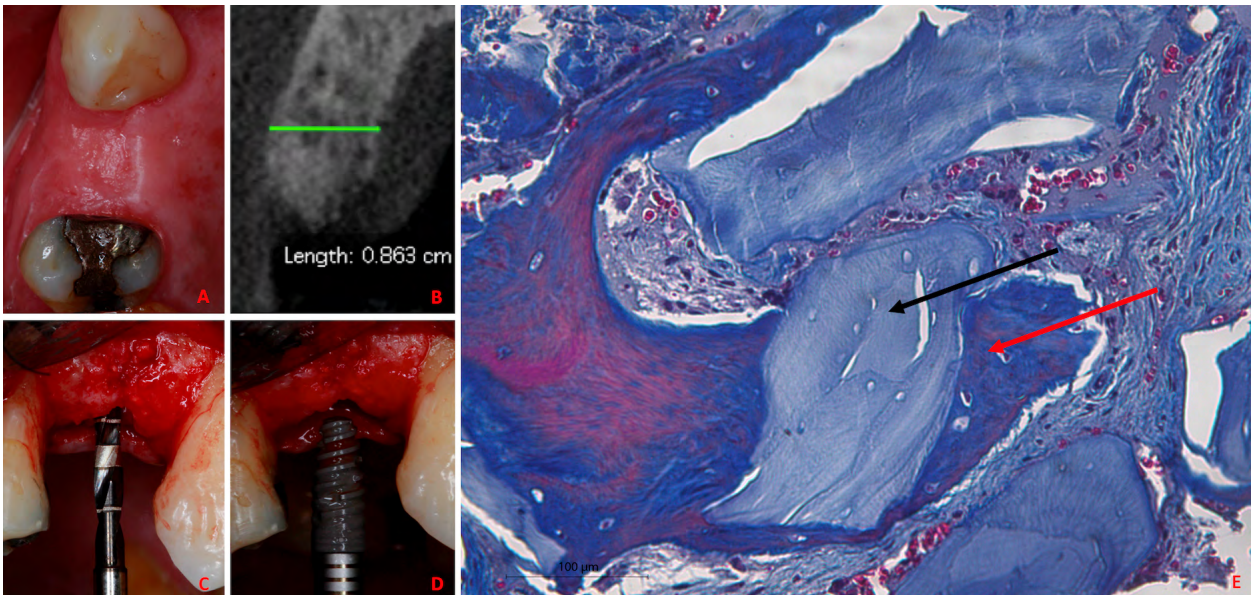

Fig. 2: Follow-up 4 months after the surgical procedure. A) Clinical condition of the soft tissues with adequate amount of keratinized tissues; B) CT images showing an adequate amount of bone tissue for implant placement; C) Drilling the bone for implant placement; D) Implant placement; E) Biopsy analysis showed presence of DBBG (Black Arrow) in close contact with the new bone (Red arrow) – (Masson Trichrome stain – 100x original magnification)

terial and 59.57 ± 7.83 % of soft tissue. Figure 2 shows the clinical conditions and the appearance of the biopsies 4 months after the graft procedure in both groups.

DISCUSSION

The presence of large buccal defects associated with post-extraction sockets impairs immediate implant placement and requires reconstruction using the guided bone regeneration technique[5]. The use of STS has recently been indicated in these cases in order to improve the soft tissue conditions prior to implant placement[16]. This study showed that CMX may be an alternative for FGG, since socket preservation at sites with labial wall defects enabled successful placement of dental implants after four months of healing without further GBR. Thus, the null hypothesis was accepted. A previous prospective clinical study compared the outcomes of socket preservation with deproteinized bovine bone mineral containing 10% of porcine collagen associated with a saddle subepithelial connective tissue graft (SCTG) in intact and compromised sockets. The need for complimentary grafting during implant placement has been reported especially at sites presenting a labial bone defect[16]. It is important to understand that there is a greater biological challenge in compromised sockets, resulting in reduced ridge dimensions after healing even when socket preservation is performed.

In this study, there was no significant statistical difference for soft tissue thickness according to the soft tissue graft used. Since the graft was used only as a sealer in the occlusal portion of the socket, there was no increase in labial soft tissue volume. In a previous study, our group reported greater volume in patients who received SCTG than in patients who were treated with CMX or with no soft tissue graft[3]. This seems to have occurred because the study evaluated the impact of the soft tissue grafts in compromised sockets that received an immediate provisional implant, so the grafts were placed on a labial pouch. While the regeneration of the ridge architecture can be quite challenging by doing GBR only, the use of soft tissue grafts can compensate for the remaining defect and provide a thick, more resilient peri-implant mucosa[3,16].

Treatment of sockets with DBBG containing 10% of porcine collagen has been extensively demonstrated in both animal[23-25] and human studies[3,26-28]. Although most studies have reported outcomes in intact sockets, our greatest clinical challenges are sockets that present bone defects. Several techniques have been described for regenerating a missing facial wall but the results are limited to the vertical and horizontal extent of the bone defect[29,30]. Moreover, there seems to be a lack of consensus on whether or not a membrane should be used in association with bone grafts when sockets are treated for bone regeneration[8,31,32]. Nonetheless, our choice in this study was to use a collagen membrane to prevent migration of cells from the soft tissue and try to foster regeneration of the missing bone wall.

The socket undergoes several events after extraction, and most of the ridge reduction occurs in the first three months. However, remodeling of the ridge thickness continues throughout the patient's life. The thickness of the facial wall and the size of the defect can play a major role in the socket regeneration and long-term maintenance. In cases where there is a thick facial wall, less resorption can be expected after tooth extraction. In aesthetic areas, this wall is rarely thicker than 2 mm, and is usually about 0.5 mm thick[33,34]. Whenever there is a defect on the facial wall, both vertical and horizontal aspects must be assessed. Kan et al[35] demonstrated greater soft tissue alterations in wider defects, while Pang et al[34] showed that socket preservation presented a remarkable effect whenever the defects were greater than 5 mm. In our study, there was a significant difference between groups regarding the facial bone vertical defect, where patients from the CMX group presented greater labial loss. This difference occurred most likely due to the small sample size and could have been influenced by the fact that patients who received CMX had a greater area to be regenerated and less bone support to aid in the new bone formation.

Considering this result, it could be argued that CMX outperformed the free gingival graft, but there is no evidence in such regard. In this type of technique, both soft tissues can be used to seal the socket and avoid the need to raise and advance a flap, while the DBBG would be responsible for the bone regeneration[20,31]. This was shown in the histological analysis, as there was no significant statistical difference between groups. The use of soft tissue substitutes as socket sealers is technically less challenging, more reproducible and therefore more advantageous than most of the rather more elaborate grafting techniques available.

Socket preservation in sites presenting a facial bone defect enabled placement of a dental implant without further GBR, regardless of the type of soft tissue graft used to seal the socket.

DECLARATION OF CONFLICTING INTERESTS
The authors declare no potential conflicts of interest regarding the research, authorship, and/or publication of this article

FUNDING
None

CORRESPONDENCE
Elcio Marcantonio Jr
Humaitá St., 1680. Zip-Code 14801-130, Araraquara, SP. Brasil
elciojr@foar.unesp.br

REFERENCES

1. Kassebaum NJ, Smith AGC, Bernabé E, Fleming TD et al. Global, Regional, and National Prevalence, Incidence, and Disability-Adjusted Life Years for Oral Conditions for 195 Countries, 1990-2015: A Systematic Analysis for the Global Burden of Diseases, Injuries, and Risk Factors. J Dent Res. 2017;96:380-387.
2. Chiapasco M, Casentini P. Horizontal bone-augmentation procedures in implant dentistry: prosthetically guided regeneration. Periodontol 2000. 2018; 77:213-240.
3. Frizzera F, de Freitas RM, Muñoz-Chávez OF, Cabral G et al. Impact of Soft Tissue Grafts to Reduce Peri-implant Alterations After Immediate Implant Placement and Provisionalization in Compromised Sockets. Int J Periodontics Restorative Dent. 2019; 39:381–389.
4. Araújo MG, Lindhe J. Dimensional ridge alterations following tooth extraction. An experimental study in the dog. J Clin Periodontol. 2005; 32:212-218.
5. Nevins M, Camelo M, De Paoli S, Friedland B et al. A study of the fate of the buccal wall of extraction sockets of teeth with prominent roots. Int J Periodontics Restorative Dent. 2006; 26:19-29.
6. Van der Weijden F, Dell'Acqua F, Slot DE. Alveolar bone dimensional changes of post-extraction sockets in humans: a systematic review. J Clin Periodontol. 2009; 36:1048-1058.
7. Tan WL, Wong TL, Wong MC, Lang NP. A systematic review of post-extractional alveolar hard and soft tissue dimensional changes in humans. Clin Oral Implants Res. 2012; 23 Suppl 5: 1-21.
8. Tan-Chu JH, Tuminelli FJ, Kurtz KS, Tarnow DP. Analysis of buccolingual dimensional changes of the extraction socket using the "ice cream cone" flapless grafting technique. Int J Periodontics Restorative Dent. 2014; 34:399-403.
9. Lekovic V, Kenney EB, Weinlaender M, Han T et al. A bone regenerative approach to alveolar ridge maintenance following tooth extraction. Report of 10 cases. J Periodontol. 1997; 68: 563-570.
10. Covani U, Cornelini R, Barone A. Bucco-lingual bone remodeling around implants placed into immediate extraction sockets: a case series. J Periodontol. 2003; 74: 268-273.
11. Iasella JM, Greenwell H, Miller RL, Hill M et al. Ridge preservation with freeze-dried bone allograft and a collagen membrane compared to extraction alone for implant site development: a clinical and histologic study in humans. J Periodontol. 2003; 74:990-999.
12. Hämmerle CH, Araújo MG, Simion M; Osteology Consensus Group 2011. Evidence-based knowledge on the biology and treatment of extraction sockets. Clin Oral Implants Res. 2012; 23: 80-82.
13. Kan JY, Rungcharassaeng K, Morimoto T, Lozada J. Facial gingival tissue stability after connective tissue graft with single immediate tooth replacement in the esthetic zone: consecutive case report. J Oral Maxillofac Surg. 2009; 67:40-48.
14. Roe P, Kan JY, Rungcharassaeng K, Caruso JM et al. Horizontal and vertical dimensional changes of peri-implant facial bone following immediate placement and provisionalization of maxillary anterior single implants: a 1-year cone beam computed tomography study. Int J Oral Maxillofac Implants. 2012; 27: 393-400.
15. Clark D, Levin L. In the dental implant era, why do we still bother saving teeth? Dent Traumatol. 2019; 35:368-375.
16. Seyssens L, Eghbali A, Christiaens V, De Bruyckere T et al. A one-year prospective study on alveolar ridge preservation using collagen-enriched deproteinized bovine bone mineral and saddle connective tissue graft: A cone beam computed tomography analysis. Clin Implant Dent Relat Res. 2019; 21:853-886.
17. Thalmair T, Fickl S, Schneider D, Hinze M, Wachtel H. Dimensional alterations of extraction sites after different alveolar ridge preservation techniques - a volumetric study. J Clin Periodontol. 2013; 40:721-727.
18. Oates TW, Robinson M, Gunsolley JC. Surgical therapies for the treatment of gingival recession. A systematic review. Ann Periodontol. 2003; 8:303-320.
19. Chambrone L, Sukekava F, Araújo MG, Pustiglioni FE et al. Root-coverage procedures for the treatment of localized recession-type defects: a Cochrane systematic review. J Periodontol. 2010; 81:452-478.
20. McGuire MK, Scheyer ET. Randomized, controlled clinical trial to evaluate a xenogeneic collagen matrix as an alternative to free gingival grafting for oral soft tissue augmentation. J Periodontol. 2014; 85:1333-1341.
21. Jung RE, Ioannidis A, Hämmerle CHF, Thoma DS. Alveolar ridge preservation in the esthetic zone. Periodontol 2000. 2018; 77:165-175.
22. Sanz M, Lorenzo R, Aranda JJ, Martin C et al. Clinical evaluation of a new collagen matrix (Mucograft prototype) to enhance the width of keratinized tissue in patients with fixed prosthetic restorations: a randomized prospective clinical trial. J Clin Periodontol. 2009; 36:868-876.
23. Araújo M, Linder E, Wennström J, Lindhe J. The influence

of Bio-Oss Collagen on healing of an extraction socket: an experimental study in the dog. Int J Periodontics Restorative Dent. 2008; 28:123-135.
24. Araújo MG, Lindhe J. Ridge preservation with the use of Bio-Oss collagen: A 6-month study in the dog. Clin Oral Implants Res. 2009; 20:433-440.
25. Araújo MG, Linder E, Lindhe J. Bio-Oss collagen in the buccal gap at immediate implants: a 6-month study in the dog. Clin Oral Implants Res. 2011; 22:1-8.
26. Araújo MG, da Silva JCC, de Mendonça AF, Lindhe J. Ridge alterations following grafting of fresh extraction sockets in man. A randomized clinical trial. Clin Oral Implants Res. 2015; 26:407-412.
27. Maiorana C, Poli PP, Deflorian M, Testori T et al. Alveolar socket preservation with demineralised bovine bone mineral and a collagen matrix. J Periodontal Implant Sci. 2017; 47:194-210.
28. Troiano G, Zhurakivska K, Lo Muzio L, Laino L et al. Combination of bone graft and resorbable membrane for alveolar ridge preservation: A systematic review, meta-analysis, and trial sequential analysis. J Periodontol. 2018; 89:46-57.
29. Elian N, Cho SC, Froum S, Smith RB et al. A simplified socket classification and repair technique. Pract Proced Aesthet Dent. 2007; 19:99-104
30. Min S, Liu Y, Tang J, Xie Y et al. Alveolar ridge dimensional changes following ridge preservation procedure with novel devices: Part 1--CBCT linear analysis in non-human primate model. Clin Oral Implants Res. 2016; 27:97-105.
31. Huynh-Ba G, Pjetursson BE, Sanz M, Cecchinato D et al. Analysis of the socket bone wall dimensions in the upper maxilla in relation to immediate implant placement. Clin Oral Implants Res. 2010; 21:37-42.
32. You DJ, Yoon HJ. Bone Regeneration with Bilayer Bone Augmentation Technique for the Treatment of Dehiscence-Type Defects Around Implants: A Preliminary Study in Dogs. Int J Oral Maxillofac Implants. 2016; 31:318-323.
33. Sanz M, Cecchinato D, Ferrus J, Pjetursson EB et al. A prospective, randomized-controlled clinical trial to evaluate bone preservation using implants with different geometry placed into extraction sockets in the maxilla. Clin Oral Implants Res. 2010; 21:13-21.
34. Pang KM, Um IW, Kim YK, Woo JM et al. Autogenous demineralized dentin matrix from extracted tooth for the augmentation of alveolar bone defect: a prospective randomized clinical trial in comparison with anorganic bovine bone. Clin Oral Implants Res. 2017; 28:809-815.
35. Kan JY, Rungcharassaeng K, Sclar A, Lozada JL. Effects of the facial osseous defect morphology on gingival dynamics after immediate tooth replacement and guided bone regeneration: 1-year results. J Oral Maxillofac Surg. 2007; 65:13-19.

Anacardium excelsum phytochemical analysis and in vitro antimicrobial activity against oral cavity microorganisms

Andrés M. Rojas[1], Clara J. Durango[1], Solanlly E. García[3], Diego Castañeda-Peláez[2,3], Dabeiba A. García[2], Fredy Gamboa[2,4]

1.Universidad Antonio Nariño, Facultad de Ciencias, Armenia – Quindío, Colombia.
2. Pontificia Universidad Javeriana, Facultad de Odontología, Centro de Investigaciones Odontológicas, Bogotá, Colombia.
3. Universidad Antonio Nariño, Facultad de Odontología, Armenia – Quindío, Colombia
4. Pontificia Universidad Javeriana, Facultad de Ciencias, Departamento de Microbiología, Bogotá, Colombia

ABSTRACT

Infections of the oral cavity have a broad microbial etiological profile that varies according to each microenvironment in the mouth. Such infections often require antimicrobial treatment, which can lead to the development of resistance. There is thus a need to find new therapeutic strategies based on natural plant-derived compounds. The aim of this study was to determine the phytochemical nuclei and the antimicrobial effect of Anacardium excelsum leaf and stem extracts, and of fractions derived from the leaf extract, against Streptococcus mutans *ATCC 25175, Staphylococcus aureus ATCC 35548, Escherichia coli ATCC 25922, Enterococcus faecalis ATCC 19433 and Candida albicans ATCC 10231. The plant material was collected from the Quindío Botanical Garden (Calarcá, Quindío-Colombia), located at an altitude of 1500 meters above sea level. Hydroalcoholic extracts of* A. excelsum *leaves and stems, and fractions of the hydroalcoholic leaf extract, were obtained by percolation extraction. Phytochemical nuclei were identified by thin layer chromatography. The antimicrobial activity of the extracts and fractions (at concentrations of 2, 5, 10, 20 and 40 mg / ml) against the five ATCC reference strains was evaluated using the well diffusion technique on Mueller-Hinton agar. The leaf extract showed no antimicrobial activity against* E. coli, *but it did show antimicrobial activity against S. mutans, S. aureus, E. faecalis and C. albicans, at a concentration of 10 mg/ml, with zones of inhibition of 9 to 11 mm. The ethyl acetate and acetone fractions obtained from* A. excelsum *leaf extract had greatest antimicrobial activity at 10 mg/ml. In conclusion, (1) the A. excelsum leaf extract, and the ethyl acetate and acetone fractions obtained from the leaf extract, had the greatest antimicrobial activity on all the study microorganisms, and (2) the phytochemical nuclei in the fractions (ethyl acetate and acetone) were found to contain phenolic-type compounds, tannins, triterpene-type terpenes and steroidal-type terpenes, which might explain the antimicrobial activity observed..*

Received: January 2021; Accepted: May 2021.

Keywords: *anacardium - plant bioactive compound - anti-infective agent - oral cavity.*

Análisis fitoquímico y actividad antimicrobiana *in vitro* de *Anacardium excelsum* sobre microorganismos de cavidad bucal

RESUMEN

Las infecciones de la cavidad bucal se caracterizan por presentar un amplio perfil etiológico microbiano que varía de acuerdo a cada microambiente en boca. En muchos casos estas infecciones requieren tratamiento antimicrobiano que puede conducir al desarrollo de resistencia. Estos hechos en conjunto generan la necesidad de buscar nuevas estrategias terapéuticas, provenientes de compuestos naturales derivados de plantas. El objetivo de este estudio fue determinar los núcleos fitoquímicos y el efecto antimicrobiano de extractos de hojas y tallos, y de fracciones derivadas del extracto de hojas de Anacardium excelsum contra Streptococcus mutans ATCC 25175, Staphylococcus aureus ATCC 35548, Escherichia coli ATCC 25922, Enterococcus faecalis ATCC 19433 y Candida albicans ATCC 10231. El material vegetal se colectó del Jardín Botánico del Quindío (Calarcá, Quindío-Colombia), situado a una altura de 1500 msnm. Se obtuvieron extractos hidroalcohólicos de hojas y tallos, y fracciones a partir del extracto hidroalcohólico de hojas de A. excelsum mediante extracción por percolación. La identificación de los núcleos fitoquímicos fue realizado por cromatografía en capa delgada. La evaluación de la actividad antimicrobiana de extractos y fracciones, en concentraciones de 2, 5, 10, 20 y 40 mg/ml, frente a las 5 cepas de referencia ATCC, se realizó mediante la técnica de difusión con aplicación en pozo sobre agar Mueller-Hinton. El extracto de hojas no presentó actividad antimicrobiana sobre E. coli pero si sobre S. mutans, S. aureus, E. faecalis y C. albicans, en una concentración de 10 mg/ml, con halos de inhibición desde 9 a 11 mm, y las fracciones de acetato de etilo y acetona obtenidas del extracto de hojas de A. excelsum, presentaron mayor actividad antimicrobiana en una concentración de 10

mg/ml. En conclusión, 1. El extracto de hojas y las fracciones de acetato de etilo y acetona obtenidas del extracto de hojas de A. excelsum *presentaron mayor actividad antimicrobiana sobre todos los microorganismos en estudio; 2. La evaluación de los núcleos fitoquímicos en las fracciones acetato de etilo y de acetona mostraron compuestos de tipo fenólico, taninos, terpenos del tipo triterpenos y terpenos del tipo esteroidal, que posiblemente expliquen la actividad antimicrobiana obtenida.*

Palabras clave: *anacardium - compuestos bioactivos de plantas - agentes anti-infecciosos, cavidad bucal.*

INTRODUCTION

Infections of the oral cavity have a broad microbial etiological profile, which varies according to the specific ecosystem in each part of the mouth, causing a range of clinical pictures with differing frequencies and seriousness[1,2]. Among these infections, odontogenic infections alone account for 7% to 10% of the total antibiotic therapy used in populations, with some cases requiring a combination of treatments and medications for resolution. Moreover, several studies have shown that oral infections can be a risk factor leading to the onset, development and progression of systemic diseases[3]. All of this, added to the problem of the increasing bacterial resistance to antimicrobial agents, creates a pressing need to find new anti-microbial strategies[4].

Within the microbial etiology of infections of the oral cavity, the pathogenic flora consists mainly of *Streptococcus* and *Staphylococcus* species, as well as a series of opportunistic microorganisms[2]. *Streptococcus mutans* has often been associated to the onset and progression of dental caries –a disease with high repercussion in the oral cavity– as well as other infections of odontogenic origin[5]. *Staphylococcus aureus* is present in abscesses of odontogenic origin, being the second most important microorganism following the *viridans* group of *Streptococci,* and appearing recurrently in different infectious lesions of the oral cavity[6]. *Escherichia coli,* which is a very important microorganism of the family Enterobacteriaceae, is also often found in infections of the oral cavity and has great capacity to develop resistance to antimicrobial agents[7]. *Enterococcus faecalis* is associated to root canal infections, as well as being recognized for its broad resistance to different antimicrobial agents[8]. Finally, *Candida albicans* is an opportunistic fungus, and due to its long persistence time in the tissues that it infects, it is closely associated to denture-related stomatitis and different types of candidiasis which are difficult to treat[9].

The particular behavior of many microbial species involved in infections of the oral cavity, and the difficulty to treat some of them, have led to increasing interest in the search for and development of new natural plant-based antimicrobial agents [10-12] Around the world, many different plant species have been used as sources of natural medicines for the treatment of diseases [10-12]. *In vitro* studies have found some raw extracts from plant species to be potentially useful in controlling multidrug resistance[13]. The plant *Anacardium excelsum* (family Anacardiaceae), known in the Andean region by the common name Caracoli, has promising potential for antimicrobial activity. It is a gigantic tree that grows along rivers in tropical zones of the Americas below 1300 m above sea level. Its wood is used commercially for carpentry and canoe building[14]. Within the Anacardium family, *Anacardium occidentale L.* and *Anadenanthera macrocarpa* are known to have anticariogenic activity[15], while *Anacardium occidentale L.*[16] and *Anacardium microcarpum*[17] are known to have antibacterial activity on chemoresistant strains of *S. aureus*. In 2011, Celis et al.[18] reported the antimicrobial activity of extracts and fractions from the species *Anacardium excelsum* against *Bacillus subtillis* and *Staphylococcus aureus*, suggesting that such extracts and fractions may have a potential role in controlling progression and development of dental caries and other odontogenic infections. However, the microbial action of *A. excelsum* extracts has not yet been explored against the microbial pathogens *S. mutans*, *S. aureus, E. coli, E. faecalis* and *C. albicans*, despite their importance as the cause of a range of infections of the oral cavity.

The aim of this study was to determine the phytochemical nuclei and the antimicrobial effect of *Anacardium excelsum* leaf and stem extracts, and of fractions derived from the leaf extract, against reference ATCC strains of *S. mutans*, *S. aureus*, *E. coli, E. faecalis* and *C. albicans*.

MATERIALS AND METHODS

Collection of plant material

Anacardium excelsum was collected from the Quindío Botanical Garden, located in the municipality of Calarcá-Quindío (Colombia) at an elevation of 1500 m above sea level. The plant species was characterized by a botanical expert, who collected and classified the material. For authentication of the plant material collected, a specimen was sent to the herbarium at the University of Quindío, where it was identified as *Anacardium excelsum*.

Extraction

Anacardium excelsum leaves and stems were processed in the laboratory of the School of Basic Sciences at the Antonio Nariño University, Armenia site (Colombia). Approximately 3000 g of each dried plant material was weighed at ambient temperature and ground in a hammer mill. Then it was macerated at ambient temperature in ethanol:water (7:3), for 15 days. The solvent mixture was retrieved for recirculation using a low-pressure rotary evaporator. The extracts were weighed, their yield percentage calculated, and finally labeled and stored at ambient temperature.

Fractionation

Fractionation of the hydroalcoholic extract of *A. excelsum* leaves only was performed with extraction by percolation. To do so, 150 g of the hydroalcoholic extract of *A. excelsum* leaves was weighed and resuspended in the (7:3) ethanol:water system until a homogenous solution was obtained. This extract was absorbed on silica gel flash 100G (Millipore™, Merck KGaA - Darmstadt, Germany) until a fine powder was obtained. For fractionation of the extract, silica 60G (Millipore™, Merck KGaA - Darmstadt, Germany) was used as an extraction base, and solvents with different polarities were used, beginning with the lowest polarity and moving to the highest (ethyl acetate, acetone, ethanol and water). The fractions were dried in a low pressure rotary evaporator. Their yields were calculated and then they were labeled and stored at ambient temperature. Finally, the extracts and fractions were eluted in different solvent systems using thin-layer chromatography (TLC), for which they were resuspended in the appropriate solvents. The phytochemical nuclei present in these fractions of *A. excelsum* leaves were identified using thin layer chromatography and spraying the plate with specific reagents to identify the most relevant nuclei.

Chromatography

Primary fractionation of the hydroalcoholic extract of *A. excelsum* leaves was followed by thin layer chromatography using as stationary phase 1 mm-thick TLC plates with silica gel 60 F_{254} (Millipore™, Merck KGaA - Darmstadt, Germany) on aluminum. Elution was performed with a solvent system at different polarities. The plates were developed using 254 nm short-wave and 365 nm long-wave light. The phytochemical nuclei were identified by thin layer spray with specific reagents for alkaloids, flavonoids, terpenes, phenols and coumarins (Table 1).

Evaluation of the antimicrobial activity of extracts and fractions. Study strains

The *A. excelsum* leaf and stem extracts, and the fractions from the hydroalcoholic leaf extract were evaluated on the reference strains *Streptococcus mutans* ATCC 25175, *Staphylococcus aureus* ATCC 35548, *Escherichia coli* ATCC 25922, *Enterococcus faecalis* ATCC 19433 and *Candida albicans* ATCC 10231. These were lyophilized strains, preserved by freezing at -70°C at the Microbiology Laboratory of the Center for Dental Research of the Pontificia Universidad Javeriana. The microorganisms were reconstituted and made viable in 5 mL of brain heart infusion (BHI) broth and incubated for 24 hours at 37 °C under anaerobic conditions (H_2:CO_2:N_2 10:10:80). Then, for isolation and viability and purity testing, they were plated on BHI agar (Brain-Heart Infusion Agar) and incubated for 1-3 days at 37 °C under anaerobic conditions (H_2:CO_2:N_2 10:10:80). Finally, the colonies grown on BHI agar were reconfirmed using Gram stain and biochemical tests.

Well-diffusion method

Antibacterial activity was identified using the agar well diffusion method on Mueller-Hinton agar, as described in Dobner *et al.*[19]. Suspensions of each fresh, viable bacterial strain were prepared in isotonic saline solution and adjusted to 0.5 on the McFarland scale. Each bacterial suspension was immediately swabbed on Mueller-Hinton agar, following the Kirby-Bauer technique[20]. After plating all the bacteria on Mueller-Hinton Agar, a 0.5 cm Pasteur pipette was used to make wells (distributed

Table 1. Phytochemical nuclei studied in extracts and fractions obtained from *Anacardium excelsum*.

Phytochemical nuclei		Positive standard	Chemical developer
Alkaloids		Caffeine and Quinine	Dragendorff
Flavonoids		Rutin	$Pb(C_2H_3O_2)_2$ 25 %
Terpenes	Triterpenes	Turpentine	Vanillin – H_3PO_4 (H_3PO_4)
	Steroids	Cholesterol	$SbCl_3$ /$CHCl_3$ y CH_3COOH
Phenols and Tannins		Catechol (phenol)	$FeCl_3$ 5 % in HCl 0.5 N – ($FeCl_3$)
Coumarins (ortho-hydroxy)			Benedict

evenly on the agar). Then, 30 µL of the extracts, fractions, and positive and negative controls were placed in their corresponding wells. For each fraction (ethyl acetate, acetone, ethanol and water), concentrations of 2, 5, 10, 20 and 40 mg/ml were evaluated to determine the lowest concentration that inhibits bacterial growth. Negative control was 1% dimethyl sulfoxide (DMSO) and positive controls were 150 ug/ml vancomycin and 0.12% chlorhexidine. All tests were performed in duplicate and incubated at 37 °C for 24-48 hours. Following the incubation period, the diameters of the zones of inhibition were measured in millimeters and the two values averaged.

RESULTS

Chromatographic analysis

Table 2 shows the phytochemical nuclei studied in the fractions obtained from the hydroalcoholic extract of *Anacardium excelsum* leaves. Of the phytochemical nuclei studied, in the ethyl acetate (Fig. 1) and acetone fractions, only presence of phenols and tannins, as well as triterpene-type terpenes and steroidal terpenes, was identified. For the ethanol fraction, evaluation showed the presence of phenolic-type compounds and absence of alkaloids, flavonoids, terpenes and coumarins. In the fraction with highest polarity (aqueous), only presence of alkaloids, phenolic-type compounds, tannins and triterpene-type terpenes was found. Coumarins and flavonoid-type compounds were not found in any of the four fractions studied.

Antimicrobial activity of extracts

Table 3, parts A and B, show the antimicrobial activity of the *A. excelsum* extracts and fractions on the five microorganisms used in the study. Leaf extract had antimicrobial activity on *S. mutans, S. aureus, E. faecalis* and *C. albicans,* from concentrations of 10 mg/mL to 40 mg/ml, with zones of inhibition of 9 to 11 mm. None of the leaf extract concentrations evaluated inhibited *E. coli*. None of the stem extract concentrations evaluated inhibited *S. mutans*, *E. coli* or *C. albicans*, though they did inhibit *E. faecalis* at concentrations of 10 mg/mL to 40 mg/ml, with zones of inhibition of 11 mm; and *S. aureus* only at 40 mg/mL, with a zone of inhibition of 10 mm.

Antimicrobial activity of leaf extract fractions

Based on its antimicrobial activity on these bacteria, the leaf extract was fractionated and the antimicrobial activity of the resulting fractions assessed. The fractions with greatest inhibitory activity were ethyl acetate and acetone, which inhibited all study microorganisms as from concentrations of 10 mg/ml with zones of inhibition ranging from 9 to 20 mm (Table 3 and Fig. 2). The ethyl acetate fraction inhibited all microorganisms at concentrations of 10, 20 and 40 mg/ml with zones of inhibition of 9 to 15 mm. The acetone fraction inhibited *S. mutans, E. faecalis* and *C. albicans* at concentrations of 10, 20 and 40 mg/ml with zones of inhibition of 10 to 14 mm, and inhibited *S. aureus* and *E. coli* only at concentrations of 20 and 40 mg/ml, with zones of inhibition of 9 to 20 mm. In general, the other two fractions (ethanol and aqueous) showed less activity on the 5 microorganisms evaluated. Table 3 also shows the inhibition results produced by the positive controls (chlorhexidine 0.12% and vancomycin 150 ug/ml) and negative control (DMSO 1%).

DISCUSSION

Due to its wide range of plant biodiversity, and favored by its geographic location, Colombia holds great promise for the discovery and development of new substances with pharmacological potential[10]. It is well known that secondary metabolites derived from plant species have shown therapeutic

Table 2. Results of the evaluation of the phytochemical nuclei present in *A. excelsum* fractions.

Phytochemical nuclei and developing reagent		Fractions			
		Ethyl Acetate	Acetone	Ethanol	Water
Alkaloids (Dragendorff)		Negative	Negative	Negative	Positive
Flavonoids (Lead Acetate 25%)		Negative	Negative	Negative	Negative
Terpenes	Triterpenes (Vanillin – H3PO4)	Positive	Positive	Negative	Positive
	Steroids (SbCl3/Chloroform and acetic acid)	Positive	Positive	Negative	Negative
Phenols and Tannins (5% Iron (III) chloride in HCl 0.5 N - FeCl3)		Positive	Positive	Positive	Positive
Coumarins (ortho-hydroxy) (Benedict)		Negative	Negative	Negative	Negative

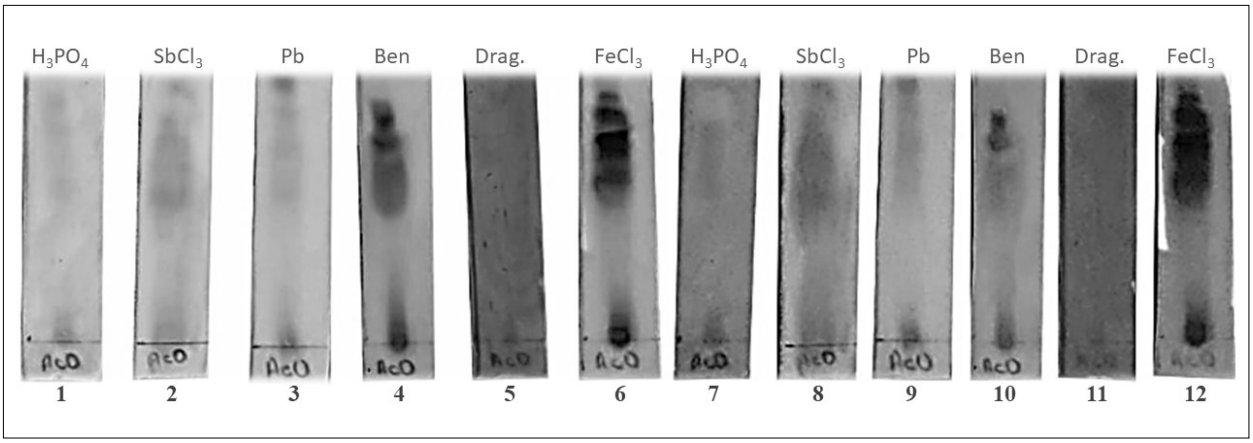

Fig. 1: Results obtained for phytochemical nuclei on TLC plates for the ethyl acetate fraction. Plates 1 to 6 (developed with UV light at 254 nm) and plates 7 to 12 (observed with specific developers). Presence of triterpene-type terpene nuclei (plates 1 and 7), steroidal terpenes (plates 2 and 8) and phenolic compounds (plates 6 and 12), and absence of coumarins (plates 4 and 10), flavonoids (plates 3 and 9) and alkaloids (plates 5 and 11).

action against various diseases[21]. Thus, different plant species have been studied to determine the presence of substances with pharmacological activity, including, among others, *Berberis goudotii, Isertia laevis*, *Borrichia frutences*, *Sarcocephalus coadunatus, Elaeagia utilis* and *Stevia rebaudiana*, with the aim of broadening the antimicrobial arsenal used to treat diseases of interest to public health, such as infectious diseases of the oral cavity[11, 12, 22, 23]. The current study evaluated the antimicrobial activity of hydroalcoholic extracts of leaves and stems, as well as fractions derived from the leaf extract, of the plant species *Anacardium excelsum*, which is endemic to Colombia. Celis et al.[18] conducted *in vitro* studies which showed that *A. excelsum* extracts inhibited the growth of Gram-positive bacteria such as *Staphylococcus aureus* and *Bacillus subtillis,* but showed no activity against Gram-negative bacteria such as *Escherichia coli* and *Salmonella*[18].

The results of the current study clearly showed that of the two extracts evaluated, leaf extract had more antimicrobial activity on the microorganisms evaluated at concentrations of 10, 20 and 40 mg/ml. For this reason, the leaf extract was fractionated using four solvents (ethyl acetate, acetone, ethanol and water) and concentrations of 2 mg/ml, 5 mg/ml, 10 mg/ml, 20 mg/ml and 40 mg/ml. The ethyl acetate fraction had the greatest antimicrobial activity, followed by the acetone fraction and, to a lesser degree, the ethanol and water fractions. The ethyl acetate and acetone fractions had antimicrobial activity at concentrations of 10, 20 and 40 mg/ml.

Outstanding was the high inhibition of the ethyl acetate fraction at concentrations of 10, 20 and 40 mg/ml on *C. albicans*, *E. faecalis* and *S. aureus* with zones of inhibition of 13.5 to 15 mm, and lower inhibition on *S. mutans* and *E. coli*, with zones of inhibition of 9 mm to 11 mm. In general, the

Table 3. Part A. Antimicrobial activity of *A. excelsum* leaf and stem hydroalcoholic extracts and fractions derived from the hydroalcoholic extract of leaves against *S. mutans* ATCC 25175, *S. aureus* ATCC 35548 and *E. coli* ATCC 25922. Zones of inhibition expressed in mm for averages of duplicate tests.

Microorganism	*S. mutans* ATCC 25175					*S. aureus* ATCC 35548					*E. coli* ATCC 25922				
Concentrations of the product in mg/ml	2	5	10	20	40	2	5	10	20	40	2	5	10	20	40
Leaf extract	0	0	9	9.5	9.5	0	0	9	9	11	0	0	0	0	0
Stem extract	0	0	0	0	0	0	0	0	0	10	0	0	0	0	0
Ethyl acetate fraction	0	0	9	10	11	0	0	13.5	13.5	15	0	0	9	9	9
Acetone fraction	0	0	10	10	10	0	0	0	20	10	0	0	0	9	10
Ethanol fraction	0	0	0	0	0	0	0	0	9	10	0	0	0	0	0
Water fraction	0	0	0	0	0	0	0	0	9	10	0	0	0	0	9
Positive control: Chlorhexidine 0.12%	19	19	19	19	19	18	18	18	18	18	18.8	18.8	18.8	18.8	18.8
Positive control: Vancomycin (150 ug/ml)	17.8	17.8	18	18	18	18	18	18	18	18	0	0	0	0	0
Negative control: DMSO 1%	0	0	0	0	0	0	0	0	0	0	0	0	0	0	0

Table 3. Part B. Antimicrobial activity of *A. excelsum* leaf and stem hydroalcoholic extracts and fractions derived from the hydroalcoholic extract of leaves against *E. faecalis* ATCC 19433, and *C. albicans* ATCC 10231. Zones of inhibition expressed in mm for averages of duplicate tests.

Microorganism	*E. faecalis* ATCC 19433					*C. albicans* ATCC 10231				
Concentrations of the product in mg/ml	2	5	10	20	40	2	5	10	20	40
Leaf extract	0	0	10	10	10	0	0	10	10	11
Stem extract	0	0	11	11	11	0	0	0	0	0
Ethyl acetate fraction	0	0	14	14	14	0	0	14.5	15	15
Acetone fraction	0	0	9	11	11	0	0	10	11	14
Ethanol fraction	0	0	9	11	11	0	0	0	9	10
Water fraction	0	0	9	10	10	0	0	0	9	10
Positive control: Chlorhexidine 0.12%	16.5	16.5	16.5	16.5	16.5	20	20	20	20	20
Positive control: Vancomycin (150 ug/ml)	19.3	19.3	19.3	19.3	19.3	0	0	0	0	0
Negative control: DMSO 1%	0	0	0	0	0	0	0	0	0	0

microorganism least inhibited by the 4 fractions was *E. coli,* in agreement with Celis et al.[18].

In the current study, the two most active fractions (ethyl acetate and acetone) obtained from *A. excelsum* leaves behaved chemically in the same way, with compounds only of phenolic type, tannins, triterpene-type terpenes and steroidal-type terpenes. Celis et al.[18] suggest that the antimicrobial activity of these two fractions against the study microorganisms was due to the presence of these phytochemical nuclei. Celis et. al [18] identified that the compounds 2- (1,1-dimethylethyl) -4- (1,1,3,3-tetramethylbutyl) phenol and 2,2'-methylenebis (6- (1,1-dimethylethyl) -4-ethyl-phenol, characterized by gas chromatography–mass spectrometry (GC/MSD), present in medium-polarity fractions of *A. excelsum*, had powerful antimicrobial and antiseptic properties, and thus, excellent antimicrobial activity due to their biological potential[18].

The current study found presence of terpenes and phenols in the ethyl-acetate and acetone fractions.

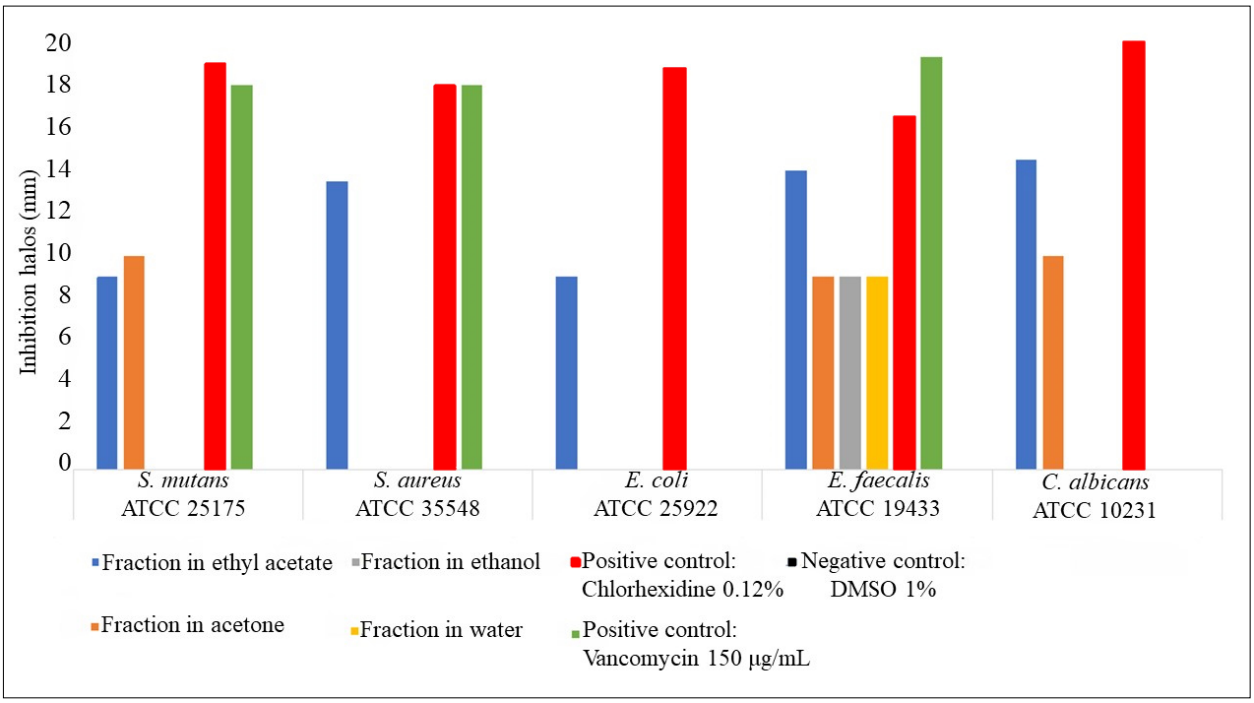

Fig. 2: Antimicrobial action of the fractions of A. excelsum leaf hydroalcoholic extracts at concentration of 10 mg/mL on the 5 study microorganisms.

Other studies have found that terpenes are important components that produce antimicrobial activity in species of the family Rubiaceae, and that phenols and phenolic acids are the main components in plants with antimicrobial activity[24, 25].

Urrea et al.[14] assessed the antibacterial activity of extracts from *A. excelsum*, and using gas chromatography, identified the compounds oleic acid, octadecanoic acid; 9-octadecenoic acid; 2-methyl-3(Z), 13(Z)-octadecadienol; 2-hydroxy-1-(hydroxymethyl)ethyl-9(Z), 12(Z)-octadecadienoate; 6(Z)-octadecenoic acid; 9(Z)-octadecenal and 7(Z),11(E)-hexadecadienal acetate; 1-isopropyl-4-methyl-benzene; 4-isopropenyl-1-methylcyclohexil acetate and 3-pentadecylphenol, with chemical characteristics that generated strong antimicrobial potential[14]. The results of the current study showed, in low polarity fractions (ethyl acetate and acetone), the presence of phytochemical nuclei which may contain the compounds described by Urrea et al.[14] and show the antimicrobial activity presented against the study microorganisms. Moreover, the ability of these compounds to provide protection to plants has been clearly demonstrated, thus, it is necessary to continue with the chemical characterization of the phytochemical nuclei in order to identify and characterize substances with potential antimicrobial activity.

The antimicrobial activity of *A. excelsum* found in the current study on reference ATTC strains of *S. mutans, S. aureus, E. coli*, *E. faecalis* and *C. albicans*, which are microorganisms which have been demonstrated to by highly pathogenic in different infectious processes of the oral cavity[2, 3], makes it clear that *A. excelsum* (Caracolí) leaves are a potential source of chemical compounds with antibacterial activity. It is thus necessary to conduct further studies to elucidate the action mechanism of these extracts and fractions, providing information on the content of secondary metabolites with antibacterial and antifungal activity, which –after evaluating pharmacological safety– could be used in the future as antimicrobial agents for infectious processes of the oral cavity.

To conclude, (1) the hydroalcoholic extract of *A. excelsum* leaves and the ethyl acetate and acetone fractions obtained from the hydroalcoholic extract at concentrations of 10 to 40 mg/ml had the greatest antimicrobial activity against *S. mutans* ATCC 25175*, S. aureus* ATCC 35548*, E. coli* ATCC 25922, *E. faecalis* ATCC 19433 and *C. albicans* ATCC 10231; and (2) the evaluation of the phytochemical nuclei in the ethyl acetate and acetone fractions showed compounds of phenolic type, triterpene-type terpenes and steroidal-type terpenes, which might explain the antimicrobial activity observed.

ACKNOWLEDGMENTS
The authors thank the Herbarium of Universidad del Quindío (HUQ) for active collaboration with the Project, the School of Dentistry and the Office of the Vice-Rector of Science, Technology and Research of Universidad Antonio Nariño, Armenia (Quindío), and the Department of Microbiology (School of Science) and Center of Dental Research (School of Dentistry) of Pontificia Universidad Javeriana, Bogotá, D.C.

DECLARATION OF CONFLICTING INTERESTS
The authors declare no potential conflicts of interest regarding the research, authorship, and/or publication of this article

FUNDING
Research funding from the Office of the Vice-Rector of Science, Technology and Research of Universidad Antonio Nariño, Armenia (Quindío), and co-funding from the Department of Microbiology (School of Science) and Center for Dental Research (School of Dentistry) of Pontificia Universidad Javeriana, Bogotá, D.C.

CORRESPONDENCE
Dr. Fredy Gamboa
Departamento de Microbiología
Facultad de Ciencias, Pontificia Universidad Javeriana
Carrera 7 No. 40-62, Bogotá, Colombia
gamboa@javeriana.edu.co

REFERENCES

1. Ogle OE. Odontogenic Infections. Dent Clin North Am 2017 ; 61:235-252.
2. Arweiler NB, Netuschil L. The Oral Microbiota. Adv Exp Med Biol 2016; 902:45-60.
3. Li X, Kolltveit KM, Tronstad L, Olsen I. Systemic diseases caused by oral infection. Clin Microbiol Rev 2000 ; 13:547-558.
4. Tent PA, Juncar RI, Onisor F, Bran S, Harangus A, Juncar M. The pathogenic microbial flora and its antibiotic susceptibility pattern in odontogenic infections. Drug Metab Rev 2019; 51:340-355.
5. Lemos JA, Palmer SR, Zeng L, Wen ZT, Kajfasz JK, Freires IA, Abranches J, Brady LJ. The Biology of *Streptococcus mutans*. Microbiol Spectr 2019;7:10.1128/microbiolspec.GPP3-0051-2018.
6. McCormack MG, Smith AJ, Akram AN, Jackson M, Robertson D, Edwards G. *Staphylococcus aureus* and the oral cavity: an overlooked source of carriage and infection? Am J Infect Control 2015 ; 43:35-37.
7. Walia IS, Borle RM, Mehendiratta D, Yadav AO. Microbiology and antibiotic sensitivity of head and neck space infections of odontogenic origin. J Maxillofac Oral Surg 2014 ; 13:16-21.
8. Ardizzoni A, Pericolini E, Paulone S, Orsi CF, Castagnoli A, Oliva I, Strozzi E, Blasi E. In vitro effects of commercial mouthwashes on several virulence traits of *Candida albicans*, *Viridans streptococci* and *Enterococcus faecalis* colonizing the oral cavity. PLoS One 2018 15; 13:e0207262.
9. Bertolini M, Dongari-Bagtzoglou A. The Relationship of *Candida albicans* with the Oral Bacterial Microbiome in Health and Disease. Adv Exp Med Biol 2019; 1197:69-78.
10. Rojas JJ, Ochoa VJ, Ocampo SA, Muñoz JF. Screening for antimicrobial activity of ten medicinal plants used in Colombian folkloric medicine: a possible alternative in the treatment of non-nosocomial infections. BMC Complement Altern Med 2006 ; 6:2.
11. Téllez N, Téllez M, Perdomo M, Alvarado A, Gamboa F. Anticariogenic activity of the active fraction from *Isertia laevis* against *S. mutans* and *S. sobrinus*: comparison of two extraction methods. Acta Odontol Latinoam 2010; 23:188-195.
12. Aldana J, Tellez N, Gamboa F. Antimicrobial activity of fractions and subfractions of *Elaeagia utilis* against microorganisms of importance in dental caries. Acta Odontol Latinoam 2013; 26:104-111.
13. Abouelhassan Y, Garrison AT, Yang H, Chávez-Riveros A, Burch GM, Huigens RW 3rd. Recent Progress in Natural-Product-Inspired Programs Aimed To Address Antibiotic Resistance and Tolerance. J Med Chem 2019 ; 62:7618-7642.
14. Urrea-Victoria V, Sequeda-Castañeda L. Evaluation of extracts of *Anacardium excelsum* (Anacardiaceae) as alternative to the food preservation. Vitae 2012; 19:394-396
15. de Araújo JSC, de Castilho ARF, Lira AB, Pereira AV, de Azevêdo TKB, de Brito Costa EMM, Pereira MDSV, et al. Antibacterial activity against cariogenic bacteria and cytotoxic and genotoxic potential of *Anacardium occidentale* L. and *Anadenanthera macrocarpa* (Benth.) Brenan extracts. Arch Oral Biol 2018 ; 85:113-119.
16. Dos Santos GHF, Amaral A, da Silva EB. Antibacterial activity of irradiated extracts of *Anacardium occidentale* L. on multiresistant strains of *Staphylococcus aureus*. Appl Radiat Isot. 2018; 140:327-332.
17. Barbosa-Filho VM, Waczuk EP, Leite NF, Menezes IR, da Costa JG, Lacerda SR, Adedara IA, Coutinho HD, et al. Phytocompounds and modulatory effects of *Anacardium microcarpum* (cajui) on antibiotic drugs used in clinical infections. Drug Des Devel Ther 2015 ; 9:5965-5972.
18. Celis C, García A, Sequeda G, Méndez G, Torrenegra R. Antimicrobial activity of extracts obtained from *Anacardium excelsum* againts some pathogenic microorganisms. Emir J Food Agric 2011; 23 : 249-257.
19. Dobner M, Schwaiger S, Jenewein I, Stuppner H. Antibacterial activity of *Leontopodium alpinum* (Edelweiss). J Ethnopharmacol 2003; 89:301-303.
20. Bauer AW, Kirby WM, Sherris JC, Turck M. Antibiotic susceptibility testing by a standardized single disk method. Am J Clin Pathol. 1966; 45:493-496.
21. Pinto D, Thomas A, Tabares T, Tenorio SF, Diaz C, BrazFilho R, Dacunha VL. Secondary metabolites isolated from *Richardia brasiliensis* (Rubiaceae). Braz J Pharmacol 2008; 18:367-372.
22. Sequeda-Castañeda LG, Muñoz-Realpe CC, Celis-Zambrano CA, Gutiérrez-Prieto SJ, Luengas-Caicedo PE, Gamboa F. Preliminary Phytochemical Analysis

of *Berberis goudotii* Triana & Planch. ex Wedd. (Berberidaceae) with Anticariogenic and Antiperiodontal Activities. Sci. Pharm. 2019, 87, 2; https://doi.org/10.3390/scipharm87010002 .

23. Gamboa F, Chaves M. Antimicrobial potential of extracts from *Stevia rebaudiana* leaves against bacteria of importance in dental caries. Acta Odontol Latinoam 2012; 25:171-175.
24. Kloucek P, Polesny Z, Svobodova B, Vlkova E, Kokoska L. Antibacterial screening of some Peruvian medicinal plants used in Calleria District. J Ethnopharmacol 2005; 99:309-312.
25. Cowan MM. Plant products as antimicrobial agents. Clin Microbiol Rev 1999;12:564-582.

Clinical evaluation of root coverage using coronally positioned flap associated with acellular dermal matrix allograft in single-type recession defects. A retrospective study

Guillermo Schinini[1,2], Alessia Molinari[1], Hugo Romanelli[1]

1. Universidad Maimónides, Carrera de Especialización en Periodoncia, Buenos Aires, Argentina
2. Práctica Privada, Rosario, Argentina

ABSTRACT

The aim of this study was to conduct a retrospective assessment of the clinical results at 6,12 and 24 months of root coverage in single gingival recessions using coronally positioned flap and acellular dermal matrix allograft.

Clinical records were collected from 16 patients with single gingival recessions who visited a private practice in Periodontics in 2005 and 2006. They were treated through a coronally positioned flap and acellular dermal matrix allograft. The following periodontal parameters were recorded at baseline, 6, 12 and 24 months: Recession Depth, Recession Width, Probing Depth, Clinical Attachment Level, Keratinized Tissue Width, Plaque Index, Gingival Index and Sensitivity.

The percentage of root coverage was 91.18 ± 21.26 at 6 months, 90.18 ± 22.04 at 12 months and 90.83 ± 18.41 at 24 months. Complete root coverage was 81% (13 out of 16) at 6 and 12 months. At 24 months, complete root coverage was 75% (9 out of 12). The plaque and gingival indexes did not vary significantly between baseline and measurement times. Probing depth was maintained at healthy levels during the months of follow-up. Sensitivity decreased at 12 months (4 of 16) compared to baseline (14 of 16), and was maintained at 2 years (2 of 12).

This retrospective study showed that acellular dermal matrix allograft could be considered a useful alternative for the treatment of single gingival recessions, reducing the discomfort and morbidity associated with the palatal donor site.

Received: April 2021; Accepted: June 2021.

Keywords: *acellular dermal tissue - alloderm - gingival recession - allografts.*

Evaluación clínica del recubrimiento radicular mediante colgajo desplazado coronal asociado a injerto dérmico acelular en recesiones únicas. Estudio retrospectivo

RESUMEN

El objetivo de este trabajo fue evaluar retrospectivamente los resultados clínicos del recubrimiento radicular en recesiones únicas mediante el uso de colgajo desplazado coronal y matriz dérmica acelular a los 6,12 y 24 meses.

Se recolectaron las historias clínicas de 16 pacientes que presentaban recesiones gingivales únicas, concurrentes a un consultorio privado de Periodoncia en los años 2005 y 2006. Fueron tratados utilizando colgajo desplazado coronal y matriz dérmica acelular. Previamente se registraron los siguientes parámetros periodontales: Altura de la recesión, Ancho de la recesión, Profundidad al sondaje, Nivel Clínico de inserción, Ancho del tejido queratinizado, Indice de placa, Indice gingival y Sensibilidad. Los datos se obtuvieron nuevamente a los 6, 12 y 24 meses.

El porcentaje de recubrimiento radicular obtenido a los 6 meses fue de 91,18 ± 21,26, de 90,18 ± 22,04 a los 12 meses y 90,83 ± 18,41 a los 24 meses. La cobertura radicular completa fue de 81% (13 de 16) a los 6 y 12 meses, y fue de 75% a los 24 meses (9 de 12). Los índices de placa y gingival no variaron significativamente entre el inicio y los diferentes intervalos de tiempo. La profundidad al sondaje se mantuvo en niveles compatibles con salud durante los meses de seguimiento. Se logró disminuir la sensibilidad a los 12 meses (4 de 16) respecto al inicio del tratamiento (14 de 16), manteniendo dicha proporción a los 2 años (2 de 12). El presente estudio retrospectivo mostró que el uso de la matriz dérmica acelular podría ser considerado una alternativa predecible para el tratamiento de recesiones gingivales únicas, reduciendo el disconfort y la morbilidad asociada al sitio donante palatino.

Palabras clave: *matriz dérmica acelular - alloderm - recesión gingival - injerto.*

INTRODUCTION

Gingival recession is defined as the apical displacement of the gingival margin with respect to the cementoenamel junction. It is a highly prevalent mucogingival condition worldwide, occurring both in individuals with good and with inadequate oral hygiene[1]. Gingival recession can be localized or involve several teeth, and the ensuing root exposure is associated with an increase in dentin sensitivity, greater susceptibility to root decay, difficulty in removing the biofilm and aesthetic alterations[2]. Recent scientific evidence has shown that untreated gingival recession defects are more likely to progress over time, even with good oral hygiene[3,4].

Several techniques have been described to achieve root coverage in single gingival recessions, with the connective tissue graft associated with the coronally positioned flap (CPF) being considered the Gold Standard among all possible variants[5]. The ultimate aim of the procedure is to obtain maximum root coverage of the recession treated at the level of the cementoenamel junction, minimum residual probing depth, and excellent gingival camouflage with respect to neighboring tissues without leaving scars or unaesthetic contour and texture alterations in the surrounding tissues.

However, there are certain situations in which it is not always possible to obtain a palatal connective tissue graft, due to the scarce or null amount of donor tissue in the palatal area (little palatal thickness and/or little availability for long grafts, absence of premolar/s in patients with limited opening and flat palate), or when the patient refuses the intervention of a second surgical site that generates greater postoperative morbidity[6]. To solve the problem caused by the limited availability of the graft, there are human or animal substitutes, among them the acellular dermal matrix allograft (ADMA, Alloderm, BioHorizons, Birmingham, AL, USA) which has been used for more than two decades as a substitute for connective tissue in the treatment of gingival recessions, gingival augmentation around teeth and implants and as a barrier in regenerative procedures[7,8].

This human graft is a non-cellular connective tissue whose cellular content is eliminated through a manufacturer's patented process which preserves the extracellular matrix ultrastructure integrity, allowing the collagen and elastin matrix to be repopulated with new cells and blood vessels without generating an inflammatory response in host tissues[9]. It has a smoother side that does not impregnate with blood (basal lamina) which fosters epithelial migration and a rough side (embedded with the blood of the receptor site), enabling growth of fibroblasts and angiogenic cells. ADMA acts as a non-immunogenic matrix which enables tissue regeneration through cell repopulation and revascularization rather than through a granulation process[10].

The main advantage in the use of connective tissue graft substitutes is the unlimited availability of donor material, especially useful for the treatment of many teeth or complete arches; and at the same time avoiding the need for a second surgical site, reducing patient morbidity and discomfort in the palatal area.

The objective of this retrospective study is to evaluate the clinical results of root coverage in single gingival recessions using CPF and ADMA at 6, 12 and 24 months.

MATERIALS AND METHODS

The clinical records of patients with single gingival recessions who attended a private practice in Periodontics in 2005 and 2006 were analyzed retrospectively. Sixteen patients (13 female and 3 male) with mean age 32.6 ± 7.3 years (range 21-49) were treated. Thirteen were non-smokers, 3 smokers of less than 5 cigarettes per day, all without systemic alterations and showing single gingival recessions (Miller Class I / TR1 Cairo[11,12]) in the upper and lower dental arches. The risks and benefits related to the surgical procedure were explained before patients signed the informed consent. The informed consents are preserved in the dental office files. Ten upper canines, 4 upper premolars, 1 upper lateral incisor and one lower premolar with dentin sensitivity and aesthetic alterations were treated.

Scaling and root planing were performed using ultrasonic and manual curettes, and polishing with a non-abrasive paste. A soft brush and interdental aids were indicated together with oral hygiene instructions (Roll Technique). The following parameters were evaluated at baseline, 6, 12 and 24 months: Recession Depth (RD), Recession Width (RW), Probing Depth (PD), Clinical Attachment Level (CAL), Keratinized Tissue Width (KTW), Plaque Index[13] (PI), Gingival Index[13] (GI) and Sensitivity[14] (SENS). Four patients did not attend the 2-year evaluation. All these measurements were

performed by the same operator (G.S.) using a PCP UNC-15-millimeter probe (Hu-Friedy®). KTW was measured after topical application of Schiller's iodine solution (Table 1).

After anesthetizing the area, careful scaling and root planning of the exposed root surface and the subgingival portion corresponding to the probing depth of each tooth was performed using 1/2 Mini-Five (Hu-Friedy®) curettes and ultrasonic devices, without chemical root conditioning (Fig. 1a).

Detailed description of surgical protocol has been published previously[15]. Briefly, intra-sulcular and horizontal incisions extending to the cementoenamel junctions of the adjacent teeth and two oblique releasing incisions exceeding the mucogingival line were made. A partial-full-split thickness flap was raised by sharp dissection.

The anatomical papillae were de-epithelialized using a 15C scalpel and micro-scalpel (Swann Morton®) (Fig. 1b). ADMA (Alloderm®, BioHorizons, Birmingham, AL, USA) was used, which was previously immersed in two containers of saline solution for 20 minutes to hydrate it, according to the manufacturer's instructions. The allograft was cut to the shape and size of the sites to be covered and oriented with the rough surface (corresponding to the connective side) towards the internal face of the flap, which was finally sutured with 5-0 Chromic Catgut sling suture (Hu-Friedy®) at the level of the cementoenamel junction of each tooth (Fig. 1c). Apically, the matrix was extended 3 mm over the bone. Subsequently, the flap was displaced coronally and sutured beyond the ADMA with Polytetrafluoroethylene suture (PTFE, Cytoplast® 5-0), such that non allograft was left exposed to the oral environment (Fig.1d).

Postoperative Care: Patients were instructed not to brush or floss the area for 3 weeks, and to rinse with 0.12% chlorhexidine digluconate twice a day until hygiene techniques were resumed. Analgesics were prescribed for a week (Flurbiprofen 100 mg every 12 h) and antibiotics for 7 days (Amoxicillin 875 mg every 12 h). The sutures were removed 2 weeks after surgery. After a month, mechanical hygiene was resumed using a soft-bristle brush and a sweeping technique (Roll Technique). The healing of the periodontal surgeries proceeded without complications. All parameters were reevaluated at 6, 12 and 24 months (Figs. 1e,1f, 1g).

Table 1. Preclinical conditions

CASE	TOOTH	PD (mm)	CAL (mm)	RD (mm)	RW (mm)	KTW (mm)
1	24	2.0	5.0	3.0	3.5	3.0
2	23	1.5	6.5	5.0	5.0	1.0
3	14	1.0	4.5	3.5	4.0	2.5
4	44	1.5	4.5	3.0	3.5	2.0
5	23	2.0	4.0	2.0	4.0	3.0
6	22	1.0	3.0	2.0	3.0	2.0
7	13	0.5	4.5	4.0	4.0	1.0
8	23	1.0	4.0	3.0	5.0	2.0
9	14	2.0	4.0	2.0	3.0	3.0
10	23	1.5	3.5	2.0	6.0	2.5
11	13	1.0	3.0	2.0	3.5	4.0
12	13	1.0	4.5	3.5	4.0	3.0
13	13	1.0	4.0	3.0	4.0	4.0
14	23	1.5	4.5	3.0	5.0	2.0
15	23	1.5	4.0	2.5	3.5	3.0
16	14	1.0	4.0	3.0	3.0	2.0
X(SD)		1.3(0.4)	4.2(0.8)	2.9(0.8)	4(0.8)	2.5(0.9)

PD: Pocket depth; CAL: Clinical attachment level; RD: Recession depth; RW: Recession width; KTW: Keratinized tissue width, X(SD): Mean (Standard Deviation)

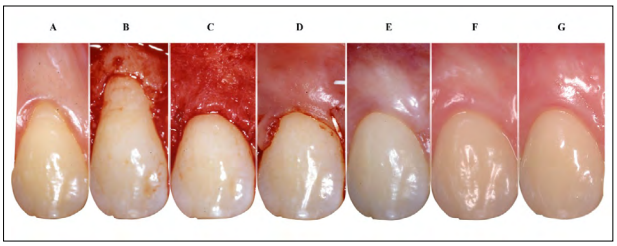

Fig.1: a- Baseline gingival recession. b- Partial/full/partial flap and de-epithelialized papillae. c- Allograft is sutured to the recipient bed. d- Coronally positioned flap. e- Postoperative appearance at 6 months. f- Postoperative appearance at 1 year. g- Postoperative appearance at 2 years.

RESULTS

PI and GI did not vary significantly between baseline and 24 months. PD was 1.31 ± 0.44 at baseline and remained at levels compatible with health during follow-up (1.25 ± 0.40 at 6 months, 1.18 ± 0.35 at 12 months, and 1.29 ± 0.39 at 24 months). Considering the average values, the CAL gain at 24 months was 2.7 mm. On the other hand, there was a keratinized gingiva gain of 0.8 mm between baseline and two years.

RD decreased from 2.90 ± 0.84 (baseline), to 0.28 ± 0.68 (6 months), 0.31 ± 0.70 (12 months) and 0.33 ± 0.65 (24 months), obtaining a Root Coverage percentage (% RC) of 91.18 % at 6 months, 90.18%

at 12 months and 90.83% at 24 months. 81% Complete Root Coverage (CRC) was obtained at 6 and 12 months (13 of 16). At 24 months, the CRC was 75% (9 of 12) (Table 2, Table 3, Fig. 2).

Individual analysis of cases per year showed that of the 16 cases evaluated, 13 presented complete coverage of the gingival recession (81% of the sites). Of those that did not have CRC, one case had 86% RC and 2 cases obtained 43% and 33% RC, respectively. At 24 months, of the 12 cases that had achieved 100% RC, 8 remained stable, 3 did not attend the follow-up visit and one presented a mild gingival recession relapse (85% RC). Of the

Table 2. Clinical parameters at baseline, 6, 12 and 24 months

	0	6	12	24	0	6	12	24	0	6	12	24	0	12	24
	RD (mm)				**RW (mm)**				**KTW (mm)**				**SENS (Y/N)**		
1	3	0.5	1	1	3.5	1.5	2	3	3	3.5	3.5	3.5	Y	N	N
2	5	0	0	1	5	0	0	3	1	3	2	2	Y	Y	Y
3	3.5	2	2	2	4	4	4	4	2.5	3	3	3	N	Y	N
4	3	0	0	0	3.5	0	0	0	2	3	3.5	3.5	Y	N	N
5	2	0	0	L	4	0	0	L	3	4	4	L	Y	N	L
6	2	0	0	0	3	0	0	0	2	4	4	4	Y	N	N
7	4	0	0	0	4	0	0	0	1	3	3	3	Y	N	N
8	3	0	0	0	5	0	0	0	2	2	2	2	Y	N	N
9	2	0	0	L	3	0	0	L	3	4	4	L	Y	N	L
10	2	0	0	0	6	0	0	0	2.5	3.5	3	3	Y	N	N
11	2	0	0	0	3.5	0	0	0	4	5	5	5	Y	N	N
12	3.5	0	0	0	4	0	0	0	3	3	3	3	Y	N	N
13	3	0	0	L	4	0	0	L	4	4	5	L	Y	Y	L
14	3	2	2	L	5	4	4	L	2	3	3	L	N	N	L
15	2.5	0	0	0	3.5	0	0	0	3	4	4	4	Y	N	N
16	3	0	0	0	3	0	0	0	2	3.5	4	4	Y	Y	Y

RD: Recession depth; RW: Recession width; KTW: Keratinized tissue width; SENS: sensitivity; Y: Yes; N: No; L: lost to follow up

Table 3. Mean root coverage and complete root coverage at 6, 12 and 24 months

	MONTH	6	12	24	6	12	24
	# TOOTH	**RC (%)**			**CRC (Y/N)**		
1	24	83	67	67	N	N	N
2	23	100	100	80	Y	Y	N
3	14	43	43	43	N	N	N
4	44	100	100	100	Y	Y	Y
5	23	100	100	L	Y	Y	L
6	22	100	100	100	Y	Y	Y
7	13	100	100	100	Y	Y	Y
8	23	100	100	100	Y	Y	Y
9	14	100	100	L	Y	Y	L
10	23	100	100	100	Y	Y	Y
11	13	100	100	100	Y	Y	Y
12	13	100	100	100	Y	Y	Y
13	13	100	100	L	Y	Y	L
14	23	33	33	L	N	N	L
15	23	100	100	100	Y	Y	Y
16	14	100	100	100	Y	Y	Y
M%		91	81	91	81	81	75

RC: Root Coverage; CRC: Complete Root Coverage; L: Lost to follow-up; Y: Yes; N: No; M%: Mean percentage

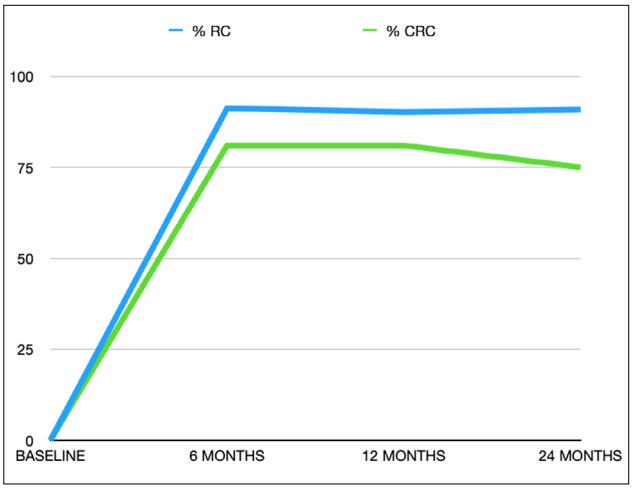

Fig. 2: Mean Root Coverage (% RC) and Complete Root Coverage (CRC) at 6, 12 and 24 months.

cases that did not achieve full coverage at one year, one did not attend the follow-up visits and the other two maintained the level of the gingival recession within the parameters reached in the first year. Sensitivity (SENS) was reduced at 12 months (4 of 16) compared to the start of treatment (14 of 16) and remained stable at 24 months (2 of 12).

DISCUSSION

ADMA has been considered a valid alternative to subepithelial connective tissue in different periodontal plastic surgery procedures. It has some advantages over other surgical procedures for the treatment of single and multiple gingival recessions. It does not require a second donor site, it allows for an unlimited amount of the material, as well as suitable camouflage with respect to the color and texture of the neighboring soft tissues. In turn, the material can be positioned and sutured on the receptor bed either on the connective side or the basement membrane side, without affecting the results of the treatment[16].

The use of ADMA associated with CPF has shown successful results in the treatment of single gingival recessions (Miller Class I and II / Cairo RT1), showing a high percentage of root coverage ranging from 70% to 95%, and a short-term increase in gingival thickness of 0.5mm to 0.7mm[17-22]. The increase in gingival thickness is considered an important factor to avoid recurrence of the lesion, since increasing the gingival phenotype counteracts the negative influence of traumatic brushing.

Based on short-term studies, the current study agrees with different publications in the literature in terms of gingival recession reduction, percentage of root coverage and increase of keratinized gingiva[18,20]. Our study achieved 91.19% root coverage at 6 months, 90.19% at 12 months, and 90.83% at 24 months. In addition, the percentage of complete root coverage was 81% at 6 months, remaining unchanged at one year. At 2 years, the CRC was reduced to 75%. Nowadays, the clinical evaluation of CRC must be accompanied by an aesthetic evaluation, i.e., achieving stable levels in the long term of gingival margins at the level of the cementoenamel junction as well as adequate texture, color and tissue contour[23].

The increase in KTW was 0.8 mm at 2 years. Other authors reported an increase in keratinized tissue between 0.4 mm and 1.2 mm at 12 months[19,20,22,24]. However, the cellular dynamics and keratinization process during healing using ADMA is not fully understood and its behavior as an inducer of keratinization needs further research[25].

Miller identified certain success criteria for root coverage procedures. Among them, he mentioned that the depth of the sulcus should be 2 mm or less without bleeding on probing[26]. At the beginning, the PD measurements were consistent with health and remained unchanged during the evaluated healing intervals. Similarly, PI and GI remained at low levels during the 24 months.

Dentin hypersensitivity is a frequent finding in patients with gingival recessions, with root coverage procedures being an alternative for its treatment. In this report, sensitivity was reduced from 87% before treatment (14 of 16) to 25% at one year (4 of 16) and 17% at 2 years (2 of 12). The presence of said postoperative residual sensitivity could be explained by the lack of CRC in 100% of the individuals at different times.

Several published studies related to single gingival recession coverage using ADMA and CPF provide short-term evaluation (≤ 12 months), and there is limited evidence with follow-up longer than 2 years. Harris reported a case series on 20 patients treated with ADMA and found that average root coverage was 91% at 3 months and 87% at 18 months[18]. In a short- and long-term retrospective study, Harris found that average root coverage was 93% at 3 months, decreasing to 70% at 48 months for multiple gingival recessions treated with ADMA and 50% in single gingival recessions[27]. These results suggest a worsening in long-term compared to short-term results. However, this author states that in 32% of the cases treated by ADMA and CPF, the results improved or remained stable over time.

In the current retrospective study, 3 out of 16 cases did not obtain CRC at 1 year; 2 of them were smokers, while the case that obtained the lowest percentage of root coverage (43%), corresponds to a non-smoker who inflicted toothbrush-trauma during the initial healing phase. At a 24-month evaluation of these 3 cases, 1 had dropped out of the study and in the other two, the gingival margin level reached at 12 months remained stable. Of the 13 cases that had achieved 100% RC at 1 year, 9 remained stable, 3 did not attend the follow-up visit and only one had a slight increase in gingival recession at the 24-month evaluation.

Although there is variability in the results obtained with the use of ADMA associated with the CPF for

the treatment of single gingival recessions, its use can be considered a valid alternative to connective tissue graft, due to the decrease in morbidity and discomfort, fewer complications and work-time in situ, unlimited availability of graft material and the possibility of full-arch treatments in the same session[28].

Due to the limitations of this study, the results should be considered with caution, since randomized controlled studies with a long-term follow-up period are needed to assess the stability of the outcomes reported herein.

CONCLUSION

The percentage of root coverage obtained was slightly higher than 90% and remained stable throughout the evaluation period. Complete root coverage was achieved in 81% of the cases at 6 and 12 months and 75% at 24 months. Acellular dermal matrix allograft is considered a useful alternative to the treatment of single and multiple gingival recessions, reducing discomfort and morbidity associated with the palatal donor site.

ACKNOWLEDGMENTS
We thank Dr. Mariel V. Gomez for reviewing the manuscript.

DECLARATION OF CONFLICTING INTERESTS
The authors declare no potential conflicts of interest regarding the research, authorship, and/or publication of this article.

FUNDING
None

CORRESPONDENCE
Dr Guillermo Schinini
Rioja 2625, 2000 Rosario
Pcia. Santa Fe, Argentina
guillermo.schinini@gmail.com

REFERENCES

1. Ishikawa I, McGuire M, Mealey B, Blieden T et al. Consensus Report: Mucogingival deformities and conditions around teeth. Ann Periodontol 1999;4:101.
2. Merijohn G. Management and prevention of gingival recession. Periodontology 2000, 2016;71:228-242.
3. Chambrone L, Tatakis DN. Long-term outcomes of untreated buccal gingival recessions. A systematic review and meta-analysis. J Periodontol 2016;87:796-808.
4. Agudio G, Cortellini P, Buti J, Pini Prato GP. Periodontal conditions of sites treated with gingival augmentation surgery compared with untreated contralateral homologous sites: An 18 to 35 year Long term study. J Periodontol 2016;87:1371-1378.
5. Chambrone L, Lima L, Pustiglioni F, Chambrone L. Systematic review of periodontal plastic surgery in the treatment of multiple recession-type defects. J Can Dent Assoc 2009,75:203a-f.
6. Chambrone L, Tatakis DN. Periodontal soft tissue root coverage procedures: a systematic review from the AAP Regeneration Workshop. J Periodontol 2015;86 (2 Suppl):S8-51. doi: 10.1902/jop.2015.130674.
7. Andrade P, Souza S, Macedo G, Novaes AB et al. Acellular dermal matrix as a membrane for guided tissue regeneration in the treatment of class II furcation lesions. J Periodontol 2007,78:1288-1299.
8. Borges G, Novaes AB, Grisi M, Palioto D et al. Acellular dermal matrix as a barrier in guided bone regeneration: a clinical, radiographic and histomorphometric study in dogs. Clin Oral Impl Res 2009;20:1105-1115.
9. Bohac M, Danisovic L, Koller J, Dragunova J et al. What happens to an acellular dermal matrix after implantation in the human body? A histological and electron microscopic study. Eur J Histochem 2018;62:2873.
10. Cummings L, Kaldahl W, Allen EP. Histologic evaluation of autogenous connective tissue and acellular dermal matrix grafts in humans. J Periodontol 2005;76:178-186.
11. Miller PD Jr. A classification of marginal tissue recession. Int J Periodontics Restorative Dent 1985;5:8-13.
12. Cairo F, Nieri M, Cincinelli S, Mervelt J, Pagliaro U. The interproximal clinical attachment level to classify gingival recessions and predict root coverage outcomes: an explorative and reliability study. J Clin Periodontol 2011; 38:661–666.
13. Löe, H. The Gingival Index, the Plaque Index and the Retention Index Systems. J Periodontol 1967; 38; Suppl:610-6.
14. Yates RJ, Newcombe RG, Addy M. Dentine hypersensitivity: a randomized, double blind placebo-controlled study of the efficacy of a fluoride-sensitive teeth mouthrinse. J Clin Periodontol 2004; 31: 885–889.
15. de Sanctis M, Zucchelli G.Coronally advanced flap: a modified surgical approach for isolated recession-type defects: three-year results. J Clin Periodontol. 2007; 34:262-268.
16. Henderson RD, Greenwell H, Drisko C, Regennitter FJ et al. Predictable multiple site root coverage using an acellular dermal matrix allograft. J Periodontol 2001;72:571–582.
17. Harris R. A comparison of root coverage obtained with a connective tissue graft versus an acellular dermal matrix. J Periodontol 1999; 70: 235.
18. Harris R. Acellular dermal matrix used for root coverage: 18-month follow-up observation. Int J Periodontics Restorative Dent 2002; 22:156-163.
19. Moslemi N, Jazi MM, Haghighati F, Morovati SP et al.

Acellular dermal matrix allograft versus subepithelial connective tissue graft in treatment of gingival recessions: a 5-year randomized clinical study. J Clin Periodontol 2011; 38:1122–1129.
20. Santos A, Goumenos G, Pascual A. Management of gingival Recession by the use of an Acellular Dermal graft Material: A 12 Case Series. J Periodontol 2005;76:1982-1990.
21. Felipe ME, Andrade PF, Grisi MF, Souza SL et al. Comparison of two surgical procedures for use of the acellular dermal matrix graft in the treatment of gingival recessions: a randomized controlled clinical study. J Periodontol.2007;78:1209-1217.
22. De Queiroz Cortes A, Sallum AW, Casati MZ, Nociti FH Jr et al. A two-year prospective study of coronally positioned flap with or without acellular dermal matrix graft. J Clin Periodontol 2006; 33: 683–689.
23. Cairo F, Rotundo R, Miller PD, Pini Prato GP. Root coverage esthetic score: A system to evaluate the esthetic outcome of the treatment of gingival recession through evaluation of clinical cases. J Periodontol 2009;80:705-710.
24. Andrade PF, Felipe ME, Novaes AB Jr, Souza SL et al. Comparison between two surgical techniques for root coverage with an acellular dermal matrix graft. J Clin Periodontol. 2008;35:263-269.
25. Novaes AB Jr, Grisi DC, Molina GO, Souza SL et al. Comparative 6-month clinical study of a subepithelial connective tissue graft and acellular dermal matrix graft for the treatment of gingival recession.J Periodontol. 2001;72:1477-1484.
26. Miller PD Jr. Root coverage with the free gingival graft. Factors associated with incomplete coverage. J Periodontol 1987; 58:674-681.
27. Harris RJ. A short-term and long-term comparison of root coverage with an acellular dermal matrix and a subepithelial graft. J Periodontol. 2004 May;75:734-743.
28. Gapski R, Parks CA, Wang HL. Acellular dermal matrix for mucogingival surgery: a meta-analysis. J Periodontol 2005;76:1814–1822.

Transmittance of lithium disilicate ceramic of different thicknesses and opacities with different curing units

Martín García-Cuerva[1], Agustina Boaventura-Dubovik[1], María E. Iglesias[2]

1. Universidad de Buenos Aires. Facultad de Odontología. Cátedra de Odontología Restauradora, Buenos Aires, Argentina.
2. Universidad de Buenos Aires. Facultad de Odontología, Cátedra de Materiales Dentales, Buenos Aires, Argentina

ABSTRACT

The aim of this study was to evaluate the amount of radiating energy transmitted through lithium disilicate discs of different thicknesses and opacities with different curing units (CU). Disc-shaped specimens 8 mm in diameter and 1.5 mm or 0.7 mm thick were designed with Zbrush® and Cura 3D® software, milled from HT and MO IPS e-maxCAD blocks (Ivoclar Vivadent) with Ceramill Mikro 4 (Amann Girrbach, Austria) and processed according to manufacturer instructions. Thickness was checked with a Mitutoyo (México) caliper. Four groups (n=4) were formed: G1(HT/1.5 mm), G2(MO/1.5 mm), G3(HT/0.7 mm) y G4(MO/0.7 mm), and the effect of three CUs: Coltolux (Coltene-Whaledent), LED.C, (Woodpecker Medical Instrument Co.Ltd) and Deepcure L(3M-ESPE) was tested Measurements were taken with a halogen and LED radiometer (Woodpecker® LM-1-Guilin Woodpecker Medical Instrument Co.Ltd) after applying the guide of each CU directly on the reading window (d) and after interposing each of the specimens. The ratio of transmitted energy was determined in each case and data was analyzed with repeated measures ANOVA and Tukey test for multiple comparisons. LED.C: d:1600 mW/cm2, G1: 0.31(0.00), G2: 0.14(0.00) G3: 0.54(0.01), G4: 0.38(0.01); Deepcure L: d:1500 mW/cm2, G1: 0.34(0.01), G2: 0.20(0,00), G3: 0.56(0.01), G4: 0.41(0.02); Coltolux: d:1275 mW/cm2, G1: 0.44(0.01), G2: 0.24(0,00), G3: 0.65(0.01), G4: 0.47(0,00). Statistically significant differences were found among the curing units (P<0.001) and for the interaction CU-thickness (P<0.001) and CU-opacity (P=0.023). Within the conditions of this study, the ratio of light transmitted through lithium disilicate structures is related to their thickness and opacity, and to the curing unit employed.

Received: January 2021; Accepted: April 2021.

Keywords: *lithium disilicate - ceramics - dental curing light.*

Transmitancia de cerámicas de disilicato de litio, de diferentes espesores y opacidades, con diferentes unidades de curado intrabucal

RESUMEN

Uno de los factores relacionados con éxito de las restauraciones y prótesis de cerámica de matriz vítrea es el logro de una fijación adhesiva para lo cual la correcta polimerización del medio de fijación es un requisito fundamental. El objetivo de este trabajo fue valorar la transmitancia de una cerámica a base de disilicato de litio de diferentes opacidades y espesores, con distintas unidades de curado. Probetas con forma de discos de 8mm de diámetro y dos diferentes espesores (1.5 mm y 0.7 mm) fueron diseñadas con Zbrush® y Cura 3D®, maquinadas a partir de bloques HT y MO de IPS e-maxCAD (Ivoclar Vivadent) con Ceramill Mikro 4 (Amann Girrbach, Austria) y procesadas según instrucciones del fabricante. Se obtuvieron cuatro grupos (n=4): G1(HT/1.5 mm), G2(MO/1.5 mm), G3(HT/0.7 mm) y G4(MO/0.7 mm),los espesores se controlaron con un calibre (Mitutoyo, México). A continuación, se registró la irradiancia con cada una de las unidades de curado (UC) Coltolux (Coltene-Whaledent) LED.C, (Woodpecker Medical Instrument Co.Ltd) y Deepcure L(3M-ESPE), aplicadas sobre la ventana de un radiómetro (Halogen and led radiometer Woodpecker® LM-1-Guilin Woodpecker Medical Instrument Co.Ltd) en forma directa (d), y luego de interponer los diferentes especímenes y se calculó la proporción de energía transmitida en cada caso. Los datos se analizaron con ANOVA de medidas repetidas y prueba de Tukey para las comparaciones múltiples. LED.C: d:1600 mw/cm2, HT/0,7mm: 0,54(0,01), HT/1,5mm:0,31(0); MO/0,7mm: 0,38(0,01), MO/1,5mm: 0,14(0,00); Deepcure L: d:1500 mW/cm2, HT/0,7 mm: 0,56(0,01), HT/1,5 mm: 0,34(0,01), MO/0,7 mm: 0,41(0,02), MO/1,5 mm: 0,20(0,00); Coltolux: d:1275 mw/cm2, HT/0,7 mm:0,65 (0,01), HT/1,5 mm:0,44(0,01), MO/0,7 mm: 0,47(0,00), MO/1,5mm: 0,24(0,00). Se encontraron diferencias estadísticamente significativas entre las diferentes unidades de curado (P<0,001), y en la interacción unidades de curado-espesor (P<0,001) y unidades de curado-opacidad (P=0,023). La proporción de energía luminosa transmitida por una estructura de cerámica de disilicato de litio depende del espesor y opacidad de la restauración y de la unidad de curado utilizada.

Palabras clave: *disilicato de litio - cerámica - unidades de curado.*

INTRODUCTION

Bonded ceramics have become the standard of care for esthetic restoration in current dentistry. According to numerous clinical studies, their advantages include excellent clinical performance, high rates of survival, near to ideal optical appearance, good biocompatibility, low thermal conductivity, chemical stability and surface smoothness[1,2].

Glass matrix and polycrystalline ceramics are the two families, according to their structure and composition, which can be used to fabricate metal-free restorations. Glass matrix ceramics (GMCs) are preferred when the main goals are esthetic results and stable micro-mechanical and chemical adhesive interaction with composite resin luting materials[3-6]. Among GMCs lithium disilicate (LDS) based ceramics have gained popularity recently, due mainly to their versatility, with an indication range that goes from veneers to three-piece bridges in premolar areas and implant-supported single crowns[7,8]. LDS restorations can be made either by traditional heat-pressing procedure or through a digital workflow and milling process (CAD-CAM). There are key differences in crystal distribution, shape and size between pressed and CAD-CAM restorations, all of which are prone to affect the transmittance of the structure[8,9].

One of the most important factors related to clinical success of glass ceramics is the achievement of durable bonding between dental tissues and the restorative unit through a composite-based luting material (CBLM) of adequate mechanical properties[10]. To ensure effective adhesive interaction, not only surface treatments of both substrates, but also an adequate activation of the polymerization in the composite organic matrix, are key factors[1,11-13]. Adequate activation is relevant for both light-cured and dual-cured materials. Although dual-cured materials were developed in an attempt to ensure activation in regions difficult to reach by light, they present significantly lower degrees of conversion when not properly photoactivated[1, 14-17].

Several variables have been reported to affect the quality of CBLM polymerization, including specific luting material composition, adhesive-cement negative interaction, and transmitted light attenuation due to scattering and absorption as light passes through the restoration[14,18,19]. The amount of radiant energy that is lost whilst being transmitted through a ceramic restoration" depends on ceramic composition, structure, quality and quantity of the crystalline phase, thickness, shade and porosity, among other factors[14,17]. This reduction results in less energy being absorbed by the initiator system of the luting composite and thus, a lower degree of conversion and lower mechanical and chemical properties, biological compatibility and bond strength[8].

Light transmittance for successful activation of composite luting materials depends not only on the characteristics of the restorative materials, but also the quality of the irradiated light. Hence, the transmittance in the 360-540 nm range should be considered, rather than the one occurring in the whole visible spectrum, which is more related to the concept of translucency as an optical property. Brodbelt[20] found that dental ceramics transmit two hundred times more light when scattering is taken into account (total transmission) and that transmittance also increases with higher wavelengths, as stated by Rayleigh's law. Transmittance of blue light would thus be overestimated if total spectrum transmission is considered. Lieberman et al.[2] found that different ceramics transmitted higher rates of visible light than light in the blue spectra. This difference in transmittance may also be of interest when considering the different emission spectra of the curing units (CU) available. One study found that transmittance was significantly lower for CU emitting in the violet range than for others which spectrum was in the blue area[1]. The emission spectra vary among different CU, for instance, typical halogen units have broad range of emission spectra, from about 390 nm to 500 nm, while LED curing units, depending on their generation, may have different spectra of 440-500nm, 420-475 nm, or 390-415 nm and 430-490 nm in bimodal emission units[21-23].

The aim of this study was to assess the transmittance of a lithium disilicate ceramic of different opacities and thicknesses with different curing units.

MATERIALS AND METHODS

Disc-shaped specimens 8 mm in diameter and 1.5 mm or 0.7mm thick were designed with Zbrush® and Cura 3D® (Ultimaker) software, milled from high translucency (HT) and medium opacity (MO) IPS e-maxCAD blocks (Ivoclar Vivadent), (Fig. 1) with Ceramill Mikro 4 (Amann Girrbach, Austria) and processed according to manufacturer



Fig. 1: Specimen dimensions and opacity

instructions. Thickness was verified in each case with a Mitutoyo (Mexico) caliper. Four different groups (n=4) were formed: G1(HT/1.5mm), G2(MO/1.5 mm), G3(HT/0.7 mm) and G4(MO/0.7 mm). Three curing units with fully charged battery throughout the procedure were used: Coltolux (Coltene-Whaledent)[24], LED.C (Woodpecker Medical Instrument Co.Ltd)[25] and Deepcure L (3M-ESPE)[26] (Table 1). After installing an opaque 8mm diameter ad hoc sample holder, the reading of an halogen and led radiometer (Woodpecker® LM-1-Guilin Woodpecker Medical Instrument Co.Ltd) was registered with each curing unit guide placed in the sample holder directly on the reading window (SL - source luminance) and after interposing each of the specimens (CL - ceramic luminance). Absolute values were registered and transmittance (T) was determined in each case as the ratio between the first and second reading T= CL/SL. Data was analyzed with repeated measures ANOVA and Tukey test for multiple comparisons

RESULTS

Under all the study conditions, the interposing of the specimens caused a statistically significant decrease in irradiance from 35% to 86% (Fig. 2), resulting in transmittance values of 0.65 to 0.14, which were related to the curing unit used (P<0.001) and to the interactions between curing units and thickness (P<0.001), as well as between curing units and opacity (P=0.023). CU source luminance values were 1275 mW/cm2, 1600 mW/cm2 and 1500 mW/cm2 for Coltolux (Coltene-Whaledent), LED.C, (Woodpecker Medical Instrument Co.Ltd), and Deepcure L(3M-ESPE), respectively. Significant differences were also found among the three CUs studied regarding the behavior of the samples of different thicknesses and opacities (Table 2) .

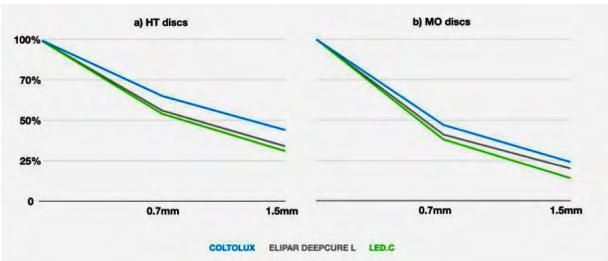

Fig. 2: a) Transmittance with HT discs. b) Transmittance with MO discs

Table 1. Manufacturer information of curing units

	Coltolux[24]	LED.C[25]	Deepcure L[26]
Manufacturer	Coltene-Whaledent	Woodpecker Medical Instrument Co. Ltd.	3M-ESPE
Diameter of guide	9 mm	8 mm	10 mm
Spectrum of emission	450-470 nm	420-480 nm	430-480 nm

Table 2. Transmittance (Ceramic luminance/Source luminance). Mean (SD).

Opacity	Thickness (mm)	Coltolux	LED.C	Deepcure L
HT	**0.7**	0.65 (0.01)	0.54 (0.01)	0.56 (0.01)
	1.5	0.44 (0.01)	0.31 (0.00)	0.34 (0.01)
MO	**0.7**	0.47 (0.00)	0.38 (0.01)	0.41 (0.02)
	1.5	0.24 (0.00)	0.14 (0.00)	0.20 (0.00)

Curing unit used (P<0.001), curing units-thickness (P<0.001) and curing units-opacity (P=0.023)

DISCUSSION

Adhesive cementation is one of the key factors related to clinical survival and success of bonded glass ceramic restorations, as any flaw in the interface between the substrates may lead to early failure due to fracture, secondary caries, postoperative sensitivity, pigmentation and marginal leakage[1]. Another important aspect related to longevity is the CBLM elastic modulus, since due to the brittleness of ceramics, tensile stress is more likely to cause catastrophic failure than compressive stress, and lower values of elastic modulus in the underlying structures result in increased tensile stress[27]. Resin-based luting materials, whether photo-activated or dual-cure, require that enough energy is absorbed by the initiator system to reach an adequate degree of conversion, providing suitable physical, mechanical and biological properties. For that to happen, sufficient energy must be transmitted through the ceramic restorative structure[11,28].

Different authors found that thickness and ceramic type were related to transmittance[28-31]. Zhang et al. found that 37%, 14% and 9% of the irradiating energy was transmitted through 1 mm, 2 mm and 3 mm, respectively, of a lithium disilicate ceramic[31]. Furthermore, Lópes et al.[28] reported transmission of 20% of total irradiated energy through 1.5 mm of the same material, which is consistent with the findings in the current study.

Evidence has been found that transmittance of ceramic is also dependent on the wavelength of the incident light, therefore, under equal conditions, ceramics transmit a higher fraction of energy in the 400-700 nm range than in the 380-540 nm range[2]. Hardy also reported that the use of a curing unit emitting light at 390-419 nm resulted in a lower fraction transmitted than a CU emitting 430-510 nm, in a zirconia-based material[1]. This may explain the effect of the curing unit factor found in the current study, where the higher the range emitted by the CU, the higher the fraction of energy transmitted [Coltolux - 450-470 nm, followed by Elipar Deepcure L (3M-ESPE 430-480 nm), and subsequently by LED C Woodpecker Guilin (420-480 nm)]. Although the differences in emitting spectrum may seem small, they are related to significative differences in the amount of energy transmitted. O'Keefe found similar results with Vita B2 felspathic porcelain veneers, which had different transmittance at 460, 470 and 480 nm[30]. Della Bonna et al. reported spectral behavior showing a slight linear increase in transmittance as wave length increased in most ceramics up to 550nm, beyond which the function is material-dependent[29].

Hence, when luting an indirect ceramic restoration, successful polymerization activation is potentially compromised by two relevant factors: the wavelength of the light and the amount of energy effectively transmitted[1,2,20]. Regarding the latter, reductions ranging from nearly 40% to 86% of total irradiance should be expected. This could be addressed by employing a CU with higher irradiance to deliver sufficient energy, or by increasing curing time in order to maintain the energy dose. However, Bueno et al. found that for some luting materials, increasing curing time does not effectively compensate light attenuation due to the presence of an indirect restoration, so it should be considered material-dependent[13]. This could be explained by the transmitted light spectra, since the shorter the wave length, the less the transmission, so the effect should be more detrimental to CBLMs that include initiators such as PPD, TPO or Ivocerin® with absorbance peaks in the range of 350-400 nm, than to materials with camphorquinone[32].

The roughening of the inner surface of the restoration as result of acid etching, and the increase of reflection due to finishing procedures, polishing or glazing of the outer surface, could be interesting factors to add to the equation of light transmittance in dental ceramics because additional scattering and reflection, respectively, could enhance the loss of transmitted energy.

Transmission efficiency affects the degree of conversion of composite-based luting materials and has direct consequence on longevity and clinical success. Moreover, the CU plays an important part in this process, mainly through its emission spectrum range. Therefore, when planning the adhesive procedures for bonded ceramics, the following factors are important and should be considered: type, composition, thickness, color and translucency of the ceramic system; spectrum of emission and irradiance of the curing unit and, according to Hardy et al., the monomer fraction, the presence of TEGDMA in the resin matrix, and the initiator system of the luting material[1].

DECLARATION OF CONFLICTING INTERESTS
The authors declare no potential conflicts of interest with respect to the research, authorship, and/or publication of this article.

FUNDING
This study was supported by a grant from Universidad de Buenos Aires. UBACYT programe 20020160100037BA

CORRESPONDENCE
Dr. María Emilia Iglesias
Cátedra de Materiales Dentales
Facultad de Odontología
Universidad de Buenos Aires
Marcelo T de Alvear 2142, piso 3 B, C1122AAH
Ciudad Autónoma de Buenos Aires, Argentina
mariaemilia.iglesias@odontologia.uba.ar

REFERENCES

1. Hardy CMF, Bebelman S, Leloup G, Hadis MA et al. Investigating the limits of resin-based luting composite photopolymerization through various thicknesses of indirect restorative materials. Dent Mater. 2018;34:1278-1288. doi:10.1016/j.dental.2018.05.009
2. Liebermann A, Freitas Rafael C, Colle Kauling AE, Edelhoff D et al. Transmittance of visible and blue light through zirconia. Dent Mater J. 2018;37:812-817. doi:10.4012/dmj.2016-287
3. Sundfeld D, Correr-Sobrinho L, Pini NI, Costa AR et al. The Effect of Hydrofluoric Acid Concentration and Heat on the Bonding to Lithium Disilicate Glass Ceramic. Braz Dent J. 2016;27:727-733. doi: 10.1590/0103-6440201601024.
4. Li R, Ma SQ, Zang CC, Zhang WY et al. Enhanced bonding strength between lithium disilicate ceramics and resin cement by multiple surface treatments after thermal cycling. PLoS One. 2019;25;14:e0220466. doi: 10.1371/journal.pone.0220466.
5. Maunula H, Hjerppe J, Lassila LLV, Närhi TO. Optical Properties and Failure Load of Thin CAD/CAM Ceramic Veneers. Eur J Prosthodont Restor Dent. 2017;25:86-92. doi: 10.1922/EJPRD_01677Maunula07.
6. Spitznagel FA, Boldt J, Gierthmuehlen PC. CAD/CAM Ceramic Restorative Materials for Natural Teeth. J Dent Res. 2018;97:1082-1091. doi: 10.1177/0022034518779759.
7. Oh S, Shin SM, Kim HJ, Paek J et al. Influence of glass-based dental ceramic type and thickness with identical shade on the light transmittance and the degree of conversion of resin cement. Int J Oral Sci. 2018;10:5. doi:10.1038/s41368-017-0005-7
8. Jafari Z, Alaghehmand H, Samani Y, Mahdian M et al. Light transmittance of CAD/CAM ceramics with different shades and thicknesses and microhardness of the underlying light-cured resin cement. Restor Dent Endod. 2018;43:e27. doi:10.5395/rde.2018.43.e27
9. Fabian Fonzar R, Carrabba M, Sedda M, Ferrari M et al. Flexural resistance of heat-pressed and CAD-CAM lithium disilicate with different translucencies. Dent Mater. 2017;33:63-70. doi: 10.1016/j.dental.2016.10.005.
10. Çetindemir AB, Şermet B, Öngül D. The effect of light sources and CAD/CAM monolithic blocks on degree of conversion of cement. J Adv Prosthodont. 2018;10:291-299. doi: 10.4047/jap.2018.10.4.291.
11. Mendonça LM, Ramalho IS, Lima LASN, Pires LA et al. Influence of the composition and shades of ceramics on light transmission and degree of conversion of dual-cured resin cements. J Appl Oral Sci. 2019;27:e20180351. doi:10.1590/1678-7757-2018-0351
12. Ilie N, Hickel R. Correlation between ceramics translucency and polymerization efficiency through ceramics. Dent Mater. 2008;24:908-914. doi:10.1016/j.dental.2007.11.006
13. Bueno AL, Arrais CA, Jorge AC, Reis AF et al. Light-activation through indirect ceramic restorations: does the overexposure compensate for the attenuation in light intensity during resin cement polymerization? J Appl Oral Sci. 2011;19:22-27. doi:10.1590/s1678-77572011000100006
14. De Souza G, Braga RR, Cesar PF, Lopes GC. Correlation between clinical performance and degree of conversion of resin cements: a literature review. J Appl Oral Sci. 2015;23:358-368. doi: 10.1590/1678-775720140524.
15. Guimaraes IR, Murillo Gómez F, De Goes MF. Effect of activation mode on flexural strength and elasticity modulus of dual cure resin cements. ODOVTOS-Int. J. Dental Sc. 2016;18:61-71. DOI:10.15517/ijds.v18i1.23556
16. Mendes LC, Matos IC, Miranda MS, Benzi MR. Dual-curing adhesive resin cement: influence of the polymerization modes on the degree of conversion and microhardness. Materials Research. 2010;13:171-176.
17. Ayres AP, Andre CB, Pacheco RR, Carvalho AO et al. Indirect Restoration Thickness and Time after Light-Activation Effects on Degree of Conversion of Resin Cement. Braz Dent J. 2015;26:363-367. doi:10.1590/0103-64402013x0024
18. Kilinc SA, Antonson PC, Hardigan A, Kesercioglu A. The Effect of Ceramic Restoration Shade and Thickness on the Polymerizationof light-and Dual-cure Resin Cements. Oper Dent. 2011;36: 661-669.
19. Ilie N, Simon A. Effect of curing mode on the micro-mechanical properties of dual-cured self-adhesive resin cements. Clin Oral Investig. 2012;16:505-512. doi:10.1007/s00784-011-0527-x
20. Brodbelt RHW, O'Brien WJ, Fan PL. Translucency of Dental Porcelains J Dent Res. 1980; 59:70-75.
21. Rueggeberg FA, Giannini M, Arrais CAG, Price RBT. Light curing in dentistry and clinical implications: a literature review. Braz Oral Res. 2017;28;31(suppl 1):e61. doi: 10.1590/1807-3107BOR-2017.vol31.0061.
22. AlShaafi MM, Harlow JE, Price HL, Rueggeberg FA et al. Emission Characteristics and Effect of Battery Drain in "Budget" Curing Lights. Oper Dent. 2016;41:397-408. doi: 10.2341/14-281-L.
23. Soares CJ, Rodrigues MP, Oliveira LRS, Braga SSL et al. An Evaluation of the Light Output from 22 Contemporary Light Curing Units. Braz Dent J. 2017;28:362-371. doi: 10.1590/0103-6440201601466.

24. https://lam.coltene.com/pim/DOC/BRO/docbro31266c-en-07-20-coltolux-edsenaindv1.pdf 22/9/20
25. MANUAL 1 https://www.woodpecker.cz/Documents/LED-C_manualEN.pdf 22/9/20
26. https://multimedia.3m.com/mws/media/1173327O/elipar-deepcure-led-curing-lights-technical-product-profile.pdf
27. Liu B, Lu C, Wu Y, Zhang X et al. The effects of adhesive type and thickness on stress distribution in molars restored with all-ceramic crowns. J Prosthodont. 2011;20:35-44. doi: 10.1111/j.1532-849X.2010.00650.x.
28. Lopes C de C, Rodrigues RB, Silva AL, Simamoto Júnior PC et al. Degree of Conversion and Mechanical Properties of Resin Cements Cured Through Different All-Ceramic Systems. Braz Dent J. 2015;26:484-489. doi: 10.1590/0103-6440201300180.
29. Della Bona A, Nogueira AD, Pecho OE. Optical properties of CAD-CAM ceramic systems. J Dent. 2014;42:1202-1209. doi: 10.1016/j.jdent.2014.07.005.
30. O'Keefe KL, Pease PL, Herrin HK. Variables affecting the spectral transmittance of light through porcelain veneer samples. J Prosthet Dent. 1991;66:434-438. doi: 10.1016/0022-3913(91)90501-m. PMID: 1791552.
31. Zhang X, Wang F. Hardness of resin cement cured under different thickness of lithium disilicate-based ceramic. Chin Med J (Engl). 2011;124:3762-3767.
32. Neumann MG, Schmitt CC, Ferreira GC, Corrêa IC. The initiating radical yields and the efficiency of polymerization for various dental photoinitiators excited by different light curing units. Dent Mater. 2006;22:576-584. doi: 10.1016/j.dental.2005.06.006.

Prevalence of three-rooted primary mandibular first and second molars: clinical and radiographic findings in a Mexican population

María A. Moyaho-Bernal[1], Rosendo Carrasco-Gutiérrez[1], Rosario Jiménez-Flores[2], Gladis Juárez-Luna[3], Gerardo R. López-Del Pino[1], Luz V. Mendoza-García[4], Bernardo Teutle-Coyotecatl[1]

1. Benemérita Universidad Autónoma de Puebla, Facultad de Estomatología, Academia de Pediatría, Puebla, México.
2. Benemérita Universidad Autónoma de Puebla, Facultad de Estomatología, Academia de Ciencias Básicas, Puebla, México.
3. Benemérita Universidad Autónoma de Puebla, Facultad de Estomatología, Departamento de Odontología Forense, Puebla, México.
4. Centro de Investigación y Estudios Superiores en Estomatología y Salud, S.C., Puebla, México.

ABSTRACT

The aim of this study was to determine prevalence and describe the clinical and radiographic findings of three-rooted primary mandibular first and second molars in a Mexican population. Intraoral periapical radiograph, orthopantomogram or cone beam computed tomography (CBCT) were obtained. A total 2284 children from the state of Puebla, Mexico were examined, of whom 20 presented an anatomic variant in tooth crown shape. Of the total teeth with crown alterations, 10 first and 5 second primary mandibular molars were found to have supernumerary roots. In one case, it was possible to obtain micro-CT images.

The study recorded prevalence, unilateral or bilateral occurrence, and ratio between sexes. Data were analyzed using descriptive statistics.

Clinical findings were presence of an anatomical variation (tuberculum paramolare / right and/or left cervical convexity) in primary mandibular first molars. Second molars presented conventional crown morphology. Prevalence of three-rooted primary mandibular first and second molars was 0.44% and 0.22%, respectively. Male: female ratio for presence of three-rooted primary mandibular first molars was 4:1, showing genetic predisposition in males, and for second molars it was 1.5:1, with no predisposition according to sex. The clinical and radiographic anatomical variants in primary molars should be considered by pediatric dentists during routine care because they may cause difficulties in restorations.

Received: October 2020; Accepted: April 2021.

Keywords: *deciduous tooth - tooth root - anomalies - diagnostic imaging.*

Prevalencia de primeros y segundos molares primarios mandibulares con tres raíces: hallazgos clínicos y radiográficos en una población mexicana

RESUMEN

El objetivo de este estudio fue determinar la prevalencia, así como los hallazgos clínicos y radiográficos de los primeros y segundos molares primarios mandibulares con tres raíces en una población mexicana. Se obtuvieron radiografías periapicales intraorales, ortopantomografía o tomografía computarizada de haz cónico (TCHC). Fueron revisados en total 2284 niños originarios del estado de Puebla, México, de los cuales 20 sujetos presentaron una variante anatómica en la forma de la corona dental. En el total de dientes con alteraciones coronarias, se encontraron 10 primeros y 5 segundos molares primarios mandibulares con raíces supernumerarias. En un caso fue posible la obtención de imágenes de micro tomografía computarizada (micro-CT).

Fueron registradas la prevalencia, la ocurrencia uni o bilateral y la relación entre sexos. Los datos se analizaron mediante estadística descriptiva.

Los hallazgos clínicos fueron: presencia de una variación anatómica (tuberculum paramolare / convexidad cervical derecha y/o izquierda) en los primeros molares primarios mandibulares. Los segundos molares presentaron una morfología coronal convencional. Entre los hallazgos radiográficos, fue común encontrar un conducto en cada raíz. La prevalencia fue de 0,44% y 0,22% para los primeros y segundos molares primarios mandibulares con tres raíces, respectivamente. La relación por sexo en los primeros molares primarios mandibulares con tres raíces fue de 4:1, indicando una predisposición genética para el sexo masculino, mientras que, en los segundos molares, la razón fue de 1,5:1 sin predisposición por sexo. Las variantes anatómicas clínicas y radiográficas presentes en los molares primarios deben ser tomadas en cuenta por los odontopediatras durante su rutina de atención, ya que pueden ocasionar dificultades para la restauración.

Palabras clave: *dientes primarios - raíz dentaria - anomalías - diagnóstico por imágenes.*

INTRODUCTION

The main aim of pulp therapy in primary teeth is to preserve the integrity of the affected tooth. Pulpectomy usually resolves the fistula problem in pediatric dentistry. However, treatment may be difficult in specific cases when there is a supernumerary root. This anatomical variation usually presents in primary first and second molars. It is an unusual finding, also considered to be a racial characteristic in Asian and Asian-derived populations[1].

Turner described similarities in the frequency of this anomaly among American Indians and contemporary southeastern Asian peoples[2]. These findings enabled inference of genetic relationships that are consistent with theories on important migratory events over the past 20,000 years.

Other studies suggest that the development of a supernumerary root may be due to external factors during odontogenesis, the expression of an atavistic gene with recurrence of a trait that has been absent for several generations, or a polygenic or multifactorial inheritance system[3].

There are few reports of clinical cases of supernumerary roots in primary teeth, and little is known about the characteristics of their crowns[4-6]. The aim of this study was to determine the prevalence of three-rooted primary mandibular first and second molars, and describe their clinical and radiographic characteristics in a Mexican population.

MATERIALS AND METHODS

This was a cross-sectional study that followed the guidelines for reporting observational studies set forth in Strengthening the Reporting of Observational Studies in Epidemiology (STROBE)[7]. It was approved by the Research Ethics Committee of the School of Stomatology at Puebla University, Mexico (Res. 003-11032014).

A total 2284 patients who visited the Pediatric Dentistry Clinic from January 2014 to December 2019 were examined. The children visited the clinic for a routine procedure. Twenty of these children presented some anatomical variation in the dental crown. They all came from Puebla State. Their clinical history was taken and parents signed informed consent for their inclusion in the study. Intraoral periapical radiographs, orthopantomography, or cone beam computed tomography (CBCT) were taken, as applicable to each particular case. As diagnostic aids, periapical radiographs were taken of 19 children, orthopantomography of one child who needed orthopedic treatment, and cone beam computed tomography of one child who had a dentigerous cyst. The 3D CBCT images were taken using Orthophos XG, Sirona Dental Systems GmbH, version 2.5x SIDEXIS XG. Images were viewed using Galaxis Galileos 1.9 with a section window according to region of interest in volumetric mode, with bone contour, with threshold 1764 and transparency 78.8%, soft tissue range 961 and transparency 94.5%. Analysis was performed in two views (panoramic and 3D) and three axial sections: apical (A1), middle (A2) and cervical (A3) levels of the roots.

Extraction of a molar was necessary in one case due to an extensive carious lesion. This enabled the molar to be studied by micro-CT. The tooth was dried slightly, mounted on an *ad hoc* device and scanned in a micro-CT scanner (Nikon Metrology Dual-Source 225kV-450kV) at isotropic resolution 16.7 lm. The X-ray tube was operated at 93 Kv and 102 uA, and the scan was performed with 360° rotations. Different sections were obtained along the Z axis (upper z) for viewing the 3D model and quantitative evaluation of root canal shape.

The images were reconstructed using the software VGSTUDIO MAX 3.3.0. All images were evaluated by two previously standardized pediatric dentists. Prevalence of three roots in both sexes, and unilaterality or bilaterality were determined, and clinical and radiographic findings were described.

RESULTS

The most frequent crown anomaly (10 of the 20 cases studied) was a triangular-shaped mandibular first molar, characterized by the presence of a distolingual lobe in combination with a cervical prominence (Figs. 1a, b). Other crown variations were paramolar cusp (tuberculum paramolare), in a mandibular first molar (1 case) and mandibular second molars (2 cases, Figs. 1c, d, e). In addition, one case exhibited a root canal emerging from the paramolar cusp in the vestibular zone (Fig. 1f).

Figure 2 shows different radiographic images of three-rooted primary molars. We found one case with radix entomolaris in a permanent molar and three roots in the primary mandibular second molar. Supernumerary root canals are usually divergent, wide and well delimited, and may be associated to

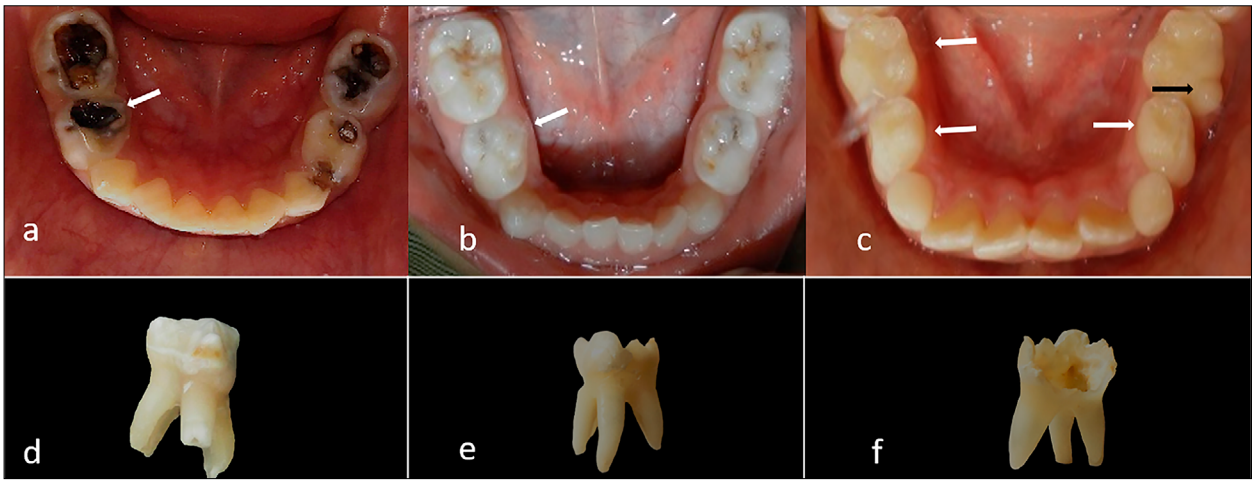

Fig. 1: Occlusal photographs showing crown morphology of three-rooted primary mandibular molars. a) and b) Triangular-shaped primary mandibular first molar (arrows). c) Primary mandibular first and second molars with normal anatomy (white arrows) and primary mandibular second molar with paramolar cusp (black arrow). d) Primary mandibular first molar with paramolar cusp. e) Vestibular view of primary mandibular second molar with paramolar cusp. f) Lingual view of primary mandibular second molar with the canal entrance of the radix paramolaris.

a cervical prominence in the crown (Figs. 2d and 2e). In 3 of the 15 cases studied, the anomaly was bilateral (Fig. 2f).

The CBCT images showed root canal morphology in detail. Fig. 3 is an example of a case in which mesial and distal canals were ribbon-shaped, while the canal in the accessory root was circular. 3D reconstructions clearly show the size relationship and position of roots and their root canals (Fig. 3b).

The micro-CT showed early physiological root resorption, as well as a ribbon-shaped mesial canal, an oval-shaped distal canal, presence of a robust, well-defined accessory root with round-shaped vestibular canal which, according to its position, corresponds to a radix paramolaris (RP). There was also a small diverticulum located in the vestibular zone between the RP and the mesial root (Fig. 4).

Prevalence of three roots was 0.44% and 0.22% for first and second molars, respectively. Male:female ratio for three-rooted primary mandibular first molars was 4:1, indicating a genetic predisposition in males. For second molars, the ratio was 1.5:1, without predisposition according to sex.

The frequency of three-rooted primary mandibular first and second molars was higher on the right side than on the left side, with a 5:1 ratio. Results are shown in Tables 1 and 2.

DISCUSSION

Dental pattern is defined as a set of discrete, independent morphological features which may be present or absent in the crown and in the root, and/or may present variation in shape, which may be small, moderate, large or very large[8].

In normal conditions, the primary mandibular first molar has four cusps (two buccal and two lingual) and the primary mandibular second molar has five cusps; both molars have two divergent roots and three root canals[9]. In the current study, the most common clinical finding was the triangular shape of the crown of the primary mandibular first molar, with presence of a distal lingual lobe in combination with the cervical prominence.

Crowns may also have other structural variations such as accessory crests, tubercules or cusps expressed on the lingual, occlusal or buccal surfaces[10]. Crown alterations may also be accompanied by root alterations. Thus, the paramolar cusp is a feature that is frequently associated with a rudimentary root formation in permanent dentition, specifically in second and third molars. The occurrence of this tubercle has been reported in 2 to 65 out of every 1000 individuals. This frequency is lower than that of the Carabelli's tubercle (10 to 380 of every 1000 individuals in Europe)[11].

An interesting finding in the current study was the presence of a paramolar cusp in three different cases. Its occurrence is considered atypical in deciduous

Fig. 2: Radiographs of 3-rooted molars. a) Periapical radiograph showing a primary mandibular first molar with pulpectomy treatment (arrow). b) Primary mandibular second molar (arrow). c) Permanent mandibular first molar and primary mandibular second molar (arrows). d) and e) Bilateral primary mandibular first molar (arrow s). f) Orthopantomographic image showing a case of primary bilateral second molars (arrows).

teeth, more specifically, in the second molar[12,13]. Crown morphological variations (triangular shape and paramolar cusp) may cause clinical difficulties for restoration with preformed stainless steel crowns. In the three cases mentioned, the crown anatomical aberration continued towards the root as a radix paramolarisis (RP) or diverticulum.

Normal primary mandibular first and second molars usually have two roots: one mesial with two canals and another distal with one canal[14], although some studies have reported one or two canals per root[15,16]. The current study found one primary mandibular first molar with no clinical evidence of caries which only presented pain on percussion. This made clinical diagnosis difficult until the presence of a third root was found in the periapical radiograph. The CBCT revealed that the primary second molar had one canal in each root. The mesial and distal canals were ribbon-shaped, while the accessory root canal was round-shaped, narrower and shorter in comparison to the adjacent roots. In cases such as this, the pulp may not be fully formed in the

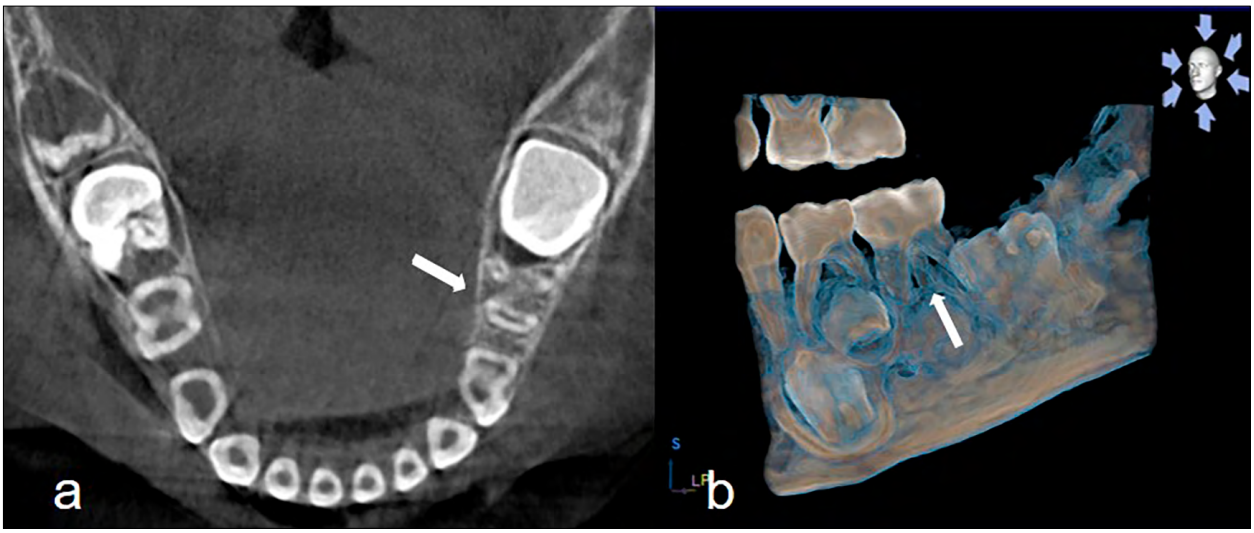

Fig. 3: Cone beam computed tomography. a) Image of cross section corresponding to horizontal lines at the mid-level of primary mandibular molar roots; left primary mandibular first molar with three roots and one canal per root (arrow). b) Three-dimensional view of 3-rooted primary mandibular second molar (arrow).



Fig. 4: Micro-TC images. Three-rooted primary mandibular second molar with one canal in each root. a) Cross section. M: mesial, D: distal, V: vestibular and L: lingual. b) Three-dimensional model of a 3-rooted primary mandibular second molar and diverticulum located in vestibular (arrow).

accessory root[17], which might cause pulp problems such as septic necrosis without presence of a fistula. Yang *et al.*[18] report that primary mandibular second molars may present seven variations in root morphology. In this regard, we found a small diverticulum located in vestibular of a second molar between the RP and the mesial root. If we consider this diverticulum to be a root, the case could be classified as variant type 7: four separate roots with a root canal in each[18].

Clinically, it is important to know about the anatomic variations of the root. Previous studies have discussed the implications of supernumerary roots in permanent first molars for endodontics and exodontia[3,19]. The same precaution must be taken for primary teeth, and pediatric dentists should have specific information on root canal morphology in children[20,21]. Knowledge of root canal shapes could help overcome problems related to root canal cleaning procedures[22].

The presence of supernumerary roots has been reported in several populations[5,6,13,23] but to date there is no information on the Mexican population. The study population for this research consists of children from the State of Puebla. General prevalence of supernumerary roots was 0.44% and 0.22% for primary mandibular first and second molars, respectively, which is somewhat lower than values reported for other populations[19,24-27].

Reports are not consistent regarding the unilateral

Table 1. Prevalence of three-rooted primary mandibular first and second molars.

Mandibular first molar No. of subjects	Unilateral		Bilateral	Total
	Right	Left		
Male (n=943)	5 (0.53)	1 (0.11)	2 (0.21)	8 (0.85)
Female (n=1341)	0 (0.00)	2 (0.15)	0 (0.00)	2 (0.15)
Total (n=2284)	5 (0.22)	3 (0.13)	2 (0.09)	10 (0.44)
Total no. of teeth examined (n=4568)	5 (0.11)	3 (0.07)	2 (0.04)	10 (0.22)
Mandibular second molar No. of subjects	**Unilateral**		**Bilateral**	**Total**
	Right	**Left**		
Male (n=943)	1 (0.11)	1 (0.11)	1 (0.11)	3 (0.32)
Female (n=1341)	0 (0.00)	2 (0.15)	0 (0.00)	2 (0.15)
Total (n=2284)	1 (0.04)	3 (0.13)	1 (0.04)	5 (0.22)
Total no. of teeth examined (n=4568)	1 (0.02)	3 (0.07)	1 (0.02)	5 (0.11)

**Data presented as n (%).*

Table 2. Distribution and odds ratio of unilateral and bilateral occurrence among fifteen subjects with three-rooted primary mandibular molars.

Additional root	No. of subjects		Odds ratio
	Primary first molars	Primary second molars	
Unilateral			
Right	5 (50)	1 (20)	5:1
Left	3 (30)	3 (60)	1:1
Subtotal	8 (80)	4 (80)	2:1
Bilateral	2 (20)	1 (20)	2:1
Total	10 (100)	5 (100)	2:1

**Data presented as n (%).*

or bilateral presence of this anomaly. In our study, most of the three-rooted primary mandibular first molars were unilateral (80%), predominantly on the right side (50%), in agreement with Mathew *et al.*[24] and Tu *et al.*[25]. Other studies report that this variation predominates on the left side[28,29]. Reports of bilateral occurrence range from 50% to 67%[4], whereas in our series it was only 20%.

Most studies have reported predominance of supernumerary roots in males[28], in agreement with our study. Some authors suggest that it is a sex-linked dominant trait, while others have found similar prevalence in both sexes[5,27].

It has been reported that supernumerary roots are less frequent in primary dentition than in permanent dentition[13,29]. Cases have also been described in which the anomaly is present in both dentitions, especially in the primary second molar and permanent first molar[30]. In the current study, we found one girl with this characteristic.

Supernumerary roots play a role as a genetic marker with forensic importance in terms of identification of persons of a certain race. Further studies are needed on prevalence in Mexican subjects, covering larger samples and different regions of the country, in order to be able to define its anthropological importance.

CONCLUSIONS

Pediatric dentists should consider the variations in dental morphology in temporary molars. A dysmorphic crown in the primary first mandibular molar may be related to the presence of an additional root; moreover, it could cause difficulties in restorations using commercially available steel-chrome crowns.

The temporary second molar was found to have more stable crown morphology. The additional root may have anatomic variations and is most often located distal-lingually with a round canal.

Prevalence of three-rooted primary mandibular molars in Mexican subjects was 0.44% for first molars and 0.22% for second molars.

Further studies are needed on very large samples to establish exact prevalence in the Mexican population.

ACKNOWLEDGMENTS
The authors thank the Radiological Center at the School of Dentistry and the Advanced Center for Nondestructive Analytic Assays on Materials of Benemérita Universidad Autónoma de Puebla, Mexico. Special thanks to Rocío Pedraza Espejel for help with cone beam computed tomography (CBCT) images and Gabriela Esquina Esgua for help with micro-CT images.

DECLARATION OF CONFLICTING INTERESTS
The authors declare no potential conflicts of interest regarding the research, authorship, and/or publication of this article

FUNDING
None

CORRESPONDENCE
Dr. Bernardo Teutle-Coyotecatl
Facultad de Estomatología de la Benemérita Universidad Autónoma de Puebla.
Calle 31 poniente 1304 colonia Los Volcanes. C.P. 72410. Puebla, México.
bertc_21@hotmail.com.

REFERENCES

1. Ferraz JA, Pécora JD. Three-rooted mandibular molars in patients of Mongolian, Caucasian and Negro origin. Braz Dent J 1993; 3: 113-117.
2. Turner CG II. Three-rooted mandibular first permanent molars and the question of American Indian origins. Am J Phys Anthropol 1971; 34: 229-241.
3. Tu MG, Tsai CC, Jou MJ, Chen WL et al. Prevalence of three-rooted mandibular first molars among Taiwanese individuals. J Endod 2007; 33: 1163-1166.
4. Ramamurthy N, Srinivasan I. Bilateral three-rooted primary lower molars. Indian J Dent Res 2012; 23: 700.
5. Winkler MP, Ahmad R. Multirooted anomalies in the primary dentition of Native Americans. J Am Dent Assoc 1997; 128: 1009-1011.
6. Curzon JA, Curzon ME. Congenital dental anomalies in a group of British Columbia children. J Can Dent Assoc (Tor). 1967; 33: 554-558.
7. Von Elm E, Altman DG, Egger M, et al. The Strengthening the Reporting of Observational Studies in Epidemiology (STROBE) Statement: guidelines for reporting observational studies. Int J Surg 2014; 12: 1495-1499.
8. Turner CG, Scott GR. The Dentition of American Indians: Evolutionary Results and Demographic Implications Following Colonization from Siberia. In Handbook of Paleoanthropology, Vol. 3, Phylogeny of Hominids, edited by Winfried Henke and Ian Tattersall, pp. 1901–1902, Springer-Verlag, Berlin.
9. Teixeira LMS, Reher P. Anatomia aplicada à odontologia. In Anatomia Aplicada à odontología, 1993:194-194.
10. Scott GR, Turner CG. Dental anthropology. Annu Rev Anthropol 1988; 17: 99-126.
11. Brabant H. Comparison of the characteristics and anomalies of the deciduous and the permanent dentition. J Dent Res 1967; 46: 897-902.
12. Kustaloglu OA. Paramolar structures of the upper dentition. J Dent Res 1962; 41: 75-83.
13. Dahlberg AA. The dentition of the American Indian. New York: Viking Fund. 1949.
14. Cleghorn BM, Boorberg NB, Christie WH. Primary human teeth and their root canal systems. Endod Topics 2012; 23: 6-33.
15. Aminabadi NA, Farahani RM, Gajan EB. Study of root canal accessibility in human primary molars. J Oral Sci 2008; 50: 69-74.
16. Bagherian A, Kalhori KA, Sadeghi M, Mirhosseini F, Parisay I. An in vitro study of root and canal morphology of human deciduous molars in an Iranian population. J Oral Sci 2010; 52: 397-403.
17. Tratman EK. Three rooted lower molars in man and their racial distribution. Br Dent J 1938; 64: 264-274.
18. Yang R, Yang C, Liu Y, Hu Y, Zou J. Evaluate root and canal morphology of primary mandibular second molars in Chinese individuals by using cone-beam computed tomography. J Formos Med Assoc 2013; 112: 390-395.
19. Carlsen O, Alexandersen V. Radix paramolarisis in permanent mandibular molars: identification and morphology. Scand J Dent Res 1991; 99: 189-195.
20. Vertucci FJ. Root canal anatomy of the human permanent teeth. Oral Surg Oral Med Oral Pathol 1984; 58: 589-599.
21. Ahmed HMA, Musale PK, El Shahawy OI, Dummer PMH. Application of a new system for classifying tooth, root and canal morphology in the primary dentition. Int Endod J 2020; 53: 27-35.
22. Fumes AC, Sousa-Neto MD, Leoni GB, Versiani MA, et al. Root canal morphology of primary molars: a micro-computed tomography study. Eur Arch Paediatr Dent 2014; 15: 317-326.
23. Erkman AC, Kaya F. Morphological variations of three-rooted mandibular molars in ancient Anatolian populations (Dilkaya Mound, Van, Turkey): A literature review on world populations. Mediterr Archaeol Archaeom 2014; 14: 1-11.
24. Mathew MG, Soni AJ. Prevalence of three-rooted primary mandibular first molars in Karnataka (South Indian) population. Int J Pedod Rehabil 2019; 4: 6-8.
25. Tu MG, Liu JF, Dai PW, Chen SY et al. Prevalence of three-rooted primary mandibular first molars in Taiwan. J Formos Med Assoc 2010; 109: 69-74.
26. Liu JF, Dai PW, Chen SY, Huang HL et al. Prevalence of 3-rooted primary mandibular second molars among chinese patients. Pediatr Dent 2010; 32: 123-126.
27. Nagaveni NB, Poornima P, Valsan A, Mathew MG. Prevalence of three-rooted primary mandibular second molars in Karnataka (South Indian) population. Int J Pedod Rehabil 2018; 3: 33-35.
28. Jorgensen KD. The deciduous dentition. A descriptive and comparative anatomical study. Acta. Odontol. Scand 1956; 14: 1-202.
29. Mayhall JT. Three-rooted deciduous mandibular second molars. J Can Dent Assoc 1981; 47: 319-321.
30. Song JS, Kim SO, Choi BJ, Choi HJ et al.. Incidence and relationship of an additional root in the mandibular first permanent molar and primary molars. Oral Surg Oral Med Oral Pathol Oral Radiol Endod 2009; 107: e56-e60.

Dental fluorosis severity in children 8-12 years old and associated factors

Alexandra Saldarriaga[1,2], Diego Rojas-Gualdrón[3], Manuel Restrepo[2], Lourdes Santos-Pinto[4], Fabiano Jeremias[1]

1. Universidade Estadual Paulista, São Paulo, Facultad de Odontologia de Araraquara, Programa de Pos-Graduación em Ciências Odontológicas, Araraquara-SP, Brasil
2. Universidad CES, Facultad de Odontología, Departamento de investigación, Medellín, Colombia
3. Universidad CES, Facultad de Medicina, Departamento de investigación., Medellín, Colombia
4. Universidade Estadual Paulista, São Paulo, Facultad de Odontologia de Araraquara, Departamento de Morfologia e Odontopediatria, Araraquara-SP Brasil.

ABSTRACT
The aim of this study was to determine the frequency and severity of dental fluorosis (DF) and the association between severity and risk factors. In a cross-sectional study, 8- to 12-year-old children, born in a Colombian district, were evaluated according to the Thylstrup and Fejerskov Index (TFI) by two calibrated examiners. Molar Incisor Hypomineralization (MIH) and dental caries (DC) were also evaluated. Ordinal logistic regression was applied (p<0.05). Risk factors and lifestyle factors were collected using a questionnaire answered by parents. DF was detected in 76 (98.7%) of the children (average of 18.4 ±1.81 permanent teeth affected). Grade TF2 was the most frequently observed (34.8%); TF5 was observed in all age groups; TF6-TF7 were observed in 12-year-olds. No association was found between DF severity and DC (Odds Ratio (OR)=1.35; 95%CI: 0.56-3.26) or MIH (OR=1.39; 95%CI: 0.43-4.46). DF severity was significantly associated with use of an indoor wood stove for food preparation (OR = 9.34; 95%CI: 1.11-78.57) and use of a pea-sized volume of toothpaste (OR = 27.42; 95%CI: 1.57-477.36). Prevalence of DC was 38.1% and prevalence of MIH was 14.4%. In this population, the frequency of DF was high and severity was associated with use of an indoor wood stove for food preparation and toothpaste amount used during childhood.

Received: March 2021; Accepted: May 2021.

Keywords: *dental fluorosis - severity - children.*

Severidad de fluorosis dental y factores asociados en niños de 8-12 años de edad

RESUMEN
El objetivo de este estudio fue determinar la prevalencia y severidad de la Fluorosis Dental (FD) y la asociación de la severidad con factores de riesgo. Mediante un estudio transversal, niños (8-12 años-de-edad), nacidos en Ayapel (El Cedro-Colombia) fueron evaluados por 2 examinadores calibrados, según los criterios del índice de Thylstrup y Fejerskov (TFI) para FD. También se evaluaron la Hipomineralización molar-incisiva (HMI) y la caries dental (CD). Se aplicó un cuestionario de factores de riesgo y estilo de vida, a los padres/responsables de los niños. Se utilizó un modelo de regresión logística ordinal (p<0.05). Se encontró FD en 76 (98.7%) niños (con una media de dientes permanentes afectados de 18.4 ±1.81). La severidad categoría TF2 fue la más observada (34.8%) en los dientes evaluados. Las lesiones que presentan pérdida estructural moderada TF 6-7, fueron evidenciadas en el grupo de edad de 12 años. No se encontró asociación entre la severidad y la CD (OR=1.35; IC95%:0.56-3.26) o con HIM (OR=1.39; IC95%:0.43-4.46). Se encontró una asociación significativa con la severidad de la FD en los niños que utilizaban fogón de leña-interno para la preparación de los alimentos (OR=9.34; IC95%:1.11-78.57) y utilizaban un volumen de crema dental del tamaño de una alverja-pequeña (OR=27.42; IC95%:1.57-477.36). la prevalencia de CD fue 38.1% y de HMI fue 14.4%. La frecuencia de la FD fue alta y la severidad mostró correlación con la utilización de fogón de leña interno para la preparación de los alimentos y la cantidad de crema-dental utilizada.

Palabras clave: *fluorosis dental - severidad - niños.*

INTRODUCTION

Dental fluorosis (DF) is an endemic disease in various parts of the world[1-3]. Its etiology is directly related to an increased total amount of fluoride (F) ingested from various sources during the amelogenesis period[4,5]. Multiple sources of F have the potential to cause DF, including natural F, artificial F or F added to water, dental products, cooking salt, milk and dietary supplements, and exposures related to occupation or lifestyle. However, the intake of F in water is considered to be the main cause of DF[5-7].

There are other forms of DF in which other factors are involved; for example, in China, foods such as tea, corn, and chili cooked for a long time and at high temperatures in coal and mud stoves have been associated with DF[1,3,8-10]. Other parts of the world, such as India (64.3%)[11], Nigeria (26.1–51.0%)[12], Mexico (83.8%)[13] and Brazil (8.53–80.4%)[14], have low normal concentrations of F in water, but high prevalence of DF due to the artificial addition of F to the water. Other associated factors include the frequency of tooth brushing, the time elapsed between the emergence of the first tooth and the use of toothpaste[15,16] and F added to common topical agents[4,9]. The varying socioeconomic, environmental, hydrochemical, and individual factors lead to differences in F exposure across countries, regions, and districts, and therefore to different degrees of severity of Dental Fluorosis. The increasing use of F as a caries-preventive agent in populations with different degrees of exposure to F has sparked controversies regarding the risk-benefit and dosage of F, which warrant further research. The clinical and epidemiological diagnosis of DF could be monitored in different scenarios and subgroups of specific endemic communities or individuals who share the same conditions, lifestyle, and social and environmental settings. The endemic characteristics provide indications for DF severity and its association with demographic factors, oral hygiene habits, and individual child-related factors[17]. It is important to identify all of the risk factors as well as to detect the disease early, chiefly during primary dentition, to prevent fluorosis in permanent dentition[18]. Thus, clinical detection of fluorosis, identification of its causes and differential diagnosis are essential for the clinical management of affected patients. Epidemiological knowledge of the disease is important for determining actions to promote oral health and may contribute to preventing it in future generations. The aim of the present study was to identify the presence of dental fluorosis among 8- to 12-year-old children and establish its severity and association with dental caries (DC), Molar Incisor Hypomineralization (MIH), medical/dental history, and factors related to lifestyle, in an isolated rural community where there is concern about DF and its severity.

MATERIAL AND METHODS

This study was designed following the STROBE (Strengthening the Reporting of Observational Studies in Epidemiology) guidelines as a cross-sectional study on a sample of 77 children aged 8 to 12 years in El Cedro (Northern Colombia). The population consisted of 929 inhabitants who have been covered since 1989 by the public health program in Colombia for the fluoridation of cooking salt (180–220 ppm). The area has an average water F concentration of 0.10 ppm, temperature 32.7°C, elevation above sea level 40 meters. It receives water from a natural well, does not have a municipal aqueduct for water treatment, and also has river access. Data were collected in August 2018.

Subjects included in the study were 8- to 12-year-old children born in Ayapel in the El Cedro district, who had at least the first permanent molars and permanent upper and lower incisors erupted. Exclusion criteria were presence of syndromes linked to enamel malformations, dental enamel defects caused by trauma, and use of orthodontic appliances.

Among 220 children invited to participate in this study, 77 were examined. A total 143 children were not examined due to absence of permanent maxillary lateral incisors (12), not having parental informed consent (28) or absence from school on the examination day as a result of the geographic situation of the scattered population. The results are presented for 76 participants that had DF at the time of the clinical evaluation. Only one examined child did not present DF.

A post hoc power analysis determined that with a Type-I error rate = 5% and 40% controls exposed, the sample of 76 participants has statistical power ≥80% for OR ≥2.3 (or OR ≤0.44).

The clinical evaluations were performed in a dental office equipped with artificial light and a suction, water and air system, using a dental mirror and periodontal probe, as recommended by the World

Health Organization (WHO). After cleaning and drying the teeth, the complete examination was conducted by two evaluators calibrated for the diagnosis of DF as primary outcome (intra-examiner kappa = 0.89; inter-examiner kappa = 0.87) according to the criteria proposed by Thylstrup and Fejerskov (TFI)[19]. Molar incisor hypomineralization (MIH) was diagnosed based on the criteria of the European Academy of Pediatric Dentistry (EAPD)[20]. Dental caries (DCs) in permanent teeth was evaluated using the DMFT index (decayed, missing, and filled teeth), following the WHO criteria[21]. Differential diagnosis with other non-fluorotic enamel opacities and white spots was based on the criteria proposed by Seow[22] (Kappa> 0.85). For the inter-examiner calibration, 20 children from each age group were evaluated and 10 children were selected at random for intra-examiner calibration. The trained staff applied a semi-structured questionnaire to all children's parents or guardians to assess economic factors, oral hygiene habits, and other individual factors and environmental aspects, for evaluation of the secondary outcome.

Ethical approval

This study was previously approved by the Institutional Committee for Research Ethics in Human Beings of the CES University (Medellín, Colombia) (Certificate No. 110-Code 718). Parents signed consent to approve their children's participation. Children underwent psychological evaluation before parents signed the consent.

Statistical analysis

The data was processed in STATA program version 16® (College Station, TX). In the descriptive analysis, frequencies and percentages were used for categorical variables, while measures of central tendency and dispersion were used for quantitative variables. The results for DF are described according to Fejerskov et al.[23]. The factors associated with DF severity were analyzed by ordinal logistic regression. DF severity according to TF categories (TFI 0-9)[19] is an ordinal variable and was the response variable. We estimated crude Odds Ratios (OR) with simple regression models and adjusted OR with a multiple regression model. For adjustment estimations, variables with p <0.25 were included using the enter method. OR are presented with 95%CI and p values. According to the Hosmer-Lemeshow goodness-of-fit test for ordinal logistic regression, the multivariate model presented in the results showed a good fit to the data (p=0.733). Additionally, a Pulkstenis-Robinson test was performed for each variable to assess the assumption of proportionality of the Odds, obtaining positive results.

RESULTS

This study evaluated 77 children between 8 and 12 (10.2 ± 1.99) years of age in the El Cedro district. The prevalence of DF was 98.7%. The analysis included only the 76 children with DF (TFI ≥ 1). Distribution of the study population according to sex, age, TFI, DMFT, MIH, and other individual variables is presented in Table 1. The prevalence of DC was 38.1%. Mean DMFT was 0.82 (SD 1.27). The mean decay component was 0.38 (SD 0.81), and the filled component was 0.44 (SD 0.98). No statistically significant difference in the prevalence of DF was observed between boys and girls (p = 0.33). In these children, the maximum TFI was TF7, with TF3 (48.6%) being the most frequent, followed by TF2 (22.3%).

Assessment of economic conditions revealed that 72.37% of the children's families did not receive a family income. The water used for food preparation was obtained through the faucet in their homes via a well (50%), and 44.74% used an outdoor wood stove.

With regard to distribution of teeth affected by DF according to age and severity (TFI)[23] (Table 2), TF1–TF3 were the most commonly observed grades at the tooth level, most frequently TF2 (34.8%). Lesions presenting TF5 loss of structure were observed in all age groups, while TF6–TF7 lesions were mainly seen in the teeth of children in the 12-year-old group. There was no association between increasing age and DF severity (p≥0.05). In this study, 18.4 ± 1.81 permanent teeth were affected per child.

Fig. 1 shows the proportions of affected teeth for each child according to the TFI scale [23]. TF≥1, ≥2, ≥3, ≥4, and ≥5 were observed in 98.78%, 89.59%, 68.47%, 19.76%, and 17.11%, respectively, of the children examined. Likewise, 82.96% and 17.13% of the children had, in at least 50% of their teeth, TF≥1 and ≥3 respectively, and 26% had TF ≥5 in 1.32% of their teeth.

According to type of tooth, TF1 diagnosis was the most common in the upper and lower central and lower lateral incisors. TF2 diagnosis was the most

Table 1. Distribution of the characteristics of 8- to 12-year-old children with DF. El Cedro, Colombia, 2018

Variable		n(%)
Sex	Male	37 (48.6)
	Female	39 (51.3)
Age (years)	8	11 (14.4)
	9	17 (22.3)
	10	12 (15.7)
	11	17 (22.3)
	12	19 (25.0)
TF	1	7 (9.2)
	2	17 (22.3)
	3	37 (48.6)
	4	2 (2.6)
	5	11 (14.4)
	6	1(1.32)
	7	1 (1.32)
DMFT	0	47 (61.84)
	≥1	29 (38.16)
MIH	0	65 (85.5)
	>0	11 (14.4)
Start of brushing (age, years)	≤3	50 (65.79)
	>3	26 (34.21)
Toothbrushing (times per day)	1	25 (32.89)
	2	35 (46.05)
	3	16 (21.05)
Toothpaste amount	Minimum	3 (3.95)
	Small layer	25 (32.89)
	Pea-sized volume	35 (46.05)
	More than pea-sized volume	13 (17.11)
Toothpaste type	Children's	34 (44.74)
	Adult	38 (50.00)
	Both	4 (5.26)
Swallows toothpaste	Yes	42 (55.26)
	No	34 (44.73)
Milk type	Mother's milk	70 (92.11)
	Infant formula	4 (5.26)
	Cow's milk	2 (2.64)
Water source	Aqueduct, untreated	38 (50.0)
	Well	38 (50.0)
Oven type	Electric	6 (7.89)
	Gas	21 (27.63)
	Indoor, wood-fired	15 (19.75)
	Outdoor, wood-fired	34 (44.74)
Family income	No income	55 (72.37)
	Minimum income	21 (27.64)

Abbreviations: TF, Thylstrup and Fejerskov criteria; DMFT, decayed, missing, and filled teeth; MIH, molar incisor hypomineralization

Table 2. Frequency of teeth with DF, according to severity and age. El Cedro, Colombia, 2018.

	Classification of severity (Thylstrup and Fejerskov, 1988)[23*]						
Age (years)	**TF1**	**TF2**	**TF3**	**TF4**	**TF5**	**TF6**	**TF7**
	n (%)	**n (%)**	**n (%)**	**n (%)**	**n (%)**	**n (%)**	**n (%)**
8	52 (11.5)	33 (6.8)	39 (9.8)	1 (11.1)	2 (6.7)	-	-
9	89 (19.6)	77 (15.8)	60 (15.0)	-	13 (43.3)	1 (8.3)	-
10	67 (14.8)	86 (17.7)	68 (17.0)	-	1 (3.3)	-	-
11	115 (25.4)	125 (25.7)	124 (31.1)	1 (11.1)	3 (10.0)	-	-
12	130 (28.7)	165 (3.0)	108 (27.1)	7 (77.8)	11 (36.7)	11(91.7)	9 (100.0)
Total n(%)	453 (32.4)	486 (34.8)	399 (28.5)	9 (0.6)	30 (2.2)	12 (0.9)	9 (0.6)

*TF1: soft white lines.
TF2: small cloudy areas
TF3: hazy areas of opacity and white lines
TF4: entire surface has opacity (white limestone).
TF5: opaque surface with rounded depressions less than 2 mm in diameter.
TF6: small depressions fuse into opaque enamel, forming bands less than 2 mm in vertical height, including canine fracture of vestibular enamel less than 2 mm.
TF7: loss of external enamel in irregular areas and less than half of the surface involved. The remaining intact enamel is opaque.

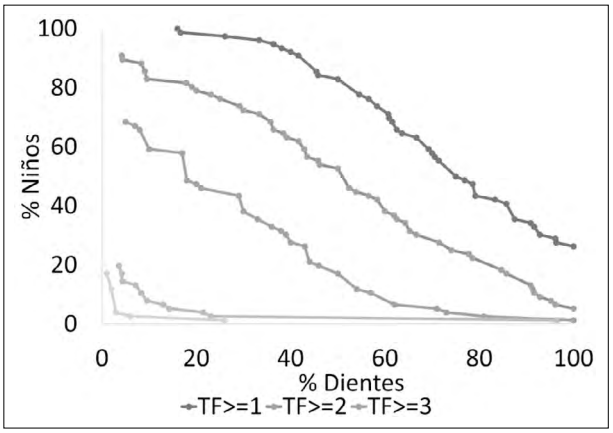

Fig. 1: Distribution curve of the cumulative frequency of the proportion of teeth per child according to Thylstrup and Fejerskov index score (TFI) ≥1, 2, 3, 4, and 5, respectively, in 8- to 12-year-old children.

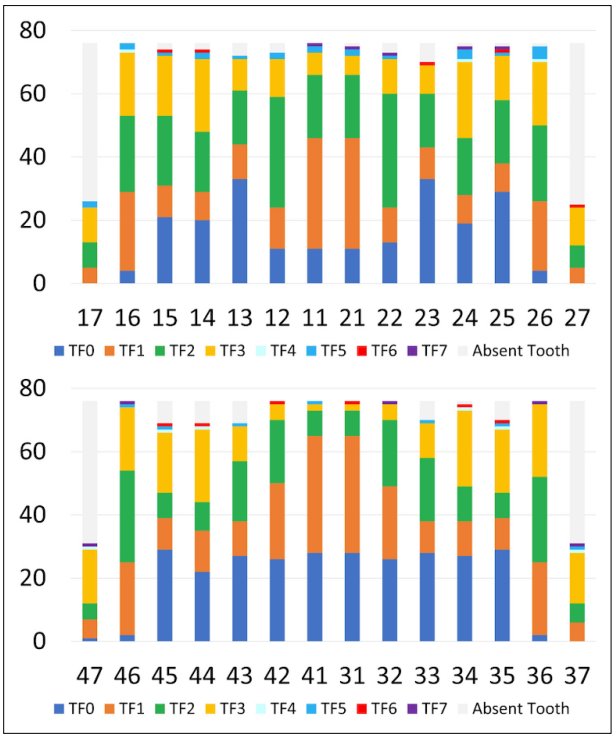

Fig. 2: Distributions of the percentages of teeth with dental fluorosis according to severity and dental arch. Upper and Lower permanent teeth.

frequent in the upper lateral incisors and permanent first molars. TF3 predominated in the permanent second molars. Comparisons of upper and lower arches showed a moderately strong correlation in severity between arches (rho = 0.693, $p < 0.001$) (Fig. 2).

The associations between the study variables and DF severity (maximum TFI score) among the children included in this study are presented in Table 3. The raw results of the bivariate analysis showed no difference in severity according to age ($p = 0.65$). While higher odds of severity were observed in boys than in girls (OR = 1.13; 95%CI: 0.49–2.63), the difference was not significant. No association was observed between DF severity and the presence of DC (OR = 1.35; 95% CI: 0.56-3.26) or MIH (OR = 1.39; 95%CI: 0.43–4.46); however, there were significant differences in children who brushed their teeth three times a day (OR = 4.05; 95%CI: 1.22–13.44), children with families with minimum-wage income (OR=2.95; 95%CI: 1.14–6.67), and those who used water from the well (OR = 2.76;

Table 3. Correlation of the children's characteristics and dental fluorosis severity. El Cedro, Colombia, 2018.

Variable		Raw odds (95%CI)	p-value	Odds Adjusted (95%IC)	p-value
Sex	Female	1		1	
	Male	1.13 (0.49–2.63)	0.77	0.93 (0.35–2.43)	0.88
Age		0.93 (0.69–1.27)	0.65		
DMFT	DMFT = 0	1			
	DMFT ≥ 1	1.35 (0.56–3.26)	0.5		
MIH	MIH=0	1			
	MIH>0	1.39 (0.43–4.46)	0.57		
Start of brushing (age, years)	≤ 3	1			
	> 3	0.95 (0.39–2.29)	0.91		
Toothbrushing (times per day)	1	1		1	
	2	1.20 (0.46–3.12)	0.71	0.74 (0.21–2.62)	0.65
	3	4.05 (1.22–13.44)	0.02	2.45 (0.61–9.83)	0.2
Toothpaste amount	Minimum	1		1	
	Smear	5.12 (0.55–47.51)	0.15	16.25 (0.94–278.21)	0.05
	Pea-sized volume	7.36 (0.82–66.13)	0.08	27.42 (1.57–477.36)	0.02
	More than a pea-sized volume	2.86 (0.28–28.97)	0.37	12.52 (0.61–256.65)	0.1
Toothpaste type	Children's	1		1	
	Adult	0.49 (0.20–1.18)	0.11	0.29 (0.09–0.98)	0.046
	Both	0.57 (0.10–3.34)	0.53	0.42 (0.05–3.48)	0.42
Swallows tooth-paste	Yes	1			
	No	0.89 (0.36–2.16)	0.79		
Milk type	Mother's milk	1		1	
	Infant formula	1.55 (0.25–9.81)	0.64	1.27 (0.12–13.10)	0.83
	Cow's milk	15.39 (0.57–418.93)	0.11	32.25 (0.76–1360.74)	0.06
Water source	Aqueduct, untreated	1		1	
	Well	2.76 (1.14–6.67)	0.02	1.89 (0.67–5.36)	0.22
Oven type	Electric	1		1	
	Gas	4.84 (0.89–26.45)	0.07	2.36 (0.33–16.57)	0.38
	Indoor, wood-fired	9.62 (1.58–58.50)	0.01	9.34 (1.11–78.57)	0.04
	Outdoor, wood-fired	5.68 (1.10–29.33)	0.04	4.57 (0.73–28.25)	0.1
Family income	No income	1		1	
	With minimum income	2.95 (1.14–6.67)	0.03	2.83 (0.84–9.48)	0.09

Abbreviations: DMFT, decayed, missing, and filled teeth; MIH, molar incisor hypomineralization

95%CI:1.14–6.67) and an indoor (OR = 9.62; 95%CI: 1.58–58.50) or outdoor (OR = 5.68; 95%CI: 1.10–29.33) wood stove for food preparation ($p < 0.05$). When adjusting for multiple regression, only two variables explained DF severity: use of a pea-sized volume of toothpaste (OR = 27.42; 95%CI: 1.57–477.36) and use of an indoor wood stove for food preparation (OR = 9.34; 95%CI: 1.11–78.57, $p < 0.05$).

Other perinatal variables, such as low birthweight, preterm delivery, jaundice, high fever, antibiotics taken by the child, medications in the mother, F supplements, and previous information on DF were not associated with DF severity ($p \geq 0.05$).

DISCUSSION

The prevalence of DF in this study population (98.7%) was greater than the overall prevalence in Colombia (62.15%)[24]; and similar to that in a recent report from another area of southern Colombia, which found that 98.2% of the children are affected according to TFI criteria[25].

Almost 100% of the 8- to 12-year-old children in this community had DF, a prevalence higher than those in other countries with fluoridated water, such as the USA (65.0%) [26], in endemic areas due to groundwater such as Kenya (86.0% in children under 14 years) [27], or in rural endemic areas of Brazil with similar climatic conditions to those in the present study (80.4%)[14], Thailand (18.4%)[16], and areas of Nigeria (11.3% of children 12 to 15 years old)[12].

This study classified the children according to the highest value of the 10-degree TFI severity scale[23]. TF3 score (of esthetic concern) was the most frequent, similar to the report by Gevera et al.[27], but in contrast to Conway et al.[28], who report a higher prevalence of TF1-TF2 in 7- to 9-year-old children, and Armas-Vega et al.[29], who report a higher prevalence of TF2 in 10- to 12-year-old children.

Comparisons of DF severity as mild, moderate, or severe should consider both the criteria used to measure DF and subject age. The severity in the present study was higher than in other reports using Dean's criteria. In the USA, moderate and severe DF are observed in 28% and 2.6%, respectively, of children 12 to 15 years old[26]. In Nigeria, 9.25% of subjects have very mild, 1.25% mild, and 0.75% moderate lesions, with no report of severe DF lesions [12]. In Thailand, 16.15% and 2.3% of children 8 to 10 years old present very mild and mild lesions, respectively, with no severe lesions[16]. Bhagavatula et al.[4] report mainly mild DF, with less than 1% of subjects having severe DF.

No significant difference was found in the degree of severity between teeth in the upper and lower arches, in contrast to the study by Larsen et al. [30], who reports variability in the risk period for DF in the upper and lower jaw teeth when examined separately. Although Bhagavatula et al.[4] did not measure individually, they report similar periods of development for each type of tooth in both arches.

Regarding severity according to tooth type, although the differences were not statistically significant, the findings of the present study show how the time of exposure to accumulated F and the time of tooth formation and mineralization[4] can be reflected in the severity. In permanent teeth that erupt early, such as the central incisors of both arches and the lower lateral side (development in the first 4 years of life), there was a predominance of TF1 severity, followed by the upper lateral incisors and the first molar with predominance of TF2 and the second molars and premolars (development at 5-8 years of age) with TF3. However, other factors must be considered, such as the effect of abrasion and brushing on milder lesions and on teeth such as the central incisors that are most exposed, as well as other conditions at the time of clinical examinatio [4,31].

Although we observed no significant relationship between DF severity and age and sex, among the few studies that have also analyzed the factors associated with severity, our findings are consistent with those published by Pontigo-Loyola et al.[13], who report no association between severity and sex, and differ from those of Ferreira et al.[14], who report an association between age and severity ($p<0.05$). Other studies present differences in the prevalence of DF according to sex[29], while still others report no significant association between DF and age, sex, or socioeconomic status[12]. Considering economic situation, the population of the present study is vulnerable, with only 25.32% of the families receiving a minimum wage and with 3–7 individuals in 81.58% of the families. However, with the economic factor in this population treated as a constant, the bivariate analysis showed a correlation with minimum-wage family income ($247 USD), although the severity was explained by other variables ($p = 0.09$) in the adjusted analysis. Other studies report correlations between socioeconomic status and DF, observing a relationship between higher income and being able to afford to buy toothpaste and other topical fluorides[16,28,29,32].

Among the statistically significant factors in the present study ($p <0.05$), the amount of toothpaste (pea-sized volume) used was associated with severity, though the use of more than a pea-sized volume did not present an association, but since its OR=12.52 was high, it was probably not significant because very few children used it (n=13). These results should be interpreted with caution due to their low power. On the other hand, the OR of adult toothpaste seems to be protective. However, an OR below the unit does not always mean protection,

it could also be more prone to severity and in this population could be associated with other biological variables or biochemical components that were not considered in this study.

Other variables such as starting tooth brushing before the age of 3 years, the frequency of brushing, the type of toothpaste and swallowing the toothpaste during childhood have been related to the prevalence of the DF in other studies[4,6,15,26,29], although they were not related to the severity of the DF in the current study.

Although 92.11% of the children in the present study had been breastfed, drinking cow's milk was related to DF severity (p = 0.06 in the adjusted analysis). Other reports suggest that while cow's milk has a low F content, the concentration can be increased with the use of infant formulas, processed foods and beverages with fluoridated water [26], as well as fluorinated salt.

In the present study, a correlation was observed between DF severity and children who received food prepared in an indoor wood stove in their homes. The study population uses fluoridated salt and 59.21% of families use between 1 and 2 tablespoons of salt when preparing food. The study population lives at an altitude of 40 meters above sea level and there was high prevalence of more severe DF than in populations from other areas at different altitudes. Food preparation and altitude are identified as risk factors in other studies; the latter, especially, may act as a modifying factor for the prevalence and severity of DF, although there is no solid evidence [3,10,13,33,34]. Regarding food preparation, in some parts of China, Fawell et al.[2] report high fluoride concentrations in indoor air as a result of the use of fluoride-rich coal for drying, curing and cooking food. Other studies report an increase in fluoride concentration when food and water are boiled for a long time and when boiled water is used for reconstituting infant formulas[16,35]. This is often the case in communities that use indoor wood stoves. But again, there is little evidence in this regard.

The lack of conclusive evidence for risk factors for DF or its severity is clear, indicating the need for further studies on larger samples[15] to identify other factors that could modify or multiply the effect or exposure to F[13,26]. DF was found to be high in 8- to 12 -year-old children in the population of El Cedro. There may be other explanatory factors that have not been studied in the area, including environmental sources, presence of metals or minerals, malnutrition or micronutrient deficiency, genetic factors and other sources of fluoride such as food, snacks and topical fluoride applications.

This study has some limitations. A consequence of the low sample size is that the estimates of some confidence intervals of the OR are broad and the results should therefore be interpreted with caution. We had a low response rate (35%). El Cedro is a remote rural community with low accessibility, which explains school absences and the difficulty to obtain informed consent from parents. Moreover, there may be memory bias in parents' answers to the questions on perinatal variables. The strength of the study was that all permanent teeth present were analyzed, individually and separately, in both arches. Despite research obstacles, characterizing DF and associated factors in this kind of community is highly relevant to provide information to support oral health improvements.

CONCLUSION

The rural community evaluated presented a high frequency of DF. The association between DF severity and the type of tooth provides evidence of the large window of susceptibility and its association with the accumulated exposure to F, with less involvement and lower severity in the lower incisors. The main factors related to DF severity in 8- to 12- year-old children were the use of an indoor wood stove for food preparation and the amount of toothpaste used in childhood.

ACKNOWLEDGMENTS

The authors would like to thank Dr. Alfonso Escobar for allowing access to the community.

DECLARATION OF CONFLICTING INTERESTS

The authors declare no potential conflicts of interest regarding the research, authorship, and/or publication of this article

FUNDING

This work was supported by the CES University in Medellin Colombia (INV032017008).

CORRESPONDENCE

Prof. Dr. Fabiano Jeremias
Facultade de Odontologia de Araraquara, Programa de Pos-graduación em Ciências Odontológicas.
Universidade Estadual Paulista, São Paulo (Unesp), Araraquara-SP Brasil.
Rua Humaitá, 1680 Araraquara, SP Brasil 14801-903
f.jeremias@unesp.br

REFERENCES

1. Ibrahim Y, Abuaffan A, Bjorvatn K. Prevalence of dental fluorosis in Sudanese children from two villages with 0.25 and 2.56 ppm fluoride in the drinking water. Int J Paediatr Dent. 1995;5:223-229.
2. Fawell JK, Bailey K, editors. Fluoride in drinking-water. London ; Seattle: IWA Pub; 2006. URL: http://www.who.int/water_sanitation_health/publications/fluoride_drinking_water_full.pdf
3. Rwenyonyi C, Bjorvatn K, Birkeland J, Haugejorden O. Altitude as a risk indicator of dental fluorosis in children residing in areas with 0.5 and 2.5 mg fluoride per liter in drinking water. Caries Res. 1999;33:267-274.
4. Bhagavatula P, Levy SM, Broffitt B, Weber-Gasparoni K, Warren J. Timing of fluoride intake and dental fluorosis on late-erupting permanent teeth. Community Dent Oral Epidemiol. 2016;44:32-45.
5. Buzalaf MAR, Pessan JP, Honório HM, Ten Cate JM. Mechanisms of action of fluoride for caries control. Monogr Oral Sci. 2011;22:97-114.
6. Celeste R, Luz P. Independent and additive effects of different sources of fluoride and dental fluorosis. Pediatr Dent. 2016;38:233-238.
7. Den Besten P, Li W. Chronic fluoride toxicity: dental fluorosis. Monogr Oral Sci. 2011;22:81-96.
8. Lyaruu DM, Medina JF, Sarvide S, Bervoets TJM, Everts V, Denbesten P, et al. Barrier formation: potential molecular mechanism of enamel fluorosis. J Dent Res. 2014;93:96-102.
9. Pérez-Pérez N, Irigoyen-Camacho ME, Boges-Yañez AS. Factors affecting dental fluorosis in low socioeconomic status children in Mexico. Community Dental Health. 2017;34:66-71.
10. Fan Z, Gao Y, Wang W, Gong H, Guo M, Zhao S, et al. Prevalence of brick tea-type fluorosis in the Tibet Autonomous Region. J Epidemiol. 2016;26:57-63.
11. Mahantesh T, Dixit UB, Nayakar RP, Ashwin D, Ramagoni NK, Kamavaram Ellore VP. Prevalence of dental fluorosis and associated risk factors in Bagalkot District, Karnataka, India. Int J Clin Pediatr Dent. 2016;9:256-263.
12. Okoye LO, Ekwueme O-EC, Sote EO, Amaechi BT. Prevalence of dental fluorosis among 12-15-year-old students in Enugu Metropolis, Nigeria. Indian J Dent Res Off Publ Indian Soc Dent res. 2019;30:462-467.
13. Pontigo-Loyola AP, Islas-Márquez A, Loyola-Rodríguez JP, Maupome G, Marquez-Corona ML, Medina-Solis CE. Dental fluorosis in 12- and 15-year-olds at high altitudes in above-optimal fluoridated in Mexico. J Public Health Dent. 2008; 68:163-166.
14. Ferreira EF, Vargas AMD, Castilho LS, Velásquez LNM, Fantinel LM, Abreu MHNG. Factors associated to endemic dental fluorosis in Brazilian rural communities. Int J Environ Res Public Health. 2010;7:3115-3128.
15. Azevedo MS, Goettems ML, Torriani DD, Demarco FF. Factors associated with dental fluorosis in school children in southern Brazil: a cross-sectional study. Braz Oral Res. 2014; 28:S1806-83242014000100220.
16. Nakornchai S, Hopattaraput P, Vichayanrat T. Prevalence, severity and factors associated with dental fluorosis among children aged 8-10 years in Bangkok, Thailand. Southeast Asian JTrop Med Public Health. 2016; 47:1105-1111.
17. European Commission, Directorate General for Health & Consumers, SCHER. Critical review of any new evidence on the hazard profile, health effects, and human exposure to fluoride and the fluoridating agents of drinking water. URL: https://ec.europa.eu/health/scientific_committees/environmental_risks/docs/scher_o_139.pdf
18. Molina-Frechero N, Gaona E, Angulo M, Sánchez Pérez L, González González R, Nevarez Rascón M, Bologna-M. Fluoride Exposure Effects and Dental Fluorosis in Children in Mexico City. Medical Science Monitor 2015;21:3664-70.
19. Thylstrup A, Fejerskov O. Clinical appearance of dental fluorosis in permanent teeth in relation to histological changes. Community Dent Oral Epidemiol. 1978;6:315-328.
20. Weerheijm K, Duggal M, Mejàre I, Papagiannoulis L, Koch G, Marten L, et al. Judgement criteria for molar incisor hypomineralisation (MIH) in epidemiologic studies: a summary of the European meeting on MIH held in Athens, 2003. Eur J Paediatr Dent. 2003;4:110-113.
21. World Health Organization (WHO). Oral Health Surveys. Basic Methods. France: WHO Library Cataloguing-in-Publication Data; 2013.
22. Seow WK. Clinical diagnosis of enamel defects: pitfalls and practical guidelines. International Dental Journal 1997;47:173-182.
23. Fejerskov O, Manji F, Baelum V, Møller IJ. Dental fluorosis a handbook for health workers. Copenhagen: Munksgaard; 1988.p. 123 .
24. Colombia. Ministerio de Salud y Protección Social. IV estudio nacional de salud bucal ENSAB IV: situación de salud bucal URL: https://www.minsalud.gov.co/sites/rid/Lists/BibliotecaDigital/RIDE/VS/PP/ENSAB-IV-Situacion-Bucal-Actual.pdf.
25. Martignon S, Opazo-Gutierrez MO, Velasquez-Riaño M, Orjuela-Osorio I, Avila V, Martinez-Mier E, et al. Geochemical characterization of fluoride in water; table salt, active sediment, rock and soil samples, and its possible relationship with the prevalence of enamel fluorosis in children in four municipalities of the department of Huila (Colombia). Environmental Monitoring and Assessment 2017;89:264.
26. Neurath C, Limeback H, Osmunson B, Connett M, Kanter V, Wells C. Dental Fluorosis Trends in US Oral Health Surveys: 1986 to 2012. JDR Clin Transl Res. 2019;4:298-308.
27. Gevera P, Mouri H, Maronga G. Occurrence of fluorosis in a population living in a high-fluoride groundwater área: Nakuru area in the Central Kenyan Rift Valley. Environ Geochem Health 2019;41:829-840.
28. Conway DI, MacPherson LMD, Stephen KW, Gilmour W, Petersson LG. Prevalence of dental fluorosis in children from non-water-fluoridated Halmstad, Sweden: fluoride toothpaste uses in infancy. Acta Odontol Scand. 2005;63:56-63.
29. Armas-Vega A, Gonzalez–Martinez F, River-Martinez M, Mayorga-Solórzano M, Banderas-Benítez V, Guevara-Cabrera O. Factors associated with fluorosis in three zones of Ecuador. J Clin Expl Dent. 2019;11:42-48.
30. Larsen MJ, Richards A, Fejerskov O. Development of dental

fluorosis according to age at start of fluoride administration. Caries Res. 1985;19:519-527.
31. Escobar Rojas A, Bullio Fragelli CM, Girotto Bussaneli D, Patrícia Cavalheiro J, Santos-Pinto L, Restrepo M, et al. Clinical aspects of dental fluorosis according to histological features: a Thylstrup Fejerskov index review. CES Odontol. 2017; 30:41-50.
32. Angulo M, Cuitiño E, Molina-Frechero N, Emilson CG. The association between the prevalence of dental fluorosis and the socio-economic status and area of residence of 12-year-old students in Uruguay. Acta Odontol Scand. 2019;78:26-30.
33. Martínez-Mier EA, Soto-Rojas AE, Ureña-Cirett JL, Katza BP, Stookey GK, Dunipace AJ, et al. Dental fluorosis and altitude: a preliminary study. Oral Health Prev Dent. 2004;2:39-48.
34. Akosu TJ, Zoakah AI, Chirdan OA. The prevalence and severity of dental fluorosis in the high and low altitude parts of Central Plateau, Nigeria. Community Dental Health. 2009;26:138-42.
35. Grimaldo M, Borja-Aburto VH, Ramírez AL, Ponce M, Rosas M, Díaz-Barriga F. Endemic fluorosis in San-Luis-Potosi, Mexico. Identification of risk factors associated with human exposure to fluoride. Environ Res. 1995;68:25-30.

Efficacy of different instruments for the mechanical removal of the smear layer in immediate post preparations: a comparative study

Marcela L. Roitman, Laura B. Pinasco, Romina Loiacono, Valeria C. Panetta, Carolina A. Anaise, Pablo A. Rodríguez

Universidad de Buenos Aires. Facultad de Odontología. Cátedra de Endodoncia. Buenos Aires, Argentina

ABSTRACT

Adhesively cemented fiber-reinforced composite posts are commonly used to reconstruct endodontically treated teeth. Adhesion to intraradicular dentin is complex, and close contact between the resin cements and the dentin is essential. The removal of the smear layer following post space preparation (secondary smear layer) can improve this integration. Different mechanical systems have been used to activate the irrigant inside the root canal. The purpose of this study was to compare, ex-vivo, the removal of the smear layer from the walls of the immediate post space preparation by the action of three mechanized instruments. Forty premolar specimens with a single root canal were selected, endodontically treated, and shaped for glass fiber post cementation with Peeso reamer #1 (Dentsply Sirona, Switzerland) and Macrolock finishing drill #3 (RTD, France). The specimens were randomly divided into 4 groups (n=10): Group C (control); Group PUI (passive ultrasonic irrigation); Group CEP (Rotoprox brush, Hager Werken, Germany) and Group XP (XP-endo Finisher, FKG Dentaire, Switzerland). Post space surfaces were cleaned with 3mL of distilled water; each specimen root split longitudinally to expose the root canals, and prepared for examination in a scanning electron microscope at magnification 350X. The results were analyzed using the Kruskal-Wallis and Friedman tests (p>0.05). RESULTS: Statistically significant differences (p <0.05) were found between Groups C and XP in all three root regions, but not between Groups C, CEP and PIU. Of these, Group CEP showed a better trend in the results of the coronary and middle thirds, without significant difference with Group XP. Although it was difficult to achieve a clean dentin surface after preparation for the fiberglass post, the XP-endo Finisher was the most efficient in removing secondary smear layer, followed by the Rotoprox conical brush.

Received: September 2020; Accepted May 2021.

Keywords: *Endodontics - Smear Layer - Root Canal Preparation.*

Eficacia de diferentes instrumentos para la remoción mecánica del barro dentinario en preparaciones inmediatas para poste: estudio comparativo

RESUMEN

La fijación adhesiva de postes de fibra es un procedimiento habitual en la rehabilitación de piezas tratadas endodónticamente. La adhesión a dentina radicular resulta compleja, y es fundamental el íntimo contacto entre el medio resinoso y el sustrato dentinario. La eliminación del barro dentinario posterior a la preparación del anclaje intrarradicular podría mejorar esta integración. Para lograr una adecuada limpieza, se han implementado diferentes sistemas mecánicos para la activación del irrigante en el interior del conducto radicular.

El objetivo del presente trabajo fue comparar ex-vivo la remoción del barro dentinario de las paredes de la preparación inmediata para poste por acción de tres instrumentos mecanizados. Se utilizaron 40 premolares inferiores unirradiculares tratados endodónticamente y preparados para anclaje intrarradicular con fresa Largo #1 (Dentsply Sirona, Suiza) y fresa piloto del sistema Macrolock Azul (RTD, Francia). Las piezas fueron divididas aleatoriamente en grupos (n=10): GC (control); G PIU (irrigación pasiva ultrasónica); G CEP (cepillo Rotoprox cónico, Hager Werken, Alemania) y G XP (XP-endo Finisher, FKG Dentaire, Suiza). Las preparaciones fueron irrigadas con 3ml de agua destilada; las piezas fueron seccionadas longitudinalmente en sentido proximal, metalizadas y observadas al microscopio electrónico de barrido a 350X. Las imágenes fueron analizadas bajo categorización ordinal y mediante las pruebas de Kruskall - Wallis y Friedman, estableciendo un p>o,o5. Existió diferencia significativa (p<0,05) entre el grupo G C y G XP en todos los tercios radiculares, pero no entre G C, G CEP y G PIU. Entre estos grupos, el G CEP marcó una tendencia a mejores resultados en tercio coronario y medio sin diferencia significativa con el G XP. A pesar de la dificultad para lograr una superficie dentinaria limpia luego de preparaciones para poste, el XP- endo Finisher fue el más eficiente en la remoción del barro dentinario secundario, seguido por el cepillo cónico Rotoprox.

Palabras clave: *endodoncia - barro dentinario - preparación del conducto.*

INTRODUCTION

Adhesive bonding of fiber-reinforced resin posts is a usual procedure in the rehabilitation of endodontically treated teeth[1].

Bonding to root dentin is complex, and requires close contact between the resin cement and the dentin substrate. Root post space preparation with Gates Glidden and pilot burs produces a large amount of secondary smear layer made up of remains of endodontic sealer, gutta-percha plasticized by frictional heat, and inorganic components[2]. This thick smear layer covering root canal walls jeopardize the effective adhesion of the cement[3,4], even more when self-etching resin-based cements are used with adhesive protocols that do not include rinses and are unable to penetrate it. Neither can acid-etch techniques always remove this smear layer successfully[1,2]. The absence of chemical bonding between the polyisoprene component of the gutta-percha remaining on root canal walls following de-obturation for the post and the methacrylate of the resin cement may compromise bonding to dentin[5].

Certain factors such as endodontic obturation technique and time of de-obturation / post preparation may modify the quantity of endodontic material remaining on the root canal walls.

Thermoplastic obturation techniques such as the hybrid technique, systems with carriers or injected gutta-percha fill the irregularities of the root canal better than single-cone and lateral condensation techniques, but make it more difficult to remove material later from inaccessible areas[6,7].

Post space preparation can be immediate or delayed until after endodontic treatment. Immediate preparation provides greater benefits regarding control of apical seal and easier removal of remains of yet unhardened endodontic material[6,7,8].

Dentinal smear layer is often removed by means of a combination of a chelating irrigant solution such as EDTA plus a proteolytic solution such as sodium hypochlorite. However, most studies have shown that these irrigant solutions are unable to remove the smear layer completely, especially when used passively, without mechanical activation[9]. Different methods can be used to activate irrigant solutions and achieve mechanical cleansing of the secondary smear layer and obturation remnants. These include low-speed rotary brushes, ultrasonic endodontic tips, cotton-wrapped files with alcohol, polymer tips on sonic devices such as the EndoActivator (Dentsply Sirona) and more recently, a nickel-titanium instrument designed for final cleansing of endodontic preparation, called XP-endo Finisher (FKG Dentaire, Switzerland).

A conical or cylindrical rotary brush is an inexpensive, simple-to-use instrument. Its use is not limited to endodontics, and it can also be used for cleaning interproximal spaces during dental prophylaxis, mounted on a micromotor and conventional low-speed contra-angle.

Passive ultrasonic irrigation, described by Weller in 1980[10], uses a smooth, thin stainless steel file to activate the irrigant inside the root canal. This technique is based on the premise that the energy released by the instrument improves the physicochemical properties of irrigant solutions by cavitation and acoustic flow[11].

The XP-endo Finisher file (FKG, Dentaire, Switzerland) has recently appeared on the dental market. It is made from a new nickel-titanium alloy that enables it to act inside the root canal by expanding up to 6 mms more than its diameter, thereby reaching all the anatomy. The file is straight in its M-phase at ambient temperature or when cooled. When exposed to body temperature (within the root canal) its shape changes due to its molecular memory, to A-phase, enabling it to access and clean various parts of the root canal such as isthmuses and resorptions that other instruments cannot reach. Comparative studies on the use of the XP-endo Finisher file for post-endodontic instrumentation report promising results[12,13].

The aim of this study was to determine which of the three instruments used (passive ultrasonic irrigation, rotatory brush and XP-endo Finisher) is most efficient in removing the secondary smear layer from the post preparation space, independently of the irrigant solution.

MATERIALS AND METHODS

This was an ex vivo, controlled study. Forty human lower premolars that had been extracted for orthodontic or periodontal reasons were selected. Sampling was probabilistic and random.

Inclusion criteria: Lower premolars with total length 21 mm to 23 mm; apex fully developed; without carious lesions; root canal single, straight, patent to glide path preparation, not excessively oval (canal was considered excessively oval

when radiograph showed vestibular-lingual and mesiodistal dimensions in the middle third with a ratio greater than 2:1).

Exclusion criterion: lower premolars with excessively oval anatomy.

Clinical crowns were sectioned 2 mm above the proximal cementoenamel junction. Conventional openings were made, root canal glide paths were prepared, and working length of each specimen was determined as 1mm before the apical foramen, using a #15 K-file. Root canals were instrumented with ProTaper Next system (Dentsply Maillefer, Ballaigues, Switzerland) up to file X3, irrigating each instrument change with 2 ml of 2.5% sodium hypochlorite solution. Final irrigation was done with 17% EDTA for 60 seconds and 2.5% sodium hypochlorite for 30 seconds, irrigating with 3ml distilled water in between. The apical thirds of the root canals were obtured with tapered gutta-percha cones, AH Plus endodontic sealer (Dentsply Sirona, Switzerland) and warm vertical compaction technique with Calamus Dual (Dentsply Sirona, Ballaigues, Switzerland). Post spaces were prepared immediately with a Largo #1 bur (Dentsply Maillefer, Ballaigues, Switzerland) and #1, 2 y 3 calibration burs of the Macro-lock XRO (RTD, France) for the fiber posts, depth 12mm. Root canals were irrigated with 3ml of distilled water using a syringe and 1" Terumo 25G needles each time the instrument was changed. Samples were divided randomly into four groups (n=10) and labelled according to the subsequent cleaning protocol to be applied: Group C (control); Group PIU (passive ultrasonic irrigation); Group CEP (conical Rotoprox brush, Hager Werken, Germany) and Group XP (XP-endo Finisher, FKG, Dentaire, Switzerland).

Group C was irrigated with distilled water but no mechanical cleaning system was used after preparation with pilot burs. For the rest of the experimental groups, each selected instrument was used following the manufacturer's instructions for 30 seconds with distilled water inside the root canal. For Group PIU, a fine stainless steel (white) spreader tip mounted on an adaptor for the Woodpecker ultrasound unit (China) was used at 20% power. For Group CEP, a brush mounted on a micromotor and contra-angle was used at low speed, with in-and-out motion, against root canal walls. For Group XP, samples were instrumented in an oven at 37 ºC to simulate body temperature and allow the instrument's nickel-titanium austenitic phase to be expressed. Then a Teflon roll was placed in each specimen to fill the root canal space, two grooves were carved in the proximal root faces using a diamond disc without invading the endodontic space, and the samples were frozen at -70 ºC for a week, in order to make it easier to section the teeth. The samples were split using a chisel and hammer in order not to create any new smear layer that might alter observations. Half of each sample was selected and a fine-tip marker was used to make marks beside the root canal at 3 mm (coronary third), 6 mm (cervical third) and 9 mm (apical third) from the coronary reference, to enable identification of the areas to be observed under scanning electron microscope. Microphotographs of the center of the root canal were taken of each third at 350X magnification.

The following scores was applied for evaluation[14] (Fig.1):

1: No smear layer.

2: Few areas covered in smear layer, with many open dentinal tubules.

3: Most areas covered in smear layer, with few visible open dentinal tubules.

4: All areas covered in smear layer.

The images were analyzed independently by two calibrated evaluators. If the evaluators disagreed, they analyzed the image together until they reached a consensus. For statistical analysis, values were calculated per root thirds and per group. Kruskall-Wallis and Friedman tests were applied. Significance level was established as $p<0.05$ for all cases.

RESULTS

Observation by SEM showed presence of dental smear in all samples, thereby corroborating the difficulty in removing secondary smear layer from root canal walls by means of all the systems tested.

In Group C (Fig. 2 a, b, c), there was a thick layer of amorphous smear layer completely covering the observation area in all three root thirds. In Group PIU (Fig. 3 a, b, c), there was smear layer covering the entire dentin surface with presence of scratch marks in different directions on the cervical and middle thirds (Fig. 3 a, b). In Group XP, most areas were covered with smear layer and there were few visible open dentinal tubules (Fig. 4 a, b, c). In Group CEP (Fig. 5 a, b, c) there was a thin, uniform, adhered smear layer covering the observation area, with a few visible open dentinal tubules and some

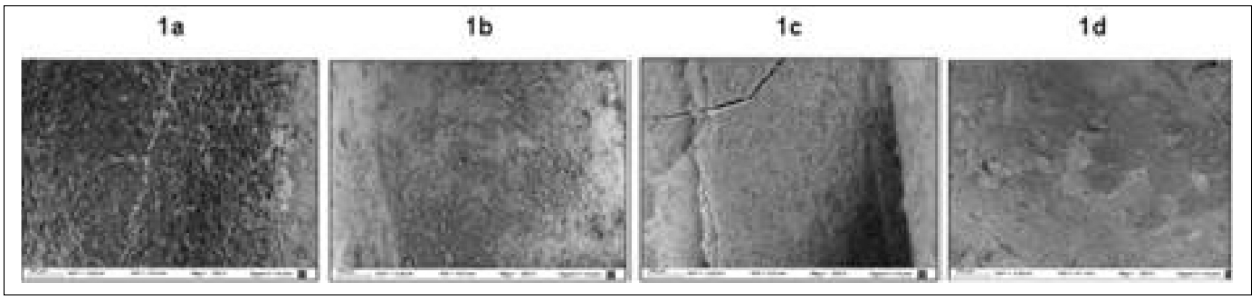

Fig. 1: Scanning electron microphotograph (350X) scores. a: Score 1, no smear layer. b: Score 2: few areas covered in smear layer, with many open dentinal tubules. c: Score 3, most areas covered in smear layer, with few visible open dentinal tubules. d: Score 4, all areas covered in smear layer.



Fig. 2: Scanning electron microphotographs (350X) for observation of secondary smear layer removal in the control group (no mechanical cleaning).a: cervical third, there is a dense, irregular smear layer covering the dentin surface entirely. b: middle third, persistence of a thick, amorphous smear layer with many debris particles of different sizes hiding dentin tubule openings. c: apical third with dense smear layer covering the entire area, with presence of loose debris particles and longitudinally oriented grooves.



Fig. 3: Scanning electron microphotographs (350X) for observation of secondary smear layer removal in Group PIU (passive ultrasonic irrigation). a: cervical third, there is a thick, even smear layer completely covering the dentin surface. b: middle third, scratches on root canal walls. c: apical third, with persistence of a thin smear layer and a few small debris particles, approximately 20µm across, scattered over the surface.

light scratch marks in the apical third (Fig. 5c).

Data and mean values are provided in Table 1.

In Groups C and XP, no statistically significant difference was found between thirds ($p>0.05$). Within Group CEP, there was a significant difference between the middle third and the apical third. Within Group PUI, there was a significant difference between the middle third and the coronary third.

There were statistically significant differences between Groups XP and C for all thirds. However, the difference was not statistically significant between Groups CEP, PIU and C, although a trend to better removal of smear layer was noted in Group CEP, for all thirds. There was no significant difference between groups CEP and XP for the middle and coronary thirds ($p>0.05$) (Figs. 2- 5).

In some samples, there were light scratch marks on the root canal surface. This was noted in all experimental



Fig. 4: Scanning electron microphotographs (350X) for observation of secondary smear layer removal in Group XP (XP-endo Finisher). a: cervical third: presence of smear layer covering dentin surface, scattered particles and a few free areas where dentin tubule openings are visible. b: middle third, persistence of smear layer, less loose debris and openings of some dentin tubules visible. c: apical third, many dentin tubules open and some areas covered in smear layer.



Fig. 5: Scanning electron microphotographs (350X) for observation of secondary smear layer removal in the Group CEP (Rotoprox conical brush). a: cervical third, presence of a smear layer of even thickness completely covering the dentin surface with a few small, scattered debris particles. b: middle third, mostly areas with open dentin tubules, with presence of debris particles approximately 25µm across scattered on the surface. c: apical third: thinned smear layer and some slight scratches, close together.

Table 1. Scores of smear layer

Third	Group	Score				
		1	2	3	4	Mean
Coronal	Control (a)	0	0	0	10	4.0
	CEP (a, b)	1	1	0	8	3.5
	PIU (a)	0	0	1	9	3.9
	XP (b)	1	1	5	3	3.0
Middle	Control (a)	0	1	0	9	3.8
	CEP (a, b)	0	3	3	4	3.1
	PIU (a)	1	0	3	6	3.4
	XP (b)	2	2	5	1	2.5
Apical	Control (a)	0	0	1	9	3.9
	CEP (a)	0	1	2	7	3.6
	PIU (a)	0	0	1	9	3.9
	XP (b)	0	3	6	1	2.8

CEP: Rotoprox brush; PIU: passive ultrasonic irrigation; XP: XP-endo Finisher.
Differences between groups identified with the same letter between brackets in each third are not statistically significant (Kruskall-Wallis; p>0.05).

groups, most frequently in the apical and middle thirds. Scratch marks were found, in descending order, in Groups PIU, CEP, and XP, with the same amount in Groups XP and C (Figs. 2c, 3b, 5c).

DISCUSSION

When luting a fiber post, it is essential to have clean dentin walls free from debris and endodontic filling remnants. It is therefore recommendable to implement a combination of mechanical and chemical cleaning actions prior to cementing[1,9]. This is even more important when dealing with oval-shaped canals such as those in single-rooted premolars and canines, which have more pronounced elliptical and irregular shape towards the free faces of the tooth, resulting in areas that retain endodontic sealer and gutta-percha[14].

The current study used distilled water instead of irrigants in order to evaluate the mechanical action only – without the chemical action of irrigants – for each system tested. In this regard, all the systems evaluated presented difficulty in completely removing the smear layer from all thirds.

In this scenario, the XP-endo Finisher achieved the best cleaning results in post space preparations and was efficient in all root thirds, even in the apical third, which is so difficult to access due to the small diameter of the post space. Thus, our studies agree with Sanabria[11], who reports that the XP-endo Finisher works better than ultrasound to remove smear layer from endodontic preparations. The XP-endo Finisher is a thin, flexible instrument designed specifically for final cleaning during surgical preparation and it reaches small, constricted areas with diameters smaller than spaces prepared for root posts. In contrast, Azimian[15] reports that the XP-endo Finisher combined with EDTA and sodium hypochlorite used after the final irrigation during surgical preparation is not superior to the same protocol without activation, thereby dismissing the mechanical action of the instrument *per se*.

In agreement with Coniglio[2], our study found very similar values between Groups PUI and C in all root thirds when distilled water was used. Consideration should be given to ultrasound intensity, which manifests in the oscillation amplitude of the instrument, application time, volume and concentration of irrigant. Although ultrasound has demonstrated good results in removing debris in combination with EDTA as a final step in surgical preparation of an endodontic treatment[16], Poletto et al. conclude that ultrasonic activation of irrigant solutions did not contribute to a more effective removal of smear layer after root post preparation[9]. There are different possible explanations for this: Coniglio et al.[2] suggest that ultrasound may compact debris particles laterally against root canal walls, Guo et al.[17] refer to the creation of new smear layer due to the scratch marks left by the instrument on dentin walls, while Chen[18] assumes that the discrepant results among studies are related to the different sizes of the preparations in the models used.

Although it was not one of the aims of this study, we noted the presence of scratch marks on some samples in all experimental groups, including Group C, where only passive irrigation of the dental smear was performed after root post space preparation, without activating the distilled water by any mechanized system. This suggests that, at least in Group C, these marks may have been caused by the Largo or pilot bur of the post system during preparation of the root bed. In agreement with Guo et al.[18], we noted more scratch marks in Group PIU, despite the precautions taken to avoid touching root canal walls upon activating the thin tip of the ultrasound.

In contrast to Goldberg[19], we found that although there was no significant difference between rotary brush and control groups, the rotary brush tended to provide cleaner results, approaching those of the XP-endo Finisher group in the middle and coronary thirds. This difference between the studies is probably related to differences in the endodontic obturation techniques used. We filled only the apical third using single cone and warm vertical compaction technique, immediately preparing the post space and cleaning unset remains of sealant from root canal walls, which must have facilitated the removal of material. It is accepted that the continuous vertical condensation technique provides better obturation quality in the coronary third because the thermo-plasticized gutta-percha provides better filling of the irregularities in the root canal[20]; nevertheless, in the middle and apical thirds, the single cone and the continuous vertical compaction techniques provide similar sealing[21].

Despite the difficulties involved in achieving a completely clean dentinal surface after post space preparation, the XP-endo Finisher instrument was the most efficient for removal of secondary smear layer, followed by the Rotoprox conical brush.

ACKNOWLEDGMENTS
We thank Dr. Ricardo Macchi for the statistical analysis in this study.

DECLARATION OF CONFLICTING INTERESTS
The authors declare no potential conflicts of interest regarding the research, authorship, and/or publication of this article.

FUNDING
None

CORRESPONDENCE
Dr. Valeria Cecilia Panetta
Paso 93 Avellaneda C.P 1870
Pcia.Buenos Aires, Argentina
panettavaleria@hotmail.com

REFERENCES

1. Serafino C, Gallina G, Cumbo E, Ferrari M. Surface debris of canal walls after post space preparation in endodontically treated teeth: A scanning electron microscopic study. Oral Surg Oral Med Oral Pathol Oral Radiol Endod 2004;97:381-387.
2. Coniglio I, Magni E, Goracci C, Radovic I, Carvalho CA, Grandini I, Ferrari M. Post space cleaning using a new nickel titanium endodontic drill combined with different cleaning regimens. J Endod 2008;34:83-86.
3. Boone KJ, Murchinson DF, Schindler WG, Walker WA 3rd. Post retention: the effect of sequence of post space preparation, cementation time and different sealers. J Endod 2001;27:768-771
4. Gu XH, Mao CY, Kern M. Effect of different irrigation on smear layer removal after post space preparation. J Endod 2009;35:583-586
5. Maroulakos G, He J, Nagy WW. The post-endodontic adhesive interface: theorical perspectives and potential flaws. J Endod 2018;44:363-371
6. Frajlich S, Goldberg F, Massone E, Cantarini C, Artaza L. Comparative study of retreatment of Thermafil and lateral condensation endodontic fillings. Int Endod J 1998;31:354-357
7. Ma J, Al-Ashaw AJ, Shen Y, Gao Y, Yang Y, Zhang Ch, Haapasalo M. Efficacy of ProTaper Universal rotary retreatment system for gutta-percha removal from oval root canals: A Micro–computed tomography study. J Endod 2012;38:1516-1520
8. Long W, Li J, Liu Y, Jiang H . Effect of obturation technique with immediate and delayed post space preparation on apical voids and bond strength of apical gutta-percha. J Int Med Res 2019;47:470–480
9. Poletto D, Poletto AC, Cavalaro A, Machado R, Cosme-Silva L, Dezan Garbelini CC, Hoeppner MG. Smear layer removal by different chemical solutions used with or without ultrasonic activation after post preparation. Restor Dent Endod 2017;42:324-331
10. Weller RN, Brady JM, Bernier WE. Efficacy of ultrasonic cleaning. J Endod 1980;6:740-743
11. Sanabria-Liviac D, Moldauer BI, Garcia-Godoy F, Campos AA, Casaretto M, Torres-Navarro J, Scalercio JM. Comparison of the XP-Endo Finisher File System and Passive Ultrasonic Irrigation (PUI) on Smear Layer Removal after Root Canal Instrumentation. J Dent Oral Health 2017;4:1-7
12. Silva EJNL, Belladonna FG, Zuolo AS, Rodrigues E, Ehrhardt IC, Souza EM, De-Deus G. Effectiveness of XP-endo Finisher and XP-endo Finisher R in removing root filling remnants: a micro-CT study. Int Endod J 2018;51: 86–91
13. Zand V, Mokhtari H, Reyhani Mf, Nahavandizadeh N, Azimi S. Smear layer removal evaluation of different protocol of Bio Race file and XP-endo Finisher file in corporation with EDTA 17% and NaOCl. J Clin Exp Dent 2017; 9:1310 - 1314
14. Hagge MS, Wong RD, Lindemuth JS. Effect of three root canal sealers on the retentive strength of endodontic posts luted with a resin cement. Int Endod J 2002;35:372-378
15. Azimian S, Bakhtiar H, Azimi S, Esnaashari E. In vitro effect of XP-endo Finisher on the amount of residual debris and smear layer on the root canal walls. Dent Res J 2019;16:179-184
16. Guerisoli DMS, Marchesan MA, Walmsley AD, Lumley PJ, Pecora JD. Evaluation of smear layer removal by EDTAC and sodium hypochlorite with ultrasonic agitation. Int Endod J 2002;35:418-421
17. Guo X, Miao H, Li L, Zhang S, Zhou D, Lu Y , Wu L. Efficacy of four different irrigation techniques combined with 60°C 3% sodium hypochlorite and 17% EDTA in smear layer removal. BMC Oral Health 2014;14:114
18. Chen X, Liu H, He Y, Luo T, Zou L. Effects of endodontic sealers and irrigation systems on smear layer removal after post space preparation. J Endod 2018; 44:1293-1297
19. Goldberg F, Frajlich S, Balzano, Rocca M, Valverde M. Estudio comparativo de la limpieza de las preparaciones para anclaje intrarradicular inmediatas y mediatas. Rev Asoc Odontol Argent 2004;92:36-39
20. Schäfer E, , Schrenker C, Zupanc J, Bürklein S. Percentage of gutta-percha filled areas in canals obturated with cross-linked gutta-percha core-carrier systems, single-cone and lateral compaction technique. J Endod 2016; 42:294–298
21. Iglecias EF, Gonzalez Freire L, de Miranda Candeiro GT, et al. Presence of Voids after Continuous Wave of Condensation and Single-cone Obturation in Mandibular Molars: A Micro-computed Tomography Analysis. J Endod 2017; 43:638-642

Low- and high-viscosity bulk-fill resin composites: a comparison of microhardness, microtensile bond strength, and fracture strength in restored molars

Fabiana M. G. França[1], Jonathan G. B. Tenuti[1], Isabela P. Broglio[1], Lara E. J. Paiva[1], Roberta T. Basting[1], Cecília P. Turssi[1], Flávia L. B. do Amaral[1], André F. Reis[2], Waldemir F. Vieira-Junior[1]

1. Faculdade São Leopoldo Mandic, Instituto de Pesquisas São Leopoldo Mandic, Departamento de Odontologia Restauradora, Campinas, Brasil.
2. University of Florida, Health Faculty Dental Practice, Operative Division, Gainesville, USA.

ABSTRACT
The aim of this study was to compare low- and high-viscosity bulk-fill composites for Knoop microhardness (KHN), microtensile bond strength (MTBS) to dentin in occlusal cavities, and fracture strength (FS) in molars with mesial-occlusal-distal restoration. Disk-shaped samples with different thicknesses (2 or 4 mm) of low-viscosity (SDR Flow, Dentsply) and high-viscosity bulk-fill composites (Filtek BulkFill, 3M ESPE; and Tetric-N Ceram Bulk Fill, Ivoclar Vivadent) were prepared for top and bottom KHN analysis (n=10). MTBS to dentin and fracture pattern was evaluated in human molars with occlusal cavities restored with (n=10): conventional nanocomposite (Z350XT, 3M ESPE), low-viscosity (Filtek Bulk-fill Flow, 3M ESPE) or high-viscosity bulk-fill composites (Filtek BulkFill). The FS and fracture pattern of human molar with mesial-occlusal-distal restorations submitted or not to thermomechanical cycling were investigated (n=10) using: intact tooth (control), and restoration based on conventional microhybrid composite (Z250, 3M ESPE), low-viscosity (SDR Flow) or high-viscosity bulk-fill composites (Filtek BulkFill). The data were submitted to split-plot ANOVA (KHN), one-way ANOVA (MTBS), two-way ANOVA (FS) followed by Tukey's test (α=0.05). For KHN, there was no significant difference for the resin composites between the top and bottom. For MTBS, no significant differences among the materials were detected; however, the low-viscosity composite presented lower frequency of adhesive failures. For FS, there was no significant difference between composites and intact tooth regardless of thermomechanical cycling. Low- and high-viscosity bulk-fill composites have comparable microhardness and microtensile bond strength when used in occlusal restorations. Likewise, the bulk-fill composites present similar fracture strength in molars with mesio-occlusal-distal restorations.

Received: April 2021; Accepted: June 2021.

Keywords: *composite resins - dental restoration failure - hardness - viscosity.*

Resinas compostas bulk-fill de baixa e alta viscosidade: uma comparação de microdureza, resistência de união à microtração e carga à fratura de molares restaurados

RESUMO
O objetivo deste estudo foi comparar resinas compostas bulk--fill de baixa e alta viscosidade quanto à microdureza Knoop (KHN), resistência de união a microtração (MTBS) em cavidades oclusais e carga à fratura (FS) em molares com restauração mesio-oclusal-distal. Amostras em forma de disco com diferentes espessuras (2 ou 4 mm) de resinas bulk-fill de baixa viscosidade (SDR Flow, Dentsply) e alta viscosidade (Filtek BulkFill, 3M ESPE; e Tetric-N Ceram Bulk Fill, Ivoclar Vivadent) foram obtidas para análise de KHN no topo e na base (n = 10). A MTBS em dentina e o padrão de fratura foram avaliados em molares humanos com cavidades oclusais restauradas com (n = 10): resina composta nanoparticulada convencional (Z350XT, 3M ESPE), resinas bulk-fill de baixa viscosidade (Filtek Bulk-fill Flow, 3M ESPE) ou alta viscosidade (Filtek BulkFill). Foram investigados a FS e o padrão de fratura de molares humanos em restaurações mesial-ocluso-distais sub metidas ou não à ciclagem termomecânica (n = 10), sendo: dente íntegro (controle), e restaurações baseadas em resina composta microhíbrida convencional (Z250, 3M ESPE); resinas bulk-fill de baixa viscosidade (SDR Flow) ou alta viscosidade (Filtek BulkFill). Os dados foram submetidos a split-plot ANOVA (KHN), one-way ANOVA (MTBS), two-way ANOVA (FS) seguidos do teste de Tukey (α = 0,05). Para KHN, não houve diferença significativa entre o topo e a base para as resinas compostas. Para MTBS, não foram detectadas diferenças significativas entre os materiais; entretanto, a resina bulk-fill de baixa viscosidade apresentou menor frequência de falhas adesivas. Para FS, não houve diferença significativa entre os materiais e o dente íntegro, independentemente da ciclagem termomecânica. As resinas bulk-fill de baixa e alta viscosidade têm microdureza e resistência à microtração comparáveis quando usados em restaurações oclusais. Da mesma forma, as

resinas bulk-fill apresentam resistência à fratura semelhante em molares com restaurações mesio-oclusal-distais.

Palavras-chave: *resinas compostas - falha de restauração dentária - dureza - viscosidade.*

INTRODUCTION

Resin-based materials are widely used for anterior and posterior tooth restoration. Nevertheless, although their properties make them suitable for clinical use, these materials shrink during polymerization[1], which is a disadvantage associated with clinical performance. The polymerization shrinkage of resin composites occurs due to the conversion of monomers into a polymer structure[2] accompanied by shrinkage stress, considered a multifactorial phenomenon determined by different factors (e.g., volumetric shrinkage, viscoelastic behavior, kinetics of reaction)[3]. Moreover, chemical and mechanical stresses in the oral environment can have consequences due to material characteristics such as defects in restoration/tooth interface, debonding, enamel micro-cracking, postoperative sensitivity, and cusp deflection[4-7].

The type of resin composite and clinical technique of application can affect the restoration properties[4, 5]. The insertion of several small increments involves more clinical variables and increases the mean time of the procedure, beyond the difficulty of filling small cavities[8], besides being dependent on the skill and expertise of clinicians. Thus, bulk-fill composites have emerged on the market to enable restorations in layers of up to 4 or 5 mm, according to manufacturers. These materials are commercially available as low- or high-viscosity composites[9, 10]. Low-viscosity bulk-fill composites (flow/flowable) are usually inserted in cavities/tooth preparations with tips and may require a layer of conventional resin composite on top of the restorations[11]. The high-viscosity bulk-fill composites (conventional/paste/sculptable) have photoinitiators with adequate activation in response to the light-curing units[12], which increase due to the resin's translucency and enable the passage of light more easily. The advantages of these materials include the simplification of the restorative procedure, time saving, low shrinkage stress depending on the technology used by the manufacturer, and adequate radiopacity[10, 12]. However, the bulk application method of tooth restoration can be associated with debonding and greater shrinkage vectors[13].

The properties and behavior of these materials need to be fully investigated. A previous study[14] has suggested that a gradual decrease in the microhardness values from the top to the bottom is composite-dependent, and that an increase in thickness could have a negative effect on the microhardness of conventional resin composites and does not interfere with bulk-fill resin composites. Microhardness could even indirectly indicate the degree of conversion of the polymer network[15] or depth of cure, and studies with different variables and purposes are necessary. A gradual reduction in microhardness values can indicate impairment in the degree conversion and consequently affect the longevity of restorations, which must have a suitable conversion to the base of the increment[16]. Considering that high-viscosity bulk-fill composites need longer curing times than low-viscosity bulk-fill composites for optimal properties[17], it is necessary to evaluate the influence of viscosity of bulk-fill composites on the microhardness and mechanical behavior of restored teeth.

In addition to physical properties, it is also relevant to consider performance during the cyclic efforts of mastication, extensive cavities, or other physicochemical challenges that can occur in the oral environment. The influence of viscosity on bulk-fill resins used for restoration under mechanical cycling and fracture strength of posterior teeth should be investigated, especially considering Class II mesio-occlusal-distal cavities with loss of marginal ridges, which are important strengthening structures for tooth resistance[18]. Furthermore, the bond strength to dentin needs to be evaluated in Class I occlusal restoration, whereas deep cavities can present high stress levels according to the technique or material applied[19].

Thus, the objective was to evaluate the influence of high- or low-viscosity bulk-fill composites on microhardness, bond strength to dentin in deep occlusal restorations, and fracture strength in molars with mesio-occlusal-distal restorations submitted or not to thermomechanical cycling. The null hypotheses tested were: 1) Increment thickness or viscosity of bulk-fill resin composites does not interfere with microhardness values; 2)

Bond strength to dentin of Class I restorations is not affected by the resin composite used; and 3) Restoration with bulk-fill composites of different viscosities, submitted or not to thermomechanical cycling, does not affect the fracture strength of the restored tooth.

MATERIALS AND METHODS

Experiment 1

Resin composite samples and Knoop microhardness analysis.

Disk-shaped samples (ø 6 mm) were made from a low-viscosity bulk-fill composite (SDR Flow, Dentsply, Milford, DE, USA) and high-viscosity bulk-fill composites (Filtek Bulk Fill, 3M ESPE, Saint Paul, MN, USA; and Tetric-N Ceram Bulk Fill, Ivoclar Vivadent, Schaan, Liechtenstein). Table 1 provides the specifications of the materials used. Samples 2 and 4 mm thick were made to evaluate the role of increment thickness on microhardness. For the microhardness test, disk-shaped samples (n = 10) were prepared by placing the single incremental material (2 or 4 mm) in a bipartite Teflon matrix. A polyester matrix strip associated with a glass plate was superimposed under pressure of 500 g / 15 s prior to photoactivation to standardize the samples. The resin composites were photopolymerized for 40 s by means of a LED curing light unit (1200 mW/cm^2; BluePhase, Ivoclar Vivadent, Schaan, Liechtenstein). The bipartite Teflon matrices were standardized at 2 mm, and the 4 mm thick samples were obtained by positioning the two aligned matrices at 2 mm.

The surface Knoop microhardness analysis (KHN)

Table 1. Description of materials and tests used in the present study.*

Material	Manufacturer	Composition	Analyses/Tests
SureFil SDR Flow (low-viscosity bulk-fill resin composite)	Dentsply Caulk, Milford, DE, USA	Modified UDMA, dimethacrylate and diluents, barium boron fluoro- alumino-silicate, colorants, strontium aluminosilicate glass, silicon dioxide - amorphous, titanium dioxide	Top and bottom microhardness Fracture strength (mesio-occlusal-distal restoration)
Filtek Bulk-fill Flow (low-viscosity bulk-fill resin composite)	3M ESPE, Saint Paul, MN, USA	Bis-GMA, Bis-EMA, UDMA, TEGDMA, Ethyl 4-(dimethylamino)benzoate, substituted dimethacrylate, silane treated ceramic, ytterbium fluoride	Microtensile bond strength (occlusal restoration)
Filtek Bulk fill Posterior Restorative (high-viscosity bulk-fill resin composite)	3M ESPE, Saint Paul, MN, USA	Aromatic urethane dimethacrylate, ytterbium dimethacrylate (YbF_3), UDMA, 1,12-Dodecane dimethcrylate (DDDMA), water, modified methacrylate monomer, ethyl 4-dimethyl aminobenzoate (EDMAB), benxotriazol, silane treated ceramic, silane treated silica, silane treated zirconia	Top and bottom microhardness Microtensile bond strength (occlusal restoration) Fracture strength (mesio-occlusal-distal restoration)
Tetric N-Ceram Bulk fill (high-viscosity bulk-fill resin composite)	Ivoclar Vivadent, Schaan, Liechtenstein	Bis-GMA, UDMA, Bis-EMA, dimethacrylates, isofiller (cured dimethacrylates, glass filler and ytterbium fluoride), spherical mixed oxide	Top and bottom microhardness
Filtek Z350 XT; (conventional nanocomposite)	3M ESPE, Saint Paul, MN, USA	Bis-EMA, UDMA, TEGDMA, Bis-GMA, , polyethylene glycol dimethacrylate, silane treated zirconia, silane treated ceramic, silane treated silica	Microtensile bond strength (occlusal restoration)
Filtek Z250 (conventional microhybrid resin composite)	3M ESPE, Saint Paul, MN, USA	Bis-GMA, Bis-EMA, UDMA, TEGDMA, ceramic treated silane, silica treated silane	Fracture strength (mesio-occlusal-distal restoration)

*Information provided by the manufacturers. Abbreviations: Bis-GMA, bisphenol-A diglycidyl ether dimethacrylate; Bis-EMA, bisphenol-A hexaethoxylated dimethacrylate; UDMA, urethane dimethacrylate; TEGDMA, triethylene glycol dimethacrylate.

was performed using a Knoop indenter with a 50-g load for 15 s in a digital microhardness tester (Pantec HVS-1000, Digimess, São Paulo, SP, Brazil). Three indentations were made on the top and bottom of disk-shaped samples, keeping a 100 µm distance between indentations.

Experiment 2

Microtensile bond strength test in occlusal restorations.

After approval by the Local Ethics Committee in Human Research (# 87973218.3.000.5374), 30 recently extracted human third molars were used. Interproximal radiographs were performed to verify the distance between the central sulcus and the pulp chamber of each tooth, selecting teeth with a minimum distance of 5 mm. Occlusal cavities were made using a cavity preparation machine (Elquip, São Carlos, SP, Brazil) and cylindrical diamond tips positioned parallel to the long axis of the tooth. Cavity dimensions were 4 x 5 x 4 mm, checked after each cavity preparation using a digital caliper. Then the teeth were randomly divided into the following restorative treatments (n = 10):

(I) Restoration using a conventional nanocomposite (Filtek Z350 XT; 3M ESPE, Saint Paul, MN, USA) and incremental filling technique as a control. The insertion was performed using small increments (2 mm) and light-curing each portion for 10 s.

(II) Restoration using a low-viscosity bulk-fill composite (Filtek Bulk-fill Flow, 3M ESPE, Saint Paul, MN, USA). The insertion was performed applying a 4-mm layer and light-curing for 20 s.

(III) Restoration using a high-viscosity bulk-fill composite (Filtek Bulk Fill, 3M ESPE). The insertion was performed using a 4-mm layer and light-curing for 20 s.

A LED curing light (BluePhase, Ivoclar Vivadent AG, Schaan, Liechtenstein) was used for the photoactivation of the resin composite and adhesive system. All teeth were restored using a universal adhesive (Adper Single Bond Universal, 3M ESPE, Saint Paul, MN, USA) applied as a self-etching adhesive system.

After the restorative procedures, the teeth were stored for 7 days at 37 ºC. After this time, the teeth were individually fixed on an acrylic plate that was attached to a precision cutting machine (Isomet 1000, Buehler, Lake Bluff, IL, USA) and high-concentration diamond disc (Buehler) was used to serially section the samples, providing stick-shaped specimens composed of resin composite bonded to dentin. Each tooth resulted in approximately 4 sticks of 1 mm^2.

Tensile testing was performed in a universal testing machine (EMIC, São José dos Pinhais, PR, Brazil). The sticks were individually attached to the grips of a microtensile device. The test was conducted at a crosshead speed of 0.5 mm/min until debonding or fracture of the stick, and the corresponding force values were obtained in newtons (N). The stick debonding tensions were calculated in megapascals (MPa) after measuring the bonding area with a digital caliper. The interface of the fractured sticks was examined under a stereoscopic microscope (30x magnification) to classify the fracture pattern. The fractures were classified such as: (a) adhesive; (b) cohesive in resin; (c) cohesive in dentin; or (d) mixed.

Experiment 3

Fracture strength in molars with mesio-occlusal-distal restorations.

Human third molars with MOD cavities were evaluated according to the following treatments/techniques: intact tooth (control, no treatment or preparation); restoration with conventional microhybrid composite (Z250, 3M ESPE, Saint Paul, MN, USA); restoration with low-viscosity bulk-fill composite (SureFil SDR Flow, Dentsply); or restoration with high-viscosity bulk-fill composite (Filtek Bulk Fill, 3M ESPE). These teeth were submitted or not to thermomechanical cycling and were assessed, with n = 10, for fracture strength by axial compressive loading (ACL) and qualitative evaluation of fracture pattern.

Eighty human third molars without caries, stains, or cracks (Local Ethics Committee in Human Research approval - #60999616.4.0000.5374) were used in this assessment. The teeth were scraped with periodontal curettes (Duflex - SS White / Dental Articles Ltd., Rio de Janeiro, RJ, Brazil) and stored in 0.1% thymol solution. All teeth were submitted to dental X-ray to check the distance between the central sulcus and the pulp chamber, and teeth in which they were less than 5 mm apart were excluded. Other variables measured were total tooth, crown, and root length, in order to ensure that tooth sizes were distributed evenly among the groups. After the

measurements, the teeth were classified according to size as small, medium and large, and randomly assigned to groups so that all groups consisted of similar amounts of each size.

To simulate the periodontal ligament[20], the dental roots were immersed in wax (# 7 Lysanda Produtos Odontológicos Ltd., São Paulo, SP, Brazil), obtaining a layer 0.2 mm thick. A polyvinyl chloride ring (PVC, Tigre S.A., Joinville, SC, Brazil) 25 mm in diameter and 25 mm high was placed around the root that was embedded with a polystyrene resin. After this, a soft polyether impression material (Impregum, 3M ESPE, Seefeld, Germany) was manipulated according to the manufacturer's instructions and applied to the root. MOD cavities were prepared using a cavity preparation machine (Elquip, São Carlos, SP, Brazil) associated with copious air–water spray. The preparations were performed with 1/3 of the intercuspal width, within a 5 mm-deep occlusal box, and without a proximal box using a diamond bur (#3145 KG Sorensen Ind. e Com. Ltd, Cotia, SP, Brazil).

All restored groups received an application of 35% phosphoric acid (3M ESPE) for 15 s for dentin and 30 s for enamel; flush with water for 15 s; removal of the excess water with a light air jet for 2 s; application of the adhesive system (Adper Single Bond 2, 3M ESPE, Saint Paul, MN, USA) according to the manufacturer's recommendation; and photoactivation for 20 s by the LED curing light (BluePhase, Ivoclar Vivadent AG, Schaan, Liechtenstein). The groups were divided according to the following description:

(I) Control: Intact tooth without preparation or restoration.

(II) Conventional microhybrid composite (Z250): The composite was incrementally inserted in three oblique layers that were photoactivated individually.

(III) Low-viscosity bulk-fill composite (SDR): The material was inserted in a single layer of 4 mm and photoactivated, followed by the layer insertion (1 mm) of microhybrid resin (Filtek Z250, 3M ESPE) and photoactivated.

(IV) High-viscosity bulk-fill composite (Filtek Bulk Fill): The resin was inserted in a single layer (5 mm) and photoactivated for 60 s: 20 s from the occlusal surface, 20 s from the buccal surface, and 20 s from the lingual surface.

The resin-based materials of all restored groups were photoactivated by the LED curing light unit mentioned above. Twenty teeth were subjected to each treatment, and half of each group was submitted to a thermomechanical cycling test, establishing n=10 per group.

Thermomechanical cycles were simulated to induce material fatigue (Elquip, São Carlos, SP, Brazil). The teeth received loading in the axial direction and were cycled 100,000 times with 50 N load and 2 Hz frequency. During the test, the teeth were stored at a relative humidity and submerged cyclically between 5 ºC and 55 ºC (1 min). The compressive loading test was performed in a Universal Testing Machine (EMIC DL 2000, São José dos Pinhais, PR, Brazil) with axial loading of compression, at 0.5 mm/min (crosshead speed). The values obtained were expressed in newtons (N). After the fracture strength test, the teeth were evaluated for fracture pattern and classified as: (a) coronary fracture up to the middle third; (b) coronary fracture up to the cervical; (c) root fracture up to the cervical; and (d) severe root fracture in the middle and apical third.

Statistical analysis

The statistical models used followed the experimental design of each experiment. All analyses were performed at the SAS (SAS Institute Inc., Cary, NC, USA, Release 9.2, 2010) considering the significance level of 5%. After the exploratory analysis, the KHN data were submitted to split-plot analysis of variance (ANOVA) and Tukey's test for multiple comparisons. The split-plot ANOVA was used because the experiment was performed considering two factors (bulk-fill composite and thickness), and the KHN values of the top and bottom were considered as a subplot. This analysis considered main factors, double and triple interactions.

The results obtained for occlusal restorations were evaluated by one-way ANOVA to determine whether the bond strength values were influenced by the resin composite used. A G-test was performed to assess the fracture pattern for microtensile bond strength test. For MOD restorations, the values of fracture strength after logarithmic transformation were analyzed by two-way ANOVA. The two-way ANOVA was used in order to consider the two factors (tooth restoration x thermomechanical cycling) and interactions. The fracture pattern was assessed by Fisher's exact test.

The calculation of sample size was performed using GPower software. The sample size (n=10) was provided considering the power setting of 0.80, significance level of 0.05, and following parameters for the detectable minimum effect sizes: 0.51 (large) for KHN; 0.52 (large) for fracture pattern; and 0.38 (medium to large) for fracture strength.

RESULTS

The KHN results (Table 2) had the following *p-values: p(composite) = 0.0004; p(thickness) = 0.04; p(composite vs. thickness) = 0.01; p(top/bottom) = 0.51; p(composite vs. top/bottom) = 0.16; p(thickness vs. top/bottom) = 0.38; p(composite vs. thickness x top/bottom) = 0.11*. There was no significant difference between the top and bottom for KHN values *(p = 0.51)*. At the top, the high-viscosity bulk-fill composite (Tetric-N) showed significantly higher KHN values for an increment thickness of 4 mm in comparison to 2 mm *(p = 0.01)*. At the bottom and increment thickness of 4 mm, the other high-viscosity bulk-fill composite (Filtek BF) presented a significantly lower surface microhardness values than the other composites *(p = 0.01)*.

Concerning the results of microtensile bond strength test for occlusal restorations (Table 3), there was no significant difference for MPa values among all groups, regardless of the restorative material used *(p = 0.15)*. Nevertheless, there was a statistically significant difference among groups regarding fracture pattern *(p = 0.04)*. Adhesive-type fracture patterns were more prevalent in high-viscosity bulk-fill (46.7%) and nanocomposite (47.4%) than in low-viscosity bulk-fill composite (20%). The dentin cohesive-type fracture pattern was more frequent in the tooth restored with low-viscosity bulk-fill composite (50%).

The results of fracture load (Table 4) presented the following *p-values: p(treatment) = 0.88; p(cycling) = 0.81; and p(treatment vs. cycling) = 0.34*. There was no significant difference between treatments or thermomechanical cycling (with and without) for fracture strength. Fisher's exact test showed that the distribution of the fracture pattern varied according to the treatment *(p = 0.007)*, and these results are presented in Table 5. All fractures were coronary, with the majority being coronary until the middle

Table 2. Surface microhardness values (Mean ± SD) in the top and bottom of materials in relation to increment thickness (n = 10).*

Bulk-fill resin composite		Thickness		Result of split-plot ANOVA
		2 mm	4 mm	
Top	Low viscosity (SDR)	127.50 ± 24.13^{Aa}	118.88 ± 35.66^{Aa}	*Main effect:* Composite, p = 0.0004 Thickness, p = 0.04 Top/bottom, p = 0.51 *Interaction effect:* Composite x Thickness, p = 0.01 Composite x Top/bottom, p = 0.16 Thickness x Top/bottom, p = 0.38 Composite x Thickness x Top/bottom, p = 0.11
	High viscosity (Filtek BF)	103.23 ± 21.65^{Aa}	109.69 ± 28.84^{Aa}	
	High viscosity (Tetric-N)	98.99 ± 8.52^{Ba}	141.72 ± 30.86^{Aa}	
Bottom	Low viscosity (SDR)	130.52 ± 22.22^{Aa}	134.38 ± 26.37^{Aa}	
	High viscosity (Filtek BF)	100.40 ± 17.04^{Aa}	99.16 ± 12.20^{Ab}	
	High viscosity (Tetric-N)	114.72 ± 30.86^{Aa}	133.76 ± 21.65^{Aa}	

*Values followed by different letters (uppercase in horizontal and lowercase in vertical) differ from each other. Abbreviations: SDR, SureFil SDR Flow; Filtek BF, Filtek Bulk Fill Posterior Restorative; Tetric-N, Tetric N-Ceram Bulk Fill.

Table 3. Results (Mean ± SD) of microtensile bond strength test (MPa) and relative frequency (%) of fracture pattern according to the restorative materials used for occlusal restorations (n = 10).*

Resin composite		Fracture pattern (%)			
	MPa	Adhesive	Mixed	Cohesive in dentin	Cohesive in resin
Conventional nanocomposite (Filtek Z350 XT)	28.62 ± 18.38^{a}	47.4	36.8	10.5	5.3
Low-viscosity bulk-fill (Filtek BF Flow)	31.88 ± 14.53^{a}	20	15	50	15
High-viscosity bulk-fill (Filtek BF)	41.40 ± 11.91^{a}	46.7	13.3	20	20
Results of statistical tests	*MPa,* p = 0.15	*Fracture pattern,* p = 0.04			

*For MPa results, mean ± SD followed by the same letters did not differ from each other. Abbreviations: Filtek BF, Filtek Bulk Fill.

Table 4. Mean ± SD of fracture load (N) according to treatment and thermomechanical cycling (n = 10).*

	Thermomechanical cycling		Result of two-way ANOVA
	without	with	
Intact tooth (control)	2188.4 ± 445.8^{Aa}	2005.5 ± 688.5^{Aa}	Main effect: Treatment, p = 0.88 Cycling, p = 0.81 Interaction effect: Treatment x Cycling, p = 0.34
Conventional microhybrid composite (Z250)	2310.8 ± 717.2^{Aa}	2165.1 ± 775.9^{Aa}	
Low-viscosity bulk-fill composite (SDR)	2025.7 ± 713.7^{Aa}	2069.7 ± 673.3^{Aa}	
High-viscosity bulk-fill composite (Filtek BF)	1906.2 ± 589.2^{Aa}	2507.5 ± 1002.9^{Aa}	

*Values followed by the same letters (uppercase in horizontal and lowercase in vertical) did not differ from each other (p>0.05). Abbreviations: SDR, SureFil SDR Flow; Filtek BF, Filtek Bulk Fill Posterior Restorative.

Table 5. Number of fractured samples and frequency distribution (%) of fracture pattern according to cycling and restorative materials used for mesio-occlusal-distal restorations (n = 10).*

Cycling	Groups	Fracture pattern			
		Coronary up to the middle third	Coronary to cervical	Root fracture up to the cervical	Severe root fracture
without	Intact tooth (control)	6 (60%)	4 (40%)	0 (0%)	0 (0%)
	Z250 (conventional)	7 (70%)	0 (0%)	3 (30%)	0 (0%)
	SDR (low viscosity)	2 (20%)	4 (40%)	4 (40%)	0 (0%)
	Filtek BF (high viscosity)	9 (90%)	1 (10%)	0 (0%)	0 (0%)
with	Intact tooth (control)	7 (70%)	3 (30%)	0 (0%)	0 (0%)
	Z250 (conventional)	7 (70%)	3 (30%)	0 (0%)	0 (0%)
	SDR (low viscosity)	4 (40%)	2 (20%)	3 (30%)	1 (10%)
	Filtek BF (high viscosity)	6 (60%)	2 (20%)	0 (0%)	2 (20%)
	Fisher's exact test	*p = 0.007*			

*Abbreviations: Z250, conventional microhybrid composite; SDR, SureFil SDR Flow, low-viscosity bulk-fill composite; Filtek BF, Filtek Bulk Fill Posterior Restorative, high-viscosity bulk-fill composite.

third for the following groups: intact tooth (with and without cycling); conventional microhybrid composite (Z250) with cycling; and high-viscosity bulk-fill composite (Filtek BF) without cycling. For the conventional microhybrid composite (Z250) without cycling, 70% of the teeth presented a coronary fracture until the middle third, and the remainder had a root fracture up to the cervical. In the treatments with low-viscosity bulk-fill composite (SDR) or high-viscosity bulk-fill composite (Filtek BF) with cycling, the root fractures were observed in the middle and apical thirds.

DISCUSSION

The present study showed there was no significant difference between the top and bottom in the surface microhardness of bulk-fill composites with different viscosities, so the results fail to reject the first null hypothesis. Bulk-fill composites have higher translucency than conventional resin composites[12], and the translucency of resins depends on the factors of increment thickness, dispersion/absorption coefficients of material, pigments, and opacifiers[21-23]. Moreover, increase in the cure depth of a bulk-fill resin can relate not only to higher translucency compared to a conventional resin but also to modified monomers, incorporation of stress relievers, or photoinitiator systems included in its composition[21], especially because the decrease in polymerization shrinkage is manufacturer-dependent and may be associated with different attenuation mechanisms[7].

The viscosity of material is influenced by monomer and filler content associating with the reaction kinetics and final polymerization. Modifications of the monomer and filler components make bulk-fill resins more translucent/transparent by adding

so-called polymerization modulators or initiation boosters[14, 24]. Considering the low-viscosity bulk-fill composites studied, SDR (Dentsply) presented favorable and constant results regarding top or bottom microhardness and fracture strength of restored molars. SDR presents a uniform degree of conversion at a depth of 1-4 mm and a low proportion of internal gaps in dental restoration[25]. According to the manufacturer, an adequate degree of conversion and reduction of shrinkage stress is related to chemically modified polymer formation, which is flexible with the homogeneous network. Furthermore, SDR is composed of a modulator chemically incorporated to UDMA that could interact synergistically with camphorquinone, culminating in adequate polymerization[21].

Considering the KHN results, Tetric-N was the high-viscosity bulk-fill composite that presented a significantly higher top KHN value at 4 mm than at the increment thickness of 2 mm. Tetric-N has a photoinitiator described as a polymerization booster (Ivocerin®) which, associated with the camphorquinone/amine initiator system, can polymerize the material in depth[21]. Ivocerin® is a dibenzoyl germanium derivative system with the highest absorption of wavelengths around 370 to 460 nm[26]. At the bottom, with increment thickness of 4 mm, the other high-viscosity bulk-fill composite studied (Filtek Bulk Fill) showed significantly lower surface microhardness compared to the other bulk-fill composites. This can be explained by the absence of TEGDMA in the composition of this material, which has approximately half the molecular weight of the other monomers[27]. The microhardness variable has a high correlation with the filler content of material, and the lower microhardness values at the bottom surface of the Filtek Bulk Fill could occur due to light attenuation[28]. Nevertheless, no differences were found between increments of 2 mm or 4 mm, indicating an adequate depth of cure.

Consistently with the KHN results, the bond strength results (MPa) showed that there were no differences between the conventional nanocomposite, high- and low-viscosity bulk-fill composites, so the results fail to reject the second null hypothesis. In posterior teeth cavities, bond strength is expected to be equal to or lower than the dental cohesive strength, because in case of failures after the adhesion process, it is preferable that these failures should occur in the material, protecting the remaining dental structure. Nevertheless, sufficient bond strength is necessary in order to resist the mechanical and chemical challenges in the oral environment. In the present study, the bulk-fill composites did not differ from conventional nanocomposite for MPa. This result is relevant because the conventional nanocomposite has been extensively studied and its performance is considered satisfactory[29]. Adhesive-type failures were more usual in the high-viscosity composites (bulk-fill or conventional) that are nonflowable and sculptable, while cohesive-type failures occurred more frequently in low-viscosity bulk-fill composite. Flowable resin composites generally have lower filler loading and are more fluid[30], promoting adequate adaptation in the pulpal floor and decreasing internal irregularities of the preparation. Other factors could contribute to the fracture pattern results, such as the elastic modulus of high-viscosity composites, which is higher than in the low-viscosity composites[31] and consequently promotes lower capacity for flow and adaptation on the deeper walls. Furthermore, bond strength was measured in the pulpal floor in deep occlusal cavities. This area is challenging for adhesive procedures due to the humidity, permeability, and characteristics of the intertubular dentin[32], which may accentuate premature loss of adhesion.

Considering the fracture strength in molars with MOD restorations, the results fail to reject the third null hypothesis because no difference was observed in the fracture strength values of cavities restored with a conventional resin composite or bulk-fill composites of different viscosities, including the comparison with the intact tooth. This result is compatible with a previous study[33] in which teeth treated endodontically with conventional composite resins or bulk-fill composites were tested for fracture strength, and there was also no difference between these materials, even when compared to the intact teeth. A high elastic modulus can inhibit the ability to deform, generating greater stress in the dental structures[34]. The adequate elastic modulus of bulk-fill resins to substitute dentin or enamel[20] allows the material to deform and absorb the stress generated during the thermomechanical cycles, similarly to the microhybrid resin used as a control. However, further studies should evaluate the behavior of teeth fully restored with low-viscosity composites, since in the present study, a conventional composite surface layer was used, considering the high occlusal

load to which MOD cavities are submitted.

In a clinical situation, the size, type, and location of the cavity should guide the choice of material; therefore, the present study investigated the behavior of these materials in cavities/restorations of different configurations. The mechanical properties of the different materials vary considerably. Thus, the low-viscosity composites seem appropriate for liner, deep cavities and restorations after endodontic treatments, since the low viscosity facilitates adaptation in less accessible spaces[30]. On the other hand, high-viscosity composites are materials with more filler content and could be used in cavities considering their resistance to fracture or wear[11]. The fracture strength and the bond strength presented by both viscosities of bulk-fill composites are similar. The fracture strength of molars restored with these composites is equivalent to that of the tooth structure and the bond strength is comparable to that of a conventional composite. However, these resin composites require care during the insertion step, especially in the deep walls, in order to reduce adhesive or adaptation failures. Under controlled situations, as employed in the present study, the behavior of the different conventional or bulk-fill resin composites, regardless of viscosity, was similar, in agreement with previous investigations[35-37] that reported clinical performance of bulk-fill resin composites similar to that of conventional resin composites. Further *in vitro* studies and clinical trials of bulk-fill composites remain necessary to continue their validation.

In general, according to the results of experiments, relevant findings were: the viscosity of bulk-fill resin composites included in this study did not influence the microhardness of top and bottom, regardless of increment thickness (2 or 4 mm); the dentin bond strength of bulk-fill resin composites, regardless of viscosities inserted as a single increment, was similar to conventional nanocomposite incrementally inserted in deep occlusal cavities, although adhesive failures were less frequent in low-viscosity bulk-fill composites compared to other materials. Moreover, the fracture strength of molars with MOD cavities restored with bulk-fill composites, regardless of viscosity, was similar to intact tooth and conventional microhybrid resin restorations, even after thermomechanical cycling.

DECLARATION OF CONFLICTING INTERESTS

The authors declare no potential conflicts of interest with respect to the research, authorship, and/or publication of this article.

FUNDING

None.

CORRESPONDENCE

Dr. Fabiana Mantovani Gomes França
Faculdade São Leopoldo Mandic, Instituto de Pesquisas São Leopoldo Mandic
Rua José Rocha Junqueira, 13 – Swift, Campinas – SP, 13045-755
Brasil
biagomes@yahoo.com

REFERENCES

1. Ferracane JL. Resin composite-state of the art. Dent Mater 2011; 27: 29-38.
2. Al Sunbul H, Silikas N, Watts DC. Polymerization shrinkage kinetics and shrinkage-stress in dental resin-composites. Dent Mater 2016;32:998-1006.
3. Braga RR, Ballester RY, Ferracane JL. Factors involved in the development of polymerization shrinkage stress in resin-composites: a systematic review. Dent Mater 2005;21:962-970.
4. Bicalho AA, Pereira RD, Zanatta RF, Franco SD et al. Incremental filling technique and composite material. Part I: cuspal deformation, bond strength, and physical properties. Oper Dent 2014;39:E71-E82.
5. Bicalho AA, Valdívia AD, Barreto BC, Tantbirojn D et al. Incremental filling technique and composite material. Part II: shrinkage and shrinkage stresses. Oper Dent 2014;39:E83-E92.
6. Tantbirojn D, Pfeifer CS, Amini AN, Versluis A. Simple optical method for measuring free shrinkage. Dent Mater 2015;31:1271-1278.
7. Soares CJ, Faria-e-Silva AL, Rodrigues MP, Vilela ABF et al. Polymerization shrinkage stress of composite resins and resin cements - What do we need to know? Braz Oral Res 2017;31:e62.
8. Kumagai RY, Zeidan LC, Rodrigues JA, Reis AF et al. Bond Strength of a Flowable Bulk-fill Resin Composite in Class II MOD Cavities. J Adhes Dent 2015;17:427-432.
9. Kim EH, Jung KH, Son SA, Hur B et al. Effect of resin thickness on the microhardness and optical properties of bulk-fill resin composites. Restor Dent Endod 2015;40:128-135.
10. Fugolin APP, Pfeifer CS. New Resins for Dental Composites. J Dent Res 2017; 96: 1085-1091.
11. Van Ende A, de Munck J, Van Landuyt KL, Poitevin A et

al. Bulk-filling of high C-factor posterior cavities: Effect on adhesion to cavity-bottom dentin. Dent Mater 2013;29:269-277.
12. Zorzin J, Maier E, Harre S, Fey T et al. Bulk-fill resin composites: polymerization properties and extended light curing. Dent Mater 2015;31:293-301.
13. Kaisarly D, El Gezawi M, Keßler A, Rösch P et al. Shrinkage vectors in flowable bulk-fill and conventional composites: bulk versus incremental application. Clin Oral Investig 2021:25:1127-1139.
14. Flury S, Peutzfeldt A, Lussi A. Influence of increment thickness on microhardness and dentin bond strength of bulk fill resin composites. Dent Mater 2014;30:1104-1112.
15. Yan YL, Kim YK, Kim KH, Kwon TY. Changes in Degree of Conversion and Microhardness of Dental Resin Cements. Oper Dent 2010;35:203-210.
16. Flury S, Hayoz S, Peutzfeldt A, Hüsler J et al. Depth of cure of resin composites: is the ISO 4049 method suitable for bulk fill materials. Dent Mater 2012;28:521-528.
17. Miletic V, Pongprueksa P, De Munck J, Brooks NR et al. Curing characteristics of flowable and sculptable bulk-fill composites. Clin Oral Investig 2017;21:1201-1212.
18. Shahrbaf S, Mirzakouchaki B, Oskoui SS, Kahnamoui MA. The effect of marginal ridge thickness on the fracture resistance of endodontically-treated, composite restored maxillary premolars. Oper Dent 2007;32:285-290.
19. Ausiello PP, Ciaramella S, Lanzotti A, Ventre M et al. Mechanical behavior of Class I cavities restored by different material combinations under loading and polymerization shrinkage stress. A 3D-FEA study. Am J Dent 2019;32:55-60.
20. Rosatto CM, Bicalho AA, Veríssimo C, Bragança GF et al. Mechanical properties, shrinkage stress, cuspal strain and fracture resistance of molars restored with bulk fill composites and incremental filling technique. J Dent 2015;43:1519-1528.
21. Kim RJ, Kim YJ, Choi NS, Lee IB. Polymerization shrinkage, modulus, and shrinkage stress related to tooth-restoration interfacial debonding in bulk-fill composites. J Dent 2015;43:430-439.
22. Haas K, Azhar G, Wood DJ, Moharamzadeh K et al. The effects of different opacifiers on the translucency of experimental dental composite resins. Dent Mater 201733:e310-e316.
23. Finan L, Palin WM, Moskwa N, Mcginley EL et al. The influence of irradiation potential on the degree of conversion and mechanical properties of two bulk-fill flowable RBC base materials. Dent Mater 2013;29:906-912.
24. Ilie N, Bucuta S, Draenert M. Bulk-fill resin-based composites: an in vitro assessment of their mechanical performance. Oper Dent 2013;38:618-625.
25. Fronza BM, Rueggeberg FA, Braga RR, Mogilevych B et al. Monomer conversion, microhardness, internal marginal adaptation, and shrinkage stress of bulk-fill resin composites. Dent Mater 2015;31:1542-1551.
26. Moszner N, Fischer U, Ganster B, Liska R et al. Benzoyl germanium derivatives as novel visible light photoinitiators for dental materials. Dent Mater 2008;24:901-907.
27. Gajewski VE, Pfeifer CS, Fróes-salgado NR, Boaro LC et al. Monomers used in resin composites: degree of conversion, mechanical properties and water sorption/solubility. Braz Dent J 2012;23:508-514.
28. Son SA, Park JK, Seo DG, Ko CC et al. How light attenuation and filler content affect the microhardness and polymerization shrinkage and translucency of bulk-fill composites? Clin Oral Investig 2017;21:559-565.
29. de Andrade AK, Duarte RM, Medeiros e Silva FD, Batista AU et al. Resin composite Class I restorations: a 54-month randomized clinical trial. Oper Dent 2014;39:588-594.
30. Baroudi K, Rodrigues JC. Flowable Resin Composites: A Systematic Review and Clinical Considerations. J Clin Diagn Res 2015;9:ZE18-ZE24.
31. Rizzante FAP, Mondelli RFL, Furuse AY, Borges AFS et al. Shrinkage stress and elastic modulus assessment of bulk-fill composites. J Appl Oral Sci 2019;27:e20180132.
32. Pashley DH, Carvalho RM. Dentine permeability and dentine adhesion. J Dent 1997;25:355-372.
33. Isufi A, Plotino G, Grande NM, Ioppolo P et al. Fracture resistance of endodontically treated teeth restored with a bulk fill flowable material and a resin composite. Ann Stomatol (Roma) 2016;7:4-10.
34. Lohbauer U, Frankenberger R, Krämer N, Petschelt A. Strength and fatigue performance versus filler fraction of different types of direct dental restoratives. J Biomed Mater Res B Appl Biomater 2006;76:114-120.
35. Kruly PC, Giannini M, Pascotto RC, Tokubo LM et al. Meta-analysis of the clinical behavior of posterior direct resin restorations: Low polymerization shrinkage resin in comparison to methacrylate composite resin. PLoS One 2018;13 e0191942.
36. Veloso SRM, Lemos CAA, de Moraes SLD, do Egito Vasconcelos BC et al. Clinical performance of bulk-fill and conventional resin composite restorations in posterior teeth: a systematic review and meta-analysis. Clin Oral Investig 2019;23:221-233.
37. Balkaya H, Arslan S. A two-year clinical comparison of three different restorative materials in class II cavities. Oper Dent 2020;45:E32-E42.

Pit and fissure depth in the enamel of mandibular third molars: An open gate for microleakage?

Osvaldo Zmener[1], Cornelis H. Pameijer[2], Ana C. Boetto[3], Mariana Picca[4]

1.Universidad del Salvador, Facultad de Ciencias Médicas, Escuela de Odontología, Buenos Aires, Argentina
2. University of Connecticut, School of Dental Medicine, Department of Reconstructive Sciences, Farmington, USA
3.Universidad de Córdoba, Facultad de Odontología, Cátedra de Endodoncia, Córdoba, Argentina
4.Universidad de Buenos Aires, Facultad de Odontología, Cátedra de Materiales Dentales, Buenos Aires, Argentina

ABSTRACT

The aim of this descriptive ex vivo study was to evaluate qualitatively the depth of pit and fissures (P&F) of the enamel in human mandibular third molars. Fifty (n=50) extracted human mandibular third molars were cleaned and disinfected. All tooth surfaces were coated with nail varnish except for a 1-mm margin around the periphery of the occlusal surface. The teeth were immersed for 48 hours at 37 °C in 1% methylene blue dye solution prepared in artificial saliva. After cleaning, the crowns were separated from the root at the cementoenamel junction and subsequently sectioned longitudinally in bucco-lingual direction at the location of the central fossa. All sections were examined using a stereoscopic microscope and photographed. The images were downloaded on a computer. The length of penetration of the P&F was recorded using the following scoring system: C1: P&F extended to half of the enamel thickness; C2: P&F extended beyond half of the enamel thickness without reaching the dentine-enamel junction; C3: P&F extended to the dentine-enamel junction. For pits, C1, C2 and C3 were observed in 35, 9 and 6 teeth, respectively, while for fissures, C1, C2 and C3 were observed in 15, 18 and 17 teeth, respectively. The P&F detected in the samples extended to the deepest portions of enamel, quite frequently reaching the enamel-dentine junction. Clinicians should recognize that even if pits and fissures are not clinically obvious, they penetrate deep into the enamel and frequently reach the dentine-enamel junction. Effective treatment is recommended to block access to P&F, thus preventing ingress of bacteria.

Received: March 2021: Accepted: July 2021.

Keywords: *dental enamel - dentine - molar - pit and fissures sealants.*

Profundidad de fosas y fisuras en el esmalte de terceros molares inferiores ¿Una puerta abierta a la microfiltración?

RESUMEN

Objetivos: El objetivo del presente estudio descriptivo fue evaluar cualitativamente mediante un ensayo ex vivo la profundidad de las fosas y fisuras (F&F) del esmalte en terceros molares inferiores humanos. Materiales y métodos: Cincuenta (n=50) terceros molares inferiores sanos extraídos se lavaron, se descontaminaron y se recubrieron con esmalte para uñas hasta 1 mm menos del área de las F&F. Luego se sumergieron durante 48 horas a 37°C en una solución de azul de metileno al 1% (pH 7,4) preparada con saliva artificial. Posteriormente se lavaron y se separaron las coronas a nivel del límite amelocementario. En cada molar se realizó una sección longitudinal de 1 mm de espesor con orientación vestíbulo-lingual a nivel de la fosa central. Las secciones fueron analizadas con microscopio estereoscópico y fotografiadas. Las imágenes se transfirieron a una computadora. Se determinó cualitativamente la extensión de las F&F en el espesor del esmalte y se las clasificó de acuerdo a 3 categorías. C1: extensión hasta la mitad del espesor del esmalte; C2: extensión que supera la mitad del espesor del esmalte sin afectar el límite amelodentinario; C3: extensión que llega al límite amelodentinario. Resultados: Para las fosas, 35, 9 y 6 especimenes correspondieron a las categorías C1, C2 y C3 respectivamente. Para las fisuras, 15, 18 y 17 especimenes correspondieron a las categorías C1, C2 y C3 respectivamente. Conclusiones: Las fosas y fisuras de la muestra analizada se extienden hasta la zona más profunda del espesor del esmalte. Con cierta frecuencia llegan hasta el límite amelodentinario.

Palabras clave: *dentina - esmalte dental - molar - selladores de fosas y fisuras.*

INTRODUCTION

Pits and fissures (P&F) of enamel surfaces in deciduous and permanent teeth are susceptible areas in which biofilm, food and bacterial debris can accumulate, leading to the development of acid-producing plaque resulting in caries[1]. The carbohydrates from food will be broken down, leading to demineralization of enamel. The extent of P&F is difficult to measure during a clinical examination. There are many investigations reporting different protocols for cleaning P&F[2] and for sealant application[3-5].

In a study published in 2007, Cruvivnel et al[6] suggested that the depth of P&F is the most critical factor in terms of possible pulpal involvement. They showed that in the permanent dentition, the deepest part of the P&F is frequently located near or in direct contact with the enamel-dentine junction. They also hypothesized that in these cases, resident bacteria may leak into the pulp via dentinal tubules, which in turn may explain why some patients may complain of pain in "clinically healthy molars"[7-9]. The literature related to P&F depth and caries incidence in permanent molars is scarce[10]. The aim of this descriptive *ex vivo* assay was to evaluate qualitatively the depth of penetration of P&F in the enamel of human permanent third molars. The null hypothesis tested was that the enamel-dentine junction is not compromised by the depth of the P&F.

MATERIALS AND METHODS

The experimental protocol of the present study was authorized by the Institutional Research Ethics Committee of the Argentine Dental Association (Approval Code # 2019/0118-AOA). For this study, fifty (n=50) extracted human third molars stored at 4 °C in 2% thymol in normal saline were used. Inclusion criteria were being free of caries, restorations, pigmentations or other morphological alterations of the enamel, and having a centralized P&F system on the occlusal surface with at least one central fossa. The absence of clinically undetectable caries was confirmed with a laser fluorescence device (Diagnodent; Kavo, Biberach, Germany) as described by Lussi et al[9].

After removal of gross debris attached to the roots, the occlusal surface of each tooth was cleaned for 30 seconds with a pumice/water slurry in a rubber cup at low-speed. The samples were then rinsed for 20 seconds with an air-water spray and dried with oil-free compressed air for another 20 seconds. After the root apexes were sealed with cyanoacrylate (Cyano Anaeróbicos, Buenos Aires, Argentina), the teeth were totally covered with two layers of nail varnish except for a 1-mm peripheral margin on the occlusal P&F. The teeth were then immersed in 1% buffered methylene blue dye solution prepared in artificial saliva (Salivar; Farpag Ltda, Buenos Aires, Argentina) and stored at 37 °C. After 48 hours, the teeth were removed from the dye solution, rinsed in tap water and dried. The crowns were separated from the roots at the cementoenamel junction using a diamond disc. The crowns were then embedded in methyl methacrylate resin and sectioned longitudinally on a buccolingual plane using a diamond wavering blade under water-cooling (Isomet, Buehler Ltd, Lake Bluff, IL, USA). A longitudinal section 1 mm thick was obtained at the location of the central fossa.

Evaluation of the sections

After drying with oil-free compressed air, the sections were examined under x14 magnification with stereomicroscope (Carl Zeiss, Oberkochen, Germany) and photographed with a digital Canon Powershot A510 camera (Canon, Tokyo, Japan). Only the side that represented the central fossa was analyzed. The images were downloaded on a computer to enable the length of the P&F to be measured and graded according to the following grading system: C1: P&F extended to half of the enamel thickness; C2: P&F extended beyond half of the enamel thickness without reaching the dentine-enamel junction; C3: P&F extended to the enamel-dentine junction. When a section had more than one P&F, the deepest one was recorded. The images were examined by two independent observers. In case of disagreement, the samples were reexamined jointly until a consensus was reached. The relative frequencies within each group (expressed in percentages) and their corresponding confidence intervals (95%) were then calculated.

RESULTS

All sections revealed the presence of at least one P&F. Descriptive data for P&F classification and frequency along with their confidence intervals are reported in Tables 1 and 2. For pits, 35 and 9 samples corresponded to C1 and C2, respectively

Table 1. Frequency of pit categories

CATEGORY	n	%	95% CONFIDENCE INTERVAL	
			LOWER LIMIT	UPPER LIMIT
C1	35	70.0	57.0	83.0
C2	9	18.0	7.1	28.9
C3	6	12.0	2.8	21.2

Table 2. Frequency of fissure categories

CATEGORY	n	%	95% CONFIDENCE INTERVAL	
			LOWER LIMIT	UPPER LIMIT
C1	15	30.0	17.0	43.0
C2	18	36.0	22.4	49.6
C3	17	34.0	20.5	47.5

(Fig. 1 A and B). Six were considered to be in the C3 category (Fig.1 C). In four of them, incipient traces of dentine dye penetration were observed (Fig.1 D). For fissures, 15 samples corresponded to C1, 18 to C2 (Fig.1 E) and 17 to C3. All samples rated C3 revealed traces of dentine dye penetration (Fig.1 F and G). Based on the 50 studied P&F sections, the enamel-dentine junction was affected in 12% of pits and 34% of fissure samples. Therefore, the null hypothesis was rejected.

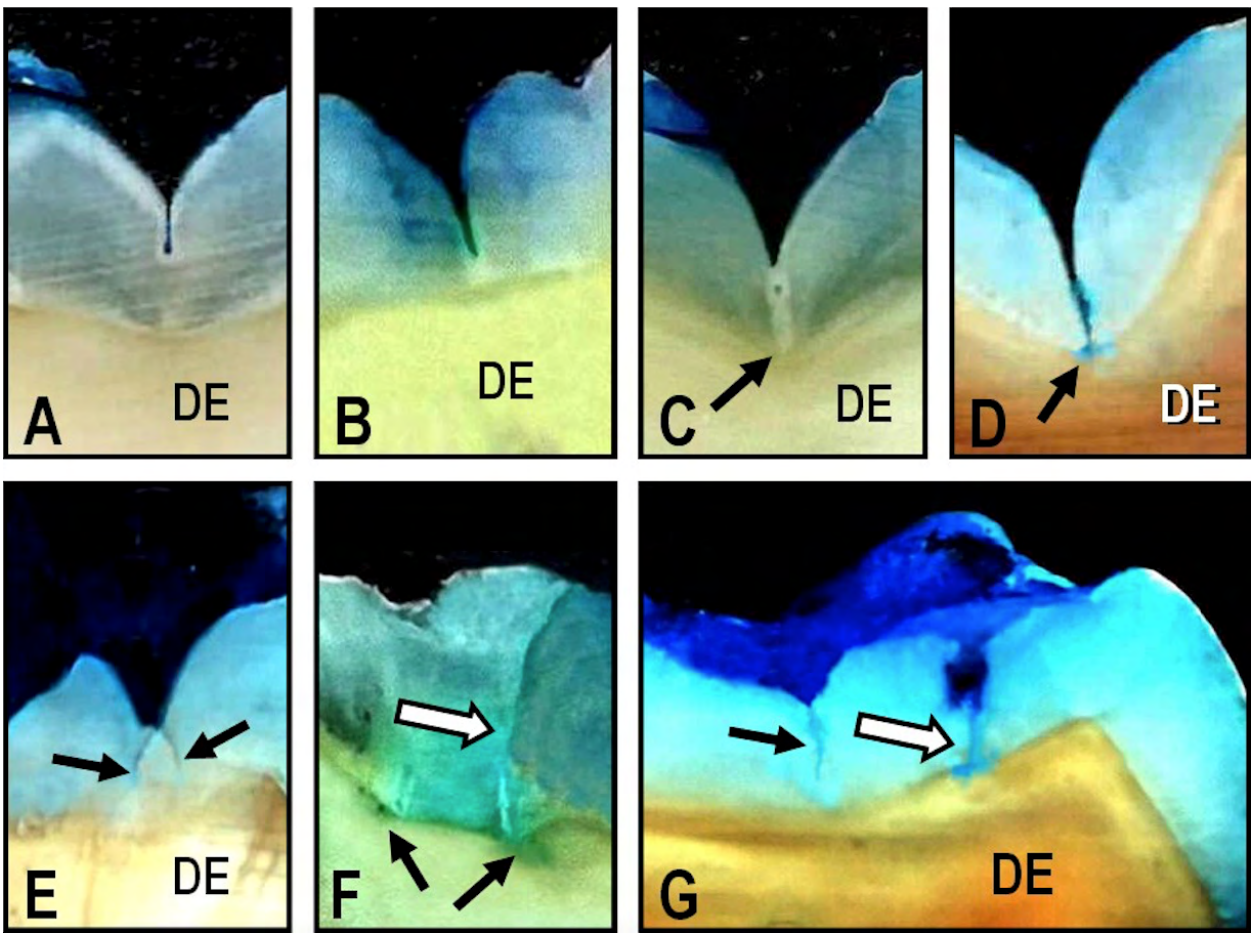

Fig.1: A. Photomicrograph of representative pit formation corresponding to C1. DE: Dentine; Original magnification x14. B. Photomicrograph of representative pit formation corresponding to C2. Note that the pit extension does not reach the enamel-dentine junction. DE: Dentine; Original magnification x14. C: Photomicrograph of representative C3 pit formation reaching the enamel-dentine junction (arrow). DE: Dentine; Original magnification x14. D. Photomicrograph of representative pit formation corresponding to C3 showing incipient dentine dye penetration (arrow). DE: Dentine; Original magnification x14. E. Photomicrograph showing two fissure formations corresponding to C2 (arrows). Note that both fissures started at the deepest part of a pit formation DE: Dentine; Original magnification x14. F. Photomicrograph of representative fissure formation (white arrow) corresponding to C3. Note the presence of dye penetration into dentine and along the enamel-dentine junction (black arrows). Original magnification x14. G. Photomicrograph of two fissures corresponding to C2 (black arrow) and C3 (white arrow). Note the incipient dye penetration along the dentine-enamel junction. DE: Dentine; Original magnification x14.

DISCUSSION

The present study aimed to mimic some of the in vivo conditions in which the enamel is permanently challenged by the oral environment. For this study, the samples were exposed to a methylene blue dye solution prepared in artificial saliva which contained potassium, magnesium and calcium electrolytes, though without bacteria, unlike intra-oral saliva. In order to estimate the frequency and depth of P&F, the methylene blue dye solution was used as the marker. In previous ex vivo studies[1-4], dye leakage was used as a predictor of bacterial penetration. However, its correlation with clinical implications should be interpreted with caution and still requires further research. The results of this ex vivo study showed that the enamel-dentine junction was affected in less than 50% (46/50) of the study samples. From an epidemiologic point of view, this proportion of P&F that reached the enamel-dentine junction is a suitable indicator of the risk of developing dental caries. Thus, we may speculate that in cases of C3 categories, penetration of bacteria into dentinal tubules may occur, leading to further access to the pulpal chamber[7,8].

Due to the presence of fermentable carbohydrates and bacterial by-products in the dentinal tubules, inflammatory pulp reactions causing pain are frequently reported by patients[7]. Björndal and Mjör[8] emphasized that the internal morphology of the interlobar grooves, as well as the potential depth of P&F, are important factors to consider during clinical examination. However, Ricketts et al[11] reported on the difficulty to detect enamel alterations or incipient caries formation in the deepest part of the P&F because the morphology of enamel does not always follow a normal pattern[12,13].

Our results are in agreement with previous reports[10,14] which suggest that every effort should be made to ensure early detection of decalcified areas[14-16], which is a consequence of cariogenic onset due to active acid-producing plaque at the base of P&F. Careful examination of the occlusal anatomy will enable the clinician to select the most effective treatment for P&F[4, 17-20] and make the decision to restore with a filling or apply a P&F sealant. Unprotected (unsealed) P&F can act as an open gate for the entry of bacteria and other irritants from the oral environment. However, since this study was performed under ex vivo conditions, its clinical relevance needs to be interpreted with caution.

CONCLUSION

Within the limitations of the present study, we conclude that in human mandibular third molars, the P&F frequently reach the dentin-enamel junction. When this is the case, there is a potential open gate for bacteria and other irritants from the oral environment to penetrate the dentinal tubules, thereby enabling bacteria and bacterial toxins to reach the dental pulp. This may explain the clinical symptoms reported by patients in otherwise healthy teeth.

ACKNOWLEDGMENTS

The authors are grateful to Dr. Susana Alvarez Serrano and Dr. Fanny Fernandez for their technical assistance.

DECLARATION OF CONFLICTING INTERESTS

The authors declare no potential conflicts of interest regarding the research, authorship, and/or publication of this article.

FUNDING

None.

CORRESPONDENCE

Dr. Osvaldo Zmener
Julian Alvarez 2335 3ro.
(1425), Ciudad Autónoma de Buenos Aires
Argentina
osvaldo@zmener.com.ar

REFERENCES

1. Gillet D, Nancy J, Dupuis V, Dorignac G. Microleakage and penetration depth of three types of materials in fissure sealant: self-etching primer vs etching: an in vitro study, J Clin Pediatr Dent 2002; 26:175-178.
2. Chan DCN, Summitt JB, García-Godoy F, Hilton T et al. Evaluation of different methods for cleaning and preparing occlusal fissures. Oper Dent 1999;24: 331-336.
3. Pardi V, Sinhoreti MAC, Pereira AC, Ambrosano GMB et al. In vitro evaluation of microleakage of different materials used as pit-and-fissure sealants. Braz Dent J 2006;17: 49-52.
4. Asselin ME, Fortin D, Sitbon Y, Rompré PH. Marginal microleakage of a sealant applied to permanent enamel: Evaluation of 3 application protocols. Pediatr Dent 2008;30: 29-33.
5. Markovic DL, Petrovick BB, Peric TO, Trisic D et al.

Evaluation of sealant penetration in relation to fissure morphology, enamel surface preparation protocol and sealing material. Oral Health Prev Dent 2019;17:349-355.
6. Cruvivnel VRN, Azevedo BC, Gravina DBL, Toledo et al. Clinical analysis of molar fissures by Cone-Beam Tomography. J Clin Pediatr Dent 2007;31:235-239.
7. Zero DT, Ferreira-Zandona A, Vail MM, Spolnik KJ. Dental caries and pulpal disease. Dent Clin North Am 2011;55: 29-46.
8. Björndal L, Mjör A. Pulp-dentin biology in restorative dentistry. 4. Dental caries – characteristics of lesions and pulpal reactions. Quintess Int 2001; 32:717-736.
9. Lussi A, Imwinkelried S, Pitts N, Longbottom C et al. Perfomance and reproducibility of a laser fluorescence system for detection of occlusal caries in vitro. Caries Res 1999;33:261-266.
10. Sanchez-Perez L, Irigoyen-Camacho ME, Molina-Frechero N, Zepeda-Zepeda M. Fissure depth and caries incidence in first permanent molars: A five-year follow-up study in schoolchildren. Int J Environ Res Public Health 2019;16:3550-3560.
11. Ricketts D, Kidd D, Weerheijm K, De Soet H. Hidden caries: What is it? Does it exist? Does it matter? Int Dent J 1997;47:259-265.
12. Lussi A. Validity of diagnostic and treatment decisions of fissure caries. Caries Res 1991;25:296-303.
13. Symons AL, Chu CY, Meyers IA. The effect of fissure morphology and pretreatment of the enamel surface on penetration and adhesion of fissure sealants, J Oral Rehabil 1996;23:791-798.
14. Ando M, van Der Veen MH, Schemehorn BR, Stookey GK. Comparative Study to quantify demineralized enamel in deciduous and permanent teeth using laser – and light – induced fluorescence techniques. Caries Res 2001;35:464-470.
15. Ferreira-Zandona A, Zero D. Diagnostic tools for early caries detection. J Am Dent Assoc 2006; 137: 1675-1684. Erratum in: J Am Dent Assoc 2007;138:298.
16. Shi X, V. Welander V. Occlusal caries detection with Kavo Diagnodent and radiography. An in vitro comparison. Caries Res 2000;34:51-158.
17. Peumans M, Canumilli P, De Munk J, Van Landuyt K et al. Clinical effectiveness of contemporary adhesives: A sistematic review of current clinical trials. Dent Mater 2005; 21:864-881.
18. Sakkas C, Khomenko L, Trachuk I. A comparative study of clinical effectiveness of fissure sealing with and without bonding systems: 3-year results. Eur Arch Pediatr Dent 2013; 14:73-81.
19. Meller C, Reichenmiller K, Schwahn C, Samietz S et al. Resin- based pit-and-fissure sealants: Microleakage reduction and infiltration enhancement using a bonding agent. J Adhes Dent 2015;17:59-65.
20. Al-Jobair A, Al-Hammad N, Aladhan S, Salama F. Retention and caries-preventive effects of glass ionomer and resin-based sealants: An 18-months-randomized clinical trial. Dent Mater J 2017;36:654-661.

Maxillary incisor internal root anatomy evaluated by cone-beam computed tomography in a population of the Autonomous City of Buenos Aires, Argentina

Eugenia P. Consoli Lizzi[1], Romina Chaintiou Piorno[1], Claudia M. Aranda[1], Ariel F. Gualtieri[2], Pablo A. Rodríguez[1]

1. Universidad de Buenos Aires, Facultad de Odontología, Cátedra de Endodoncia, Buenos Aires, Argentina
2. Universidad de Buenos Aires, Facultad de Odontología, Cátedra de Biofísica y Bioestadística, Buenos Aires, Argentina

ABSTRACT

In the field of anthropology, discrete traits are considered as minimal epigenetic variations. However, they can elicit complications in endodontic therapy. Thorough understanding of root canal morphology is essential to achieving predictable results in endodontic practice, and may be attained by using cone-beam computed tomography (CBCT) scans. The aim of the present study was to research the internal root anatomy of maxillary central and lateral incisors in vivo and quantify its variation in a population of the Autonomous City of Buenos Aires, Argentina. A total 697 CBCT scans from a pre-existing database were observed, and the configuration type for each tooth was determined according to Vertucci's classification. The data were described by absolute frequencies and percentages with 95% confidence intervals (CI). The CI was estimated by the Wilson Score method. Chi-square test (χ^2) was used for comparing frequencies, with a 5% significance level. 238 CBCT scans met the inclusion criteria, resulting in 761 teeth assessed. Vertucci Type I configuration was observed in 760 teeth (99.9%) and the Type II was found in only one tooth (0.1%), in which the anatomy was compatible with dens in dente. When differences were analyzed according to sex, all the teeth in all women had Vertucci Type I configuration. In men, all maxillary central incisors were Vertucci Type I. Of 151 maxillary lateral incisors, 150 had Vertucci Type I configuration (99.3%) and 1 had Type II (0.7%). Conclusions: Maxillary incisor internal root anatomy prevalence was estimated from CBCT scans for the first time in an Argentine population. 99.9% of the sample presented Vertucci Type I configuration, and 0.1% had Vertucci Type II configuration. The clinical finding of maxillary incisors with anatomical complexity should be considered as a possibility in endodontic practice.

Received: December 2020; Accepted: June 2021.

Keywords: *cone-beam computed tomography - endodontics - anatomy - morphology - root canal.*

Anatomía radicular interna de incisivos superiores evaluados mediante tomografía cone-beam en una población de Buenos Aires, Argentina

RESUMEN

En el ámbito de la antropología, los rasgos discretos son considerados variaciones epigenéticas mínimas, pero pueden traer complicaciones en la terapia endodóntica. Comprender la morfología del conducto radicular es fundamental para lograr resultados predecibles en la práctica endodóntica, y esto puede lograrse mediante el uso de la tomografía cone-beam (CBCT). El objetivo de este trabajo fue investigar de manera in vivo la anatomía radicular interna de incisivos centrales y laterales superiores, y cuantificar su variación en una población de la Ciudad Autónoma de Buenos Aires, Argentina. 697 CBCTs de una base de datos preexistente fueron analizadas, y se consignó para cada pieza el tipo de configuración basada en la clasificación de Vertucci. Los datos se describieron mediante frecuencias absolutas y porcentajes con intervalos de confianza al 95% (IC95). Los IC95 fueron estimados mediante el método score de Wilson. Para la comparación de frecuencias se utilizó la prueba de Chi-cuadrado (χ^2), con un nivel de significación de 5%. 238 CBCTs cumplieron con los criterios de inclusión, resultando en 761 piezas evaluadas. Se encontró un Vertucci tipo I en 760 piezas (99,9%) y se halló Vertucci tipo II en una sola pieza dentaria (0,1%), que mostraba anatomía compatible con dens in dente. Diferenciando por sexos, todas las mujeres para todas las piezas mostraron Vertucci tipo I. Los varones en sus incisivos centrales superiores poseían Vertucci tipo I en todas las piezas, y de los 151 incisivos laterales superiores, 150 mostraron tipo I de Vertucci (99,3%) y 1, tipo II (0,7%). Conclusión: La prevalencia de anatomía dentaria interna fue estimada por primera vez en una población argentina mediante CBCTs. El 99,9% de la muestra presentó un Vertucci tipo I, y el 0,1% un Vertucci tipo II. La aparición clínica de incisivos superiores con complejidad anatómica debe ser considerada posible en la práctica endodóntica.

Palabras clave: *tomografía de haz cónico - endodoncia - anatomía - morfología - conducto radicular.*

INTRODUCTION

Tooth anatomy, size and morphology are closely related to the evolutionary processes and diet, playing a pivotal role in human survival. Discrete traits (cusps and accessory ridges, roots and extra canals) are considered as minimal epigenetic variations in the field of dental anthropology. Within this discipline, they constitute an important field of research that can be applied to evaluating biological distances among past populations from a bioarchaeological perspective, as well as to assigning missing persons to a given population during the identification processes in the field of forensic anthropology[1,2]. On the other hand, in endodontic practice, these traits might hinder treatment success. It is widely acknowledged that understanding root canal morphology and its possible variations is of the utmost importance to achieving predictable endodontic outcomes and avoiding potential complications. It is therefore essential that the clinician be acquainted with the available tools to improve treatment planning[3], including radiographic studies, which are crucial to treating teeth with pulpal pathology[4,5].

According to the American Academy of Oral and Maxillofacial Radiology (AAOMR) and the American Associations of Endodontists (AAE), among the imaging studies, periapical radiography should be considered the first choice for assessing a tooth with endodontic pathosis[6]. The number of root canals and the presence and location of associated periapical lesions should be confirmed by radiographic assessment in order to reach the most accurate treatment planning[7,8]. However, it should be considered that traditional periapical radiography presents some drawbacks, such as two-dimensional imaging, sensitivity to distortion because of anatomical structures and the possibility of incorrect acquisition techniques or processing errors[9]. Digital radiology (radiovisiography) has the advantages of overcoming difficulties in image processing and enabling easier documentation of clinical cases, among others[10]. Cone-beam computed tomography (CBCT) is a non-invasive tool capable of overcoming the aforementioned problems which can occur in both traditional and digital periapical radiographs. CBCT is very useful for acquiring anatomic knowledge of the teeth and surrounding structures, as well as for the diagnosis and management of endodontic complication[11], and it has been widely shown to improve the location, description and analysis of unusual dental structures such as *dens invaginatus*[12], C-shaped canal configuration[13] and extra roots[14].

Several authors describe maxillary incisors as teeth with one canal and one root in 100% of the cases [Green (1956)[15], Pineda and Kuttler (1972)[16], and Vertucci (1984)[17]]. The presence of extra canals in this group of teeth is described as extraordinary[18,19]. Nevertheless, another study has reported that it is possible to identify a high diversity of anatomical variations in root canals. Moreover, all teeth – not only a specific group – can present additional canals, which is why canal configuration variations should be considered normal rather than exceptional[20].

The aim of this study was to describe the internal root anatomy of maxillary central and lateral incisors and to quantify its variation in a population of the Autonomous City of Buenos Aires, by assessing CBCT scans taken at the Diagnostic Imaging Department, School of Dentistry of the University of Buenos Aires (FOUBA), Argentina.

MATERIALS AND METHODS

Study design and place

An observational, cross-sectional, descriptive study was designed. The research was conducted by assessing CBCT scans of patients who received care at the FOUBA Diagnostic Imaging Department, which has three tomographs. The device used in this study, as well as the research period, were selected randomly. During 2019, a total 211,146 patients received care at the FOUBA and 10,640 CBCT scans were taken, adding up to a total 298,362 services provided.

Tomographic volumes

Tomographic volumes were acquired with a Planmeca ProMax® 3D Max (Planmeca OY, Helsinki, Finland) tomograph with 88 kV and 9.0 mA, exposure time 12.07 seconds and 150-200 µm voxel size. The CT scans were requested for diagnosis or follow-up of pre-existing pathologies, which were not the reason for the present research. The patients signed the informed consent form by which they understood that their examinations could be used for academic purposes, with their identity being preserved (FOUBA Resolution CD N° 983).

Data collection

This research was conducted through the assessment

of 697 CBCT scans of patients who received care at the aforementioned Department from February to March 2019. The CBCT scans were assessed by the direct observation of volumes by two calibrated endodontists who specialized in the detection of unusual internal dental anatomy. Shifts of 1 ½ hour per day per observer were arranged, to avoid visual strain and potential misinterpretation of the images. Data were collected by direct observation of complete DICOM (.dcm) volumes using the scanner's own software (Planmeca Romexis Viewer Launcher version 4.6.0.R. released 02/20/2017, Planmeca OY, Helsinki, Finland). The information was recorded in spreadsheets especially designed for this report.

Selection criteria

Inclusion criteria: Maxillary CBCT scans of patients, regardless of age and sex, with at least one permanent central or lateral incisor with developed apex.

Exclusion criteria: Teeth with previous canal therapy, crown destruction below the cementoenamel junction, or internal or external resorptions.

Elimination criteria: CBCT scans with artifacts or noise interfering with correct image interpretation.

Image assessment

Once the volumes had been selected, biological sex at birth (sex), presence or absence of maxillary central and lateral incisors, and internal root anatomy according to Vertucci[17] for the existing incisors were assigned. To describe internal root anatomy, the following sequence was applied for all volumes: the window "Explorer" in the software was selected, the smallest slice admitted by the volume was chosen, and the axial and coronal plane levels were set for the target tooth. The resulting image was observed in the sagittal plane window and classified according to Vertucci[17]:

Type I: A single canal extends from the pulp chamber to the apex.

Type II: Two separate canals leave the pulp chamber and join short of the apex to form one canal.

Type III: One canal leaves the pulp chamber, divides into two within the root, and then merges to exit as one canal.

Type IV: Two separate and distinct canals extend from the pulp chamber to the apex.

Type V: One canal leaves the pulp chamber and divides short of the apex into two separate and distinct canals with separate apical foramina.

Type VI: Two separate canals leave the pulp chamber, merge in the body of the root, and redivide short of the apex to exit as two distinct canals.

Type VII: One canal leaves the pulp chamber, divides and then re-joins within the body of the root, and finally re-divides into two distinct canals short of the apex.

Type VIII: Three separate and distinct canals extend from the pulp chamber to apex.

Statistical analysis

The data were described by absolute frequencies (AF) and as percentages with 95% confidence interval (CI). The CI was estimated by the Wilson Score method[21]. A Chi-square test (χ^2) was used for comparing frequencies, with a 5% significance level. The following software types were used: Calc (Apache OpenOfficeTM) v. 4.1.3[22], Infostat v. 2018[23] and MedCalc v. 19.0.4[24].

RESULTS

A total 697 CBCT scans were observed, of which 238 met the inclusion criteria, resulting in 761 teeth assessed. Vertucci Type I configuration was found in 760 teeth, which represents 99.9% (CI95: 99.3 to 100.0) (Fig. 1).

Anatomy compatible with Vertucci Type II was found in only one tooth, representing 0.1% (CI95: 0.0 to 0.7). This tooth was associated with *dens in dente* anomaly (Fig. 2).

A hundred and ninety-one absent teeth (20%; CI95: 18% to 23%) and 761 present teeth (80%; CI95: 77% to 82%) were observed, this difference being meaningful (χ^2=341.28; df=1; p<0.05). No significant association was found between the type of tooth and its presence (χ^2=2.27; df=3; p=0.52).

When the Vertucci type configuration was analyzed according to tooth type, in teeth 2.1, 1.1 and 1.2, only Vertucci Type I was found. Among the 185 maxillary left lateral incisors studied (tooth 2.2), 184 corresponded to Vertucci Type I (99.5%; CI95: 97.0% to 99.9%) and only 1 corresponded to Type II, accounting for 0.5% (CI95: 0.1% to 3.0%) (Fig. 3 A).

When the sample was differentiated according to sex, all teeth in all females were Vertucci Type I. In males, Vertucci Type I was apparent in all maxillary central incisors. Among the 151 maxillary lateral incisors, 150 were Vertucci Type I (99.3%; CI95: 96.3% to 99.9%) and 1 was Vertucci Type II, accounting for 0.7% (CI95: 0.1% to 3.7%) (Fig. 3 B).

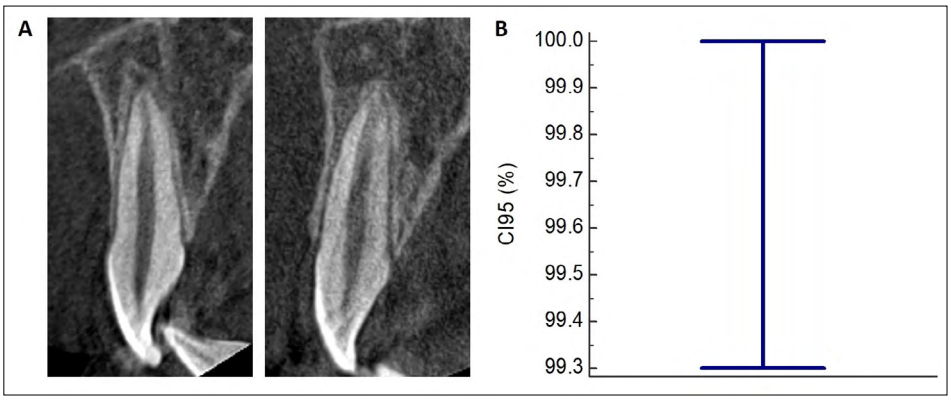

Fig. 1: A. Sagittal plane showing Vertucci Type I. B. A 95% confidence interval. Interval upper and lower limits: 99.3% - 100.0%.

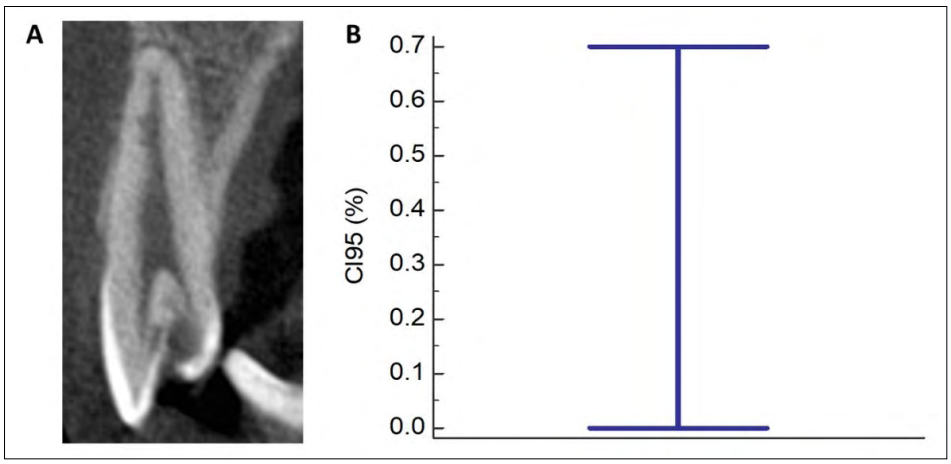

Fig. 2: A. CBCT sagittal plane showing Vertucci Type II. B. A 95% confidence interval. Interval upper and lower limits: 0.0% - 0.7%.

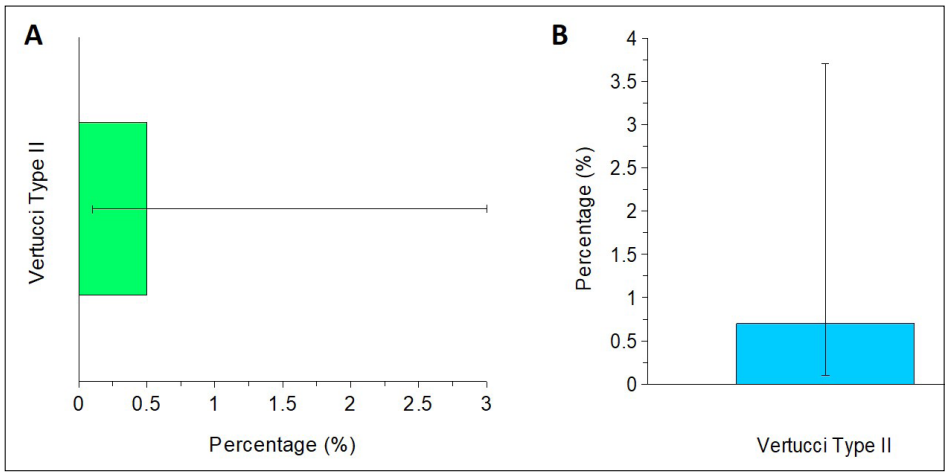

Fig. 3: A. Vertucci Type II configuration in tooth 2.2. B. Vertucci Type II configuration in male maxillary lateral incisors. Bar graph: % (CI95).

DISCUSSION

In the field of anthropology and bioarchaeology, discrete trait variation has been used as an important tool in the study of biological and social change from an evolutionary perspective[25], as well as the characterization and differentiation of ethnic groups, and the evaluation of biodistances, migratory processes and changes in the gene flow,

in both current and past populations[26-29]. This is possible given the high heritability of dental traits, which implies that a large part of the observed inter-sample variations can be explained by genetic differences[30,31] Additionally, from the standpoint of dentistry, the thorough understanding of the root canal morphology is essential to achieving predictable endodontic results. In this regard, failure to locate root canals entails a clearly deficient technique, one of the major causes of endodontic failure[32].

Maxillary incisors usually have a single canal[15-17], consistently with the results of the current study, in which Vertucci Type I was identified for the 99.9% of the sample (CI95: 99.3 to 100.0). Incisors with more than one root canal are rarely described in the literature[12,18,19], in agreement with the results obtained in the current research (Vertucci Type II: 0.1%; CI95: 0.0 to 0.7). Vertucci Type II association with the analogy of the *dens in dente* anomaly in a maxillary anterior tooth has been described in a case report by Liji et al.[12], as in the current research.

Sample size, sex and ethnicity are factors that should be addressed regarding the root canal variability. Sert & Bayirly[33] reported that sex and ethnic origin can influence the variability of root canal anatomy. These authors analyzed maxillary lateral incisors in a sample from the Turkish population, identifying very similar percentages of Vertucci Type I according to sex (90% in women, n=100 and 91% in men, n=100). On the other hand, Altunsoy et al.[34] reported that the prevalence of two canals was higher in males than in females in maxillary anterior teeth, regarding sex as an important variable. Their report on a sample of the Turkish population analyzed the differences in CBCT scans according to sex. For maxillary central incisors, males (n=775) had Vertucci Type I: 99.5%, Type III: 0.4%, and Type V: 0.1%, and females (n=768) had Vertucci Type I: 99.7% and Type IV: 0.3%. For maxillary lateral incisors, males (n=759) had Vertucci Type I: 96.7%, Type II: 1.3%, Type III: 0.7% and Type IV: 1.3%, and females (n=745) had Vertucci Type I: 98.3%, Type II: 0.7%, Type IV and V: 0.5%.

Martins et al.[35] compared CBCT scans of maxillary central and lateral incisors of Chinese (n=440) and Portuguese (n=1846) populations, finding Vertucci Type I for 100% of the sample. Pan et al.[36] analyzed the Malasyan population CBCT scans of 347 maxillary central incisors and 362 maxillary lateral incisors, also finding Vertucci Type I in 100% of the sample. Da Silva et al.[37] analyzed CBCT scans of maxillary central incisors (n=200) in the Brazilian population, finding Vertucci Type I anatomy in 98%, and Type II and V in 1%. In maxillary lateral incisors (n=200), Vertucci Type I was 96%, Type II, 3.5% and Type III, 0.5%.

The population Argentina is considered to be heterogeneous in origin, with the immigrant component interacting with the previous native substrate in diverse ways[38,39]. This is why the variability in ethnicity should be considered as a key factor in root canal anatomical diversity. The data in this report were acquired in a single center in Argentina, located in the Autonomous City of Buenos Aires, which constitutes a limitation regarding the impact of the results obtained. Although the FOUBA is considered a national level reference and referral center, the origin of the sample limits its variability and reduces the possibility of extrapolating the research results to other regions of the country. Only one report on the Argentinian population has been found in the literature, which makes exclusive reference to the prevalence of the C-shaped canal anatomy in mandibular second molars evaluated by CBCT scans[40]. The lack of previous reports discussing the dental internal anatomic morphology of maxillary incisors assessed by CBCT scans in Argentina makes this study an important contribution to the knowledge of internal root anatomy in a sample from the Autonomous City of Buenos Aires.

CONCLUSION

Maxillary incisor internal root anatomy prevalence was estimated by CBCT scans for the first time in an Argentine population. The highest prevalence of internal anatomy found and assessed by CBCTs for maxillary incisors was a single canal, corresponding to Vertucci Type I configuration, observed in 99.9% of the sample. The remaining 0.1% was only one tooth with two canals joining in the middle third, with Vertucci Type II configuration. The clinical finding of anatomically complex maxillary incisors should be considered as a possibility in endodontic practice.

ACKNOWLEDGMENTS
The authors acknowledge the FOUBA Diagnostic Imaging Department for providing the volumes assessed in this report.

DECLARATION OF CONFLICTING INTERESTS
The authors declare no potential conflicts of interest regarding the research, authorship, and/or publication of this article.

FUNDING
None

CORRESPONDENCE
Dr.Eugenia Pilar Consoli Lizzi
Calle 46 530 1 A.
La Plata, Pcia. Buenos Aires, Argentina.
eugenia.consoli@odontologia.uba.ar

REFERENCES

1. Irish JD & Scott GR: Introduction to dental Anthropology. In: Irish JD & Scott GR: A Companion to Dental Anthropology. Oxford: Wiley Blackwell, 2016.
2. Scott GR. Dental Anthropology. In: Smith C. Encyclopedia of Global Archaeology. Springer Cham, 2018. URL: https://doi.org/10.1007/978-3-319-51726-1_138-2.
3. Vertucci FJ. Root canal morphology and its relationship to endodontic procedures. Endod Topics 2005;10:3-29. doi: 10.1111/j.1601-1546.2005.00129.x.
4. Patel S, Dawood A, Mannocci F, Wilson R et al. Detection of periapical bone defects in human jaws using cone beam computed tomography and intraoral radiography. Int Endod J 2009;42:507-515. doi:10.1111/j.1365-2591.2008.01538.x.
5. Özen T, Kamburoğlu K, Cebeci ARİ, Yüksel SP et al. Interpretation of chemically created periapical lesions using two different dental cone-beam computerized tomography units, an intraoral digital sensor, and conventional film. Oral Surg Oral Med Oral Pathol Oral Radiol Endod 2009;107:426–432. doi:10.1016/j.tripleo.2008.08.017.
6. Nair M, Fayad MI, Levin MD, Benavides E et al. AAE and AAOMR joint position statement. Oral Surg Oral Med Oral Pathol Oral Radiol 2015;120:508–512. doi:10.1016/j.oooo.2015.07.033.
7. Lofthag-Hansen S, Huumonen S, Gröndahl K, Gröndahl H-G. Limited cone-beam CT and intraoral radiography for the diagnosis of periapical pathology. Oral Surg Oral Med Oral Pathol Oral Radiol Endod 2007;103:114–119. doi:10.1016/j.tripleo.2006.01.001.
8. Low KMT, Dula K, Bürgin W, von Arx T. Comparison of periapical radiography and limited cone-beam tomography in posterior maxillary teeth referred for apical surgery. J Endod 2008;34:557–562. doi:10.1016/j.joen.2008.02.022.
9. Ørstavik D, Larheim TA: Radiographic interpretation. In: Ingle JI, Bakland LK, Baumgartner JC: Ingle's endodontics 6. Hamilton, Canada: BC Decker inc, 2008:600-625.
10. Nair MK, Levin MD, Nair UP: Radiographic interpretation. In: Hargreaves KM, Berman L: Cohen's pathways of the pulp. St. Louis, Missouri, USA: Elsevier, 2016:33-70.
11. Patel S, Brown J, Pimentel T, Kelly RD, et al. Cone beam computed tomography in endodontics – a review of the literature. Int Endod J 2019;52:1138-1152. doi:10.1111/iej.13115.
12. Liji M, Chandrababu K, Kumar M, Jayashree S. Type II canal configuration and type I dens invaginatus. J Conserv Dent 2014;17:382-384. doi:10.4103/0972-0707.136517.
13 . Chaintiou Piorno R, Consoli Lizzi EP, Lenarduzzi A, Rodríguez PA. Reto de la endodoncia: conducto en ̇C ̈. Rev Fac Odontol Univ B Aires 2018;33:5-9. URL: http://odontologia.uba.ar/wp-content/uploads/2018/06/revvol33num74_2018_art1.pdf
14. Gopal S, John G, Pavan Kumar K, Latha S et al. Endodontic treatment of bilateral maxillary first premolars with three roots using CBCT: a case report. Case Rep Dent 2014;2014:505676:1-4. doi:10.1155/2014/505676.
15. Green D. A stereomicroscopic study of the root apices of 400 maxillary and mandibular anterior teeth. Oral Surg Oral Med Oral Pathol 1956;9:1224–1232. doi:10.1016/0030-4220(56)90192-x.
16. Pineda F, Kuttler Y. Mesiodistal and buccolingual roentgenographic investigation of 7,275 root canals. Oral Surg Oral Med Oral Pathol 1972;33:101–110. doi: 10.1016/0030-4220(72)90214-9.
17. Vertucci FJ. Root canal anatomy of the human permanent teeth. Oral Surg Oral Med Oral Pathol 1984;58:589–599. doi:10.1016/0030-4220(84)90085-9.
18. Kavitha M, Gokul K, Ramaprabha B, Lakshmi A. Bilateral presence of two root canals in maxillary central incisors: a rare case study. Contemp Clin Dent 2014;5:282-286. doi:10.4103/0976-237X.132354.
19. Sponchiado EC, Qader Ismail HAA, Lima Braga MR, de Carvalho FK et al. Maxillary central incisor with two root canals: a case report. J Endod 2006;32:1002–1004. doi:10.1016/j.joen.2006.03.022.
20. Slowey RR. Radiographic aids in the detection of extra root canals. Oral Surg Oral Med Oral Pathol 1974;37:762–772. doi:10.1016/0030-4220(74)90142-X.
21. Newcombe RG, Merino Soto C. Intervalos de confianza para las estimaciones de proporciones y las diferencias entre ellas. Interdisciplinaria 2006;23:141-154.
22. Apache Software Foundation. Apache OpenOfficeTM v. 4.1.3. (software). 2016. Available from https://www.openoffice.org.
23. Di Rienzo JA, Casanoves F, Balzarini MG, Gonzalez L et al. InfoStat versión 2018 (software). 2018. Grupo InfoStat, FCA, Universidad Nacional de Córdoba, Argentina. Available from URL http://www.infostat.com.ar.
24. MedCalc Software bvba. MedCalc Statistical Software version 19.0.4 (software). 2019. Ostend, Belgium. Available from http://www.medcalc.org.
25. Cavalli-Sforza LL, Piazza A, Menozzi P, Mountain J. Reconstruction of human evolution: bringing together genetic, archaeological, and linguistic data. Proc Nat Acad Sci USA 1988;85:6002-6006.
26. Hanihara T. Biological relationships among Southeast Asian, jomonese, and the pacific populations as viewed from dental characters. The basis populations in East Asia, X. J Anthrop Soc Nippon 1992;100:53-67.
27. Turner CG II, Nichol CR, Scott GR: Scoring procedures for key morphological traits of the permanent dentition: the

Arizona State University dental anthropology system. In: Kelley MA, Larsen CS: Advances in dental anthropology. New York, USA: Wiley-Liss,1991:13-31.
28. Matsumura H, Hudson M. Dental perspectives on the population history of Southeast Asia. Am J Phys Aanthropol 2005;127:192-209. https://doi.org/10.1002/ajpa.20067.
29. Coppa A, Cucina A, Lucci M, Mancinelli D et al. Origins and spread of agriculture in Italy: a nonmetric dental analysis. Am J Phys Aanthropol 2007;133:918-930. https://doi.org/10.1002/ajpa.20620.
30. Scott GR: Dental morphology. In: Katzenberg MA, Saunders SR, eds. Biological anthropology of the human skeleton. New York, USA: Wiley-Liss, 2008:265-298.
31. Bollini G, Atencio JP, Colantonio SE. El hipocono en poblaciones aborígenes de Argentina. Un análisis comparativo poblacional. Rev Arg Antrop Biol 2012;14:57-64. http://sedici.unlp.edu.ar/handle/10915/24490
32. Tabassum S, Khan FR. Failure of endodontic treatment: The usual suspects. Eur J Dent 2016;10:144–147. doi:10.4103/1305-7456.175682.
33. Sert S, Bayirli G. evaluation of the root canal configurations of the mandibular and maxillary permanent teeth by gender in the Turkish population. J Endod 2004;30:391–398. doi:10.1097/00004770-200406000-00004.
34. Altunsoy M, Ok E, Nur BG, Aglarci OS, et al. A cone-beam computed tomography study of the root canal morphology of anterior teeth in a Turkish population. Eur J Dent 2014;8:302–306. doi:10.4103/1305-7456.137630.
35. Martins JNR, Gu Y, Marques D, Francisco H et al. Differences on the root and root canal morphologies between Asian and white ethnic groups analyzed by cone-beam computed tomography. J Endod 2018;44:1096–1104. doi:10.1016/j.joen.2018.04.001.
36. Pan JYY, Parolia A, Chuah SR, Bhatia S et al. Root canal morphology of permanent teeth in a Malaysian subpopulation using cone-beam computed tomography. BMC Oral Health 2019;19:14. doi:10.1186/s12903-019-0710-z.
37. da Silva EJ, de Castro RW, Nejaim Y, Silva AI et al. Evaluation of root canal configuration of maxillary and mandibular anterior teeth using cone beam computed tomography: An in-vivo study. Quintessence int 2016;47:19–24. doi:10.3290/j.qi.a34807.
38. Avena SA, Goicoechea AS, Rey J, Dugoujon JM, et al. Mezcla génica en una muestra poblacional de la Ciudad de Buenos Aires. Medicina 2006;66:113-118. http://medicinabuenosaires.com/revistas/vol66-06/2/MEZCLA%20GENICA%20EN%20UNA%20MUESTRA%20POBLACIONAL%20DE%20LA%20CIUDAD%20DE%20BUENOS%20AIRES.pdf
39. Di Fabio Rocca F, De la Vega D, Russo G, Raggio C et al.: El aporte africano al acervo génico de la población de Rosario, Santa Fé. In: Ghidoli ML & Martínez Peria JF: Estudios afrolatinoamericanos. Nuevos enfoques multidisciplinarios. Buenos Aires, Argentina: Ediciones del CCC Floreal Gorini, 2013:383-398.
40. Chaintiou Piorno R, Consoli Lizzi EP, Saiegh J, Vázquez DJ et al. C-Shaped Canal System in Mandibular Second Molars Evaluated by Cone-Beam Computed Tomography in an Argentinean Subpopulation. GJMR 2019;19:17-23.

Anxiety about dental treatment – a gender issue

Manoela T.S. Dadalti[1], Antônio J.L. Cunha[2], Thaís G.D. Souza[3], Brunna A. Silva[3], Ronir R. Luiz[4], Patrícia A. Risso[3]

1. Universidade Federal do Rio de Janeiro, Faculdade de Medicina, Departamento de Clínica Médica, Rio de Janeiro, Brasil.
2. Universidade Federal do Rio de Janeiro, Faculdade de Medicina, Departamento de Pediatria, Rio de Janeiro, Brasil.
3. Universidade Federal do Rio de Janeiro, Faculdade de Odontologia, Departamento de Clínica Odontológica, Rio de Janeiro, Brasil.
4. Universidade Federal do Rio de Janeiro, Instituto de Estudos em Saúde Coletiva, Rio de Janeiro, Brasil.

ABSTRACT
This study compared prevalence and risk factors of dental anxiety between men and women. The sample consisted of 244 participants (n = 122 men) aged 18 years or older who sought dental care at a public Dental Education Institution from March 2018 to November 2019. The Modified Dental Anxiety Scale was used to determine presence of dental anxiety. The following risk factors were recorded: age, years of schooling, preoperative pain, and type of dental treatment. Bivariate analysis was used to assess the difference in dental anxiety between the sexes. Multivariate logistic regression was used to analyze the association between dental anxiety and gender, regardless of the influence of other variables. Total prevalence of dental anxiety was 18% (n = 44), 22.9% (28/122) in women and 13.1% (16/122) in men (p = 0.04). Gender (odds ratio: 1.83, 95% confidence interval: 0.92–3.62) and preoperative pain (odds ratio: 2.095, 95% confidence interval: 0.97–4.49) were associated with dental anxiety. We concluded that women had a higher prevalence of dental anxiety. Preoperative pain was associated with dental anxiety regardless of gender.
Received: March 2021; Accepted: June 2021.

Keywords: *dental anxiety - dental care - gender - pain.*

Ansiedade em relação ao tratamento dentário - uma questão de gênero

RESUMO
Este estudo avaliou a prevalência e os fatores de risco da ansiedade odontológica entre homens e mulheres. O cálculo amostral foi composto por 244 participantes (n = 122 homens) com 18 anos ou mais que procuraram atendimento odontológico em uma instituição pública de Educação Odontológica no período de março de 2018 a novembro de 2019. A Escala de Ansiedade Odontológica Modificada foi utilizada para determinar a presença de ansiedade odontológica. Os seguintes fatores de risco também foram coletados: idade, anos de estudo, dor pré-operatória e tipo de tratamento odontológico. A análise bivariada foi usada para avaliar a diferença na ansiedade odontológica entre os gêneros. A regressão logística multivariada foi utilizada para analisar a associação entre ansiedade odontológica e gênero, independentemente da influência de outras variáveis. A prevalência total de ansiedade odontológica foi de 18% (n = 44), 22,9% (28/122) nas mulheres e 13,1% (16/122) nos homens (p = 0,04). O gênero (odds ratio: 1,83, intervalo de confiança de 95%: 0,92–3,62) e a dor pré-operatória (odds ratio: 2,095, intervalo de confiança de 95%: 0,97–4,49) foram associados à ansiedade odontológica. Concluímos que as mulheres apresentaram maior prevalência de ansiedade odontológica. A dor pré-operatória foi associada à ansiedade odontológica, independentemente do gênero.

Palavras-chave: *ansiedade odontológica - tratamento odontológico - gênero - dor.*

INTRODUCTION

Dental anxiety is an excessive and unreasonable negative emotional state experienced by patients undergoing dental treatment[1]. Its etiology may be related to previous traumatic experiences[2,3] such as severe pain or discomfort during or after a dental procedure and negative observations by the dentist[2,4]. Dental anxiety can affect the patient's oral health, cause negative thoughts, affect social interactions and job performance, and impact self-esteem and self-confidence, influencing the overall quality of life[5,6]. Anxiety is an important barrier to dental care[5] because anxious patients tend to miss, delay, or

cancel appointments, seeking treatment only in acute cases of inflammation and/or infection[7].Patients with dental anxiety have greater rates of caries, gingivitis, and aggressive periodontitis, which are associated with a negative effect on dental and periodontal health[6,8,9]. Gordon et al.[10] considered dental anxiety a public health problem and suggested that special attention should be given to these patients due to the consequences of anxiety on oral health. In addition, dental anxiety increases the likelihood of complications occurring during dental intervention[11], including the onset of systemic changes during dental procedures such as changes in heart rate[2]. A widely used method to assess anxiety level in patients is the Dental Anxiety Scale questionnaire, originally created by Corah[12] and later modified by Humphris et al.[13] and renamed Modified Dental Anxiety Scale (MDAS)[9,11,14–16]. The MDAS consists of five questions with five answer options each, in which the aggregate score suggests the overall dental anxiety level of the patient. Studies performed using MDAS report that the frequency of dental anxiety ranged from 8% to 42.1%[9,11,14–16]. This variation may be related to cultural factors, measurement methods, and the study design[17].

Factors such as age, education level, duration of the dental procedure, and personality traits have also been reported to influence dental anxiety[4,9,11,14–16,18]. Some studies report that female gender was more closely related to dental anxiety[4,9,11,14,18-20], while others disagree[6,15,16,21]. It has been reported that men and women tend to express distress differently due to systems that structure gendered behavior[22,23]. However, it is not known whether the factors that influence dental anxiety in men are the same as in women. Furthermore, the studies comparing anxiety according to gender are not methodologically designed to assess gender as a risk factor for dental anxiety and most of them performed an exploratory analysis using convenience samples. Thus, there are limitations in these assessments due to the absence of a sample calculation designed specifically to assess differences in dental anxiety between the genders. The aim of the present study was therefore to evaluate the prevalence and risk factors of dental anxiety in men and women.

MATERIALS AND METHODS

Study design and population

This cross-sectional study was approved by the University Hospital Clementino Fraga Filho of the Federal University of Rio de Janeiro Ethics and Research Committee (No. 1.526.201). All participants were treated in accordance with the Declaration of Helsinki and signed a consent form. The study description followed the recommendations of the Strengthening the Reporting of Observational Studies in Epidemiology criteria.

Sample calculation was based on a predicted prevalence of 15% for men and double that for women (considering that the average prevalence of dental anxiety was 27% in previous studies[14-16]) with 80% power and 95% confidence level. The calculated sample was 244 participants (n = 122 men and 122 women).

From March 2018 to November 2019, adult patients (age ≥ 18 years) who sought dental care at a public dental teaching institution were invited to participate in the present study by one of the researchers. The patients included were systemically healthy and received restorative, prosthetic, endodontic, periodontal, or surgical dental treatment immediately after the data-collection interview. Patients who reported psychiatric or physical comorbidities, required highly complex dental treatments, or were pregnant or lactating were excluded.

Risk factors and data collection

Data were collected through interviews by a previously calibrated examiner (kappa > 0.9). The calibration was performed via a pilot study with 30 participants who answered the questionnaires and then answered again 30 days later under similar clinical situations of dental care. During the interviews, the questionnaire was applied to assess the level of dental anxiety and risk factors such as age, years of schooling, preoperative pain, and the type of dental treatment to which the participant would be submitted on the date of application of the dental anxiety questionnaire.

Preoperative pain was assessed by the question "Are you in pain right now?". When the respondent indicated that pain was present, they were asked to mark the intensity on a visual analog scale (0–170). Age (years) was recorded and patients were stratified into two groups according to age (18–40 and 41–80 years, respectively) as well as years of

schooling (≤ 12 years or > 12 years). Then, to assess the type of dental treatment, two distinct groups were established. One treatment group included participants receiving nonsurgical endodontic treatment, independently of the dental group, and simple surgical treatments such as dental extraction of teeth in occlusion or tooth root, excluding cases with impacted third-molar surgeries and implants. The second treatment group included participants undergoing nonsurgical periodontal treatments such as supra-gingival or subgingival scaling procedures and prophylaxis in general as well as prosthetic-restorative treatments such as direct and indirect restorations, cementation of temporary or final prostheses, or manufacture of fixed or removable prosthesis.

The level of dental anxiety among study participants was measured using the MDAS[13]. The scale consists of five questions with five alternative answers, with a value of "1" being assigned to the alternative corresponding to the lowest degree of anxiety and "5" to the highest degree. Thus, the minimum possible score is five points (without anxiety) and the maximum is 25 points (extreme anxiety). Patients were considered to have dental anxiety when their scores were greater than or equal to 16[16,24].

Data analysis

The data were entered into the Statistical Package for the Social Sciences version 22.0 software (SPSS for Windows, version 22.0; IBM Corporation, Armonk, NY, USA). The prevalence of anxiety and risk factors (age, years of schooling, preoperative pain, and type of dental treatment) according to each gender was determined. To better explore the influence of gender on anxiety, a multivariate analysis was conducted using a logistic regression model across the sample. For statistical inference, the chi-squared test ($p < 0.05$) and odds ratio (OR) with a 95% confidence interval (CI) were used.

RESULTS

A total 256 patients were invited to participate in the study, of whom 244 met the eligibility criteria. Of the total participants included, 44 (18%) were considered to have dental anxiety according to the MDAS cutoff score of 16 points. The prevalence of dental anxiety was 22.9% (28/122) in women and 13.1% (16/122) in men (odds ratio: 1.75, 95% confidence interval: 1.02–3.01; $p = 0.04$). Regarding the other variables studied, the genders were similar, except for the presence of preoperative pain, which was more prevalent in women ($p = 0.04$) (Table 1).

Table 2 shows the distribution of dental anxiety per gender according to the risk factors studied. Dental anxiety was more frequent among female patients with preoperative pain than in those without preoperative pain (35.7% vs. 19.1%).

Multivariate logistic regression analysis including all patients suggests an association between female gender and the presence of dental anxiety (odds ratio: 1.833, 95% confidence interval: 0.926–3.629) and presence of preoperative pain (odds ratio: 2.095, 95% confidence interval: 0.977–4.492), although the significance level was not reached.

Table 1. Distribution of the study variables according to gender

Variable		Female (n=122) (%)	Male (n=122) (%)	P value
Age (years)	18-40 (n=108)	49 (40.2)	59 (48.4)	0.19
	41-80 (n=136)	73 (59.8)	63 (51.6)	
Years of schooling	≤ 12 (n=149)	71 (58.2)	78 (64)	0.35
	> 12 (n=95)	51 (41.8)	44 (36)	
Preoperative pain	Present (n=44)	28 (23)	16 (13.1)	0.04
	Absent (n=200)	94 (77)	106 (86.9)	
Type of treatment	Endodontic and surgical (n=152)	76 (62.3)	76 (62.3)	1.0
	Periodontal and restorative (n=92)	46 (37.7)	46 (37.7)	

Table 2. Distribution of anxiety according to the factors studied, stratified by gender

Gender	Variable		Anxious (%)	Not anxious (%)	P value
Female	Age (years)	18-40 (n=49)	13 (26.5)	36 (73.5)	0.441
		41-80 (n=73)	15 (20.5)	58 (79.5)	
	Years of schooling	≤ 12 (n=71)	13 (18.3)	58 (81.7)	0.150
		> 12 (n=51)	15 (29.4)	36 (70.6)	
	Preoperative pain	Present (n=28)	10 (35.7)	18 (64.3)	0.067
		Absent (n=94)	18 (19.1)	76 (80.9)	
	Type of treatment	Endodontic and surgical (n=76)	19 (25)	57 (75)	0.489
		Periodontal and restorative (n=46)	9 (19.6)	37 (80.4)	
Male	Age (years)	18-40 (n=59)	10 (16.9)	49 (83.1)	0.225
		41-80 (n=63)	6 (9.5)	57 (90.5)	
	Years of schooling	≤ 12 (n=78)	11 (14.1)	67 (85.9)	0.667
		> 12 (n=44)	5 (11.4)	39 (88.6)	
	Preoperative pain	Present (n=16)	3 (18.8)	13 (81,3)	0.474
		Absent (n=106)	13 (12.3)	93 (87.7)	
	Type of treatment	Endodontic and surgical (n=76)	12 (15.8)	64 (84.2)	0.407
		Periodontal and restorative (n=46)	4 (8.7)	42 (91.3)	

DISCUSSION

In this study, a prevalence of 18% for dental anxiety was observed and the condition was more common among women. This finding of a female predominance is controversial as it has been corroborated by some studies[4,9,11,14,18-20] but not reported by others[6,15,16,21]. Such differences in the literature could be attributed to personal and socioeconomic differences[17] as well as methodological differences such as study design, analysis methods, type of measurement of dental anxiety, and sample size.

However, given the multidimensional nature of anxiety[17], sociodemographic and preoperative factors were also explored in this study. The male and female groups were similar, except concerning the frequency of preoperative pain, which can be explained by the greater perception of pain stimulation by women[25,26]. However, when initially explored through bivariate analysis (Table 2), preoperative pain did not show association with female or male gender.

In sequence, considering that the difference in preoperative pain between groups could be a confounding factor, a multivariate logistic regression analysis was performed, grouping all study participants together (n = 244) and adopting anxiety as an outcome, gender as a variable exposure, and the other variables studied as potential confounders. In this model, the interaction between gender and preoperative pain was ruled out and female gender and the presence of preoperative pain proved to be factors that may increase the chance of dental anxiety. The chance of dental anxiety occurring was 1.8 times greater among women, similar to a previous study[9], and was two times greater among those who had preoperative pain. Other studies have suggested that the presence of preoperative pain may influence the frequency of dental anxiety[4] and vice versa[27], which may impact the sensitivity to pain even during dental care[28]. Other factors such as age, educational level, and type of dental treatment did not show a variable association with dental anxiety between the genders. However, our results cannot be directly compared with those of previous studies because other studies did not analyze these factors according to gender.

Studies that evaluated the association of anxiety to other factors without exploring gender found that dental anxiety did not differ according to age[6,15,16], though there is not complete consensus on this point[9,11,14,18]. Previous studies have considered that the older the patient, the more often they visit the dentist, which can minimize dental anxiety[9,14,18]. Nascimento et al.[16] and Yakar et al.[11] showed that the

fewer the patient's years of schooling, the higher their level of dental anxiety, while other studies did not report such an association[6,15,19,21]. Further, it has been reported elsewhere that the type of dental treatment does not influence the frequency of anxiety[16,28].

The method used in the present study to assess and identify anxious patients was the MDAS questionnaire[13], which has been validated in different languages[29,30], is easy to apply[31], and is widely used[6,3,9,11,15,16,18,21,29]. Moreover, we decided to apply the questionnaires immediately prior to initiating dental care or the procedure because patients were experiencing all of the sensations, including any emotional responses, triggered by the imminent care. Dental anxiety questionnaires have limitations because they are subjective and their outcomes are influenced by patients' responses. All anxiety questionnaires were filled out by patients and some may not have answered the questions sincerely. We also consider the fact that patients were waiting to be attended to by undergraduate dentistry students, which could artificially inflate the level of dental anxiety, to be a limitation of the present study.

According to Sadi et al.[31], dental anxiety is a common phenomenon, being one of the main reasons why many people avoid dental care[32]. Dental anxiety not only affects the patient's quality of life[5,6] but also makes the care of these patients more challenging[4]. To adopt an appropriate and successful treatment approach, adapted to the concerns of these patients, dentists first need to identify such patients[7], which would enable them to apply more appropriate dental management protocols in such cases.

We conclude that women had higher prevalence of dental anxiety. Preoperative pain was associated with anxiety, regardless of gender.

ACKNOWLEDGMENTS

The authors would like to acknowledge the support of Fundação Carlos Chagas Filho de Amparo à Pesquisa do Estado do Rio de Janeiro (FAPERJ), Brasil.

DECLARATION OF CONFLICTING INTERESTS

The authors declare no potential conflicts of interest regarding the research, authorship, and/or publication of this article.

FUNDING

None.

CONTACT INFORMATION

Dr. Manoela Dadalti
Prof. Rodolpho Paulo Rocco, 325, 2º andar - Cidade Universitária, Rio de Janeiro, RJ, CEP: 21941-913
Brasil

manoeladadalti@gmail.com

REFERENCES

1. Cianetti S, Lombardo G, Lupatelli E, Pagano S et al. Dental fear/anxiety among children and adolescents. A systematic review. Eur J Paediatr Dent 2017;18:121-130.
2. Liau FL, Kok S, Lee J, Kuo R et al. Cardiovascular influence of dental anxiety during local anesthesia for tooth extraction. Oral Surg Oral Med Oral Pathol Oral Radiol Endod 2008;105:16-26.
3. Humphris G, King K. The prevalence of dental anxiety across previous distressing experiences. J Anxiety Disord 2011;25:232-236.
4. Muglali M, Komerik N. Factors related to patients' anxiety before and after oral surgery. J Oral Maxillofac Surg 2008;66:870-877.
5. Cohen SM, Fiske J, Newton JT. The impact of dental anxiety on daily living. Br Dent J 2000;189:385-90.
6. Kanaffa-Kilijanska U, Kaczmarek U, Kilijanska B, Frydecka D. Oral Health Condition and Hygiene Habits Among Adult Patients with Respect to Their Level of Dental Anxiety. Oral Health Prev Dent 2014;12:233-239.
7. Armfield JM. What goes around comes around: revisiting the hypothesized vicious cycle of dental fear and avoidance. Community Dent Oral Epidemiol 2013;41:279–287.
8. Levin L, Zini A, Levine J, Weiss M et al. Dental anxiety and oral health-related quality of life in aggressive periodontitis patients. Clin Oral Invest 2018;22:1411–1422.
9. Guentsch A, Stier C, Raschke Gf, Peisker A et al . Oral health and dental anxiety in a German practice-based sample. Clin Oral Investig. 2017;21:1675-1680.
10. Gordon D, Heimberg RG, Tellez M, Ismail AI. A critical review of approaches to the treatment of dental anxiety in adults. J Anxiety Disord 2013;27:365-378.
11. Yakar B, Kaygusuz Tö, Pirinçci E. Evaluation of Dental Anxiety and Fear in Patients who Admitted to the Faculty of Dentistry: Which patients are more risky in terms of dental Anxiety. Ethiop J Health Sci 2019;29:719-726.
12. Corah N. Development of A Dental Anxiety Scale. J Dent Res 1969;48:596.
13. Humphris GM, Morrison T, Lindsay SJ. The Modified Dental Anxiety Scale: validation and United Kingdom norms. Community Dent Health 1995;12:143-150.
14. Viinikangas A, Lahti S, Yuan S, Pietilä I et al. Evaluating a single dental anxiety question in Finnish adults. Acta Odontol Scand 2007;65:236-240.
15. Kanegane K, Penha SS, Munhoz CD, Rocha RG. Dental anxiety and salivary cortisol levels before urgent dental care. J Oral Sci 2009;51:515-520.
16. Nascimento DL, Araújo ACS, Gusmão ES, Cimões R.

Anxiety and fear of dental treatment among users of public health services. Oral Health Prev Dent 2011;9:329-337.
17. Armfield Jm, Pohjola V, Joukamaa M, Mattila AK et al. Exploring the associations between somatization and dental fear and dental visiting. Eur J Oral Sci 2011;119:288–293.
18. Caltabiano ML, Croker F, Page L, Sklavos A et al. Dental anxiety in patients attending a student dental clinic. BMC Oral Health 2018;18:48.
19. Kheir OO, Ziada HM, Abubakr NH, Abdel-Rahman ME et al. Patient-dentist relationship and dental anxiety among young Sudanese adult patients. Int Dent J 2019;69:35-43.
20. Zinke A, Hannig C, Berth H. Psychological distress and anxiety compared amongst dental patients- results of a cross-sectional study in 1549 adults. BMC Oral Health 2019;19:27.
21. Dou L, Vanschaayk MM, Zhang Y, Fu X et al. The prevalence of dental anxiety and its association with pain and other variables among adult patients with irreversible pulpitis. BMC Oral Health 2018;18:101.
22. Behler R, Donnelly R, Umberson D. Psychological Distress Transmission in Same-sex and Different-sex Marriages. J Health Soc Behav 2019;60:18-35.
23. Luna MJ, Ameli RN, Cheringal J, Panahi S et al. Gender Differences in Psycho-Social-Spiritual Healing J Womens Health (Larchmt) 2019;28:1513-1521.
24. Haugejorden O, Klock KS. Avoidance of dental visits: the predictive validity of three dental anxiety scales. Acta Odontol Scand 2000;58:255-259.
25. Bartley EJ, Fillingim RB. Sex differences in pain: a brief review of clinical and experimental findings. Br J Anaesth 2013;111:52-58.
26. Pieretti S, Di Giannuario A, Di Giovannandrea R, Marzoli F et al. Gender differences in pain and its relief. Ann Ist Super Sanita 2016;52:184-189.
27. Svensson L, Hakeberg M, Wide U. Dental pain and oral health-related quality of life in individuals with severe dental anxiety. Acta Odontol Scand 2018;76:401-406.
28. Lin CS, Wu SY, Yi CA. Association between Anxiety and Pain in Dental Treatment: A Systematic Review and Meta-analysis. J Dent Res 2017;96:153-162.
29. Gupta G, Shanbhag N, Puranik MP. Cross-Cultural Adaptation of Kannada Version of Modified Dental Anxiety Scale Among an Adult Indian Population. J Clin Diagn Res 2015;9;ZC34-38.
30. Facco E, Gumirato E, Humphris G, Stellini E et al. Modified dental anxiety scale: validation of the italian version. Minerva Stomatol 2015;64:295-307.
31. Said H, Finkelman M, Rosenberg M. Salivary Cortisol, Salivary Alpha Amylase, and the Dental Anxiety Scale. Anesth Prog 2013;60:46-53.
32. Rayman S, Dincer E, Almas K. Managing Dental Fear and Anxiety. N Y State Dent J 2013;79:25-29.

SAIO
SOCIEDAD ARGENTINA
DE INVESTIGACION ODONTOLOGICA
División Argentina de la International Association for Dental Research

IADR
International Association for Dental Research

Since its foundation in 1961, the Argentine Society for Dental Research has held annual scientific meetings in different cities across Argentina. The meetings bring together approximately 450 researchers from different parts of the country and from abroad, including fellows, alumni, and graduate students devoted to basic and applied research in the various fields of dentistry. The aim of our meetings is to facilitate the communication of research findings and encourage discussion of results, with the ultimate goal of improving oral health and quality of life. Society activities are communicated via our website (www.saio.org.ar) and our social media.

Research Groups:

- Cariology - Public Health
- Education
- Dental Materials
- Oral Medicine & Pathology
- Orthodontics
- Periodontics & Implants

President	Gabriel Sánchez
Inmediate Past-President	Susana Molgatini
Vice-President	Raquel Gallará
Secretary	Analía Garrofé
Treasurer	Ángela Argentieri
Assistant Secretary	Daniel Di Croce
Assistant Treasurer	Carlos Rozas
Committee Members	Esteban Funosas
	Luciana Sánchez
	Luis Wuscovi
International Relations	Mariana Picca
Scientific Advisor	Noemí Bordoni

Marcelo T. de Alvear 2142 - CABA - Buenos Aires, Argentina (C1122AAH)
Phone: 5411 5287 6690 - Email: info@saio.org.ar - Website: www.saio.org.ar
SAIO División Argentina de IADR
@saio_división_argentina_iadr



Picture Authors -in order- Daniel Olmedo, Natalia Escudero, Maria Julia Piloni, Daniel Olmedo, Patricia Mandalunis, y Daniel Olmedo

Modalidad **Virtual**

SAIO
SOCIEDAD ARGENTINA DE INVESTIGACIÓN ODONTOLÓGICA
División Argentina de la International Association for Dental Research

Latin American Region IADR

IADR
International Association for Dental Research

VIII CONGRESO de la REGIÓN LATINOAMERICANA de la IADR

LIV REUNIÓN CIENTÍFICA ANUAL **SAIO**

11 al 13 noviembre 2021

Buenos Aires / **ARGENTINA**

INSCRIPCIÓN

HASTA 12/09 !!!

	Hasta 12/09/21	A partir 13/09/21
Miembros IADR	USD 10	USD 10
Socios SAIO, SUIO, SBPqO	USD 35	USD 50
No Socios	USD 50	USD 75

Carga de Resúmenes de Trabajos (Mediante Scholar One de IADR)	19/07 al 12/09
Carga de proyectos y Postulaciones a premios (Mediante Sitio Web SAIO)	19/09 al 30/09

INFORMES
reunionanual@saio.org.ar
www.saio.org.ar

Colgate

THE MEETING WILL INCLUDE SCIENTIFIC PRESENTATIONS ON THE FOLLOWING TOPICS:

- Histopathology
- Clinical Pathology
- Radiology
- Periodontics
- Epidemiology
- Preventive Dentistry
- Physiology
- Biochemistry
- Pharmacology
- Dental Materials
- Operative Dentistry
- Prosthetics
- Surgery
- Dental Implants
- Anatomy
- Microbiology
- Endodontics
- Dental Education

LIV Annual Scientific Meeting President: Analía Garrofé

For further information about the meeting and the awards the Society will be offering this year, please visit our website at:
www.saio.org.ar
email: reunionanual@saio.org.ar

Marcelo T. de Alvear 2142 - CABA - Buenos Aires, Argentina (C1122AAH)
Phone: 5411 5287 6690 - Email: info@saio.org.ar - Website: www.saio.org.ar

elmex®

MARCA SUIZA

TECNOLOGÍA DE AVANZADA PARA DIENTES SALUDABLES PARA TODA LA VIDA.

elmex® ANTICARIES

TECNOLOGÍA DE FLUORURO DE AMINA

PREVIENE LA CARIES DENTAL Y EL DESGASTE TEMPRANO DE LOS DIENTES[1]

- Contra la degradación química del esmalte y la dentina*
- Controla el proceso de biocorrosión dental*
- Enjuague bucal sin alcohol ni colorantes
- Crea una barrera que remineraliza y protege el esmalte

elmex® SENSITIVE

TECNOLOGIA PRO-ARGIN ® + CALSEAL™**

ALIVIO INMEDIATO Y PROTECCIÓN PROLONGADA CONTRA LA SENSIBILIDAD[2]

- Penetra en los túbulos dentinarios obliterándolos
- Forma una barrera protectora resistente a los ácidos
- Repara y protege las áreas sensibles de los dientes
- Enjuague bucal sin alcohol ni colorantes

elmex® ULTRA SOFT

+5500 PUNTAS ULTRAFINAS

SUAVE PARA LA ENCÍA

DELICADO, PRECISO, EFICIENTE

- Cepillo con +5.500 cerdas ultra suaves de alta densidad
- Limpieza delicada, precisa y eficiente
- Cabeza compacta para un alcance superior de los dientes distales
- 8 colores disponibles

*Soares PV. Aranha AC, y col. Guía de prevención de hipersensibilidad a la dentina. 1 a edición. 2019.**Pasta de dientes elmex SENSITIVE con Pro-Argin® + CalSeal TM, enjuague elmex SENSITIVE con fluoruro de amina + polímero protector (PVP) + arginina + fluoruro de calcio. 1. Contra la caries y con el uso continuo del régimen completo. 2. Cuando se usa como se indica en el envase y con el uso continuo del régimen completo. Este material contiene contenido propiedad de Colgate-Palmolive. Está destinado exclusivamente a consultas con profesionales dentales que han recibido este documento directamente de Colgate-Palmolive. Se prohíbe cualquier revisión, exposición, transmisión, difusión u otro uso de esta información. Imágenes meramente ilustrativas.

Colgate® Duraphat®

Experimente y compruebe la eficacia de Colgate Duraphat.

El barniz más usado en el mundo por más de 30 años

Una única aplicación de Duraphat ofrece:

Más **77%** de flúor en el esmalte[1]

Hasta **73%** de reducción de caries[2]

Libre de aerosoles: procedimiento seguro para usted y sus pacientes

Prevención, control y tratamiento clínico de la caries dental

1. Grobler S.R. Ogaard B. Rolla G. Fluoride uptake by sound enamel ofter in vivo Duraphat application. J Dent Assoc Afr 1983; 38:55-59.
2. Clark R. E. Papais A. S. Duraphat vs. Extra strenght Aim in treating of dentinal hypersensibility. J Dent Res 1992;71:628.