

Micro-computed tomographic evaluation of root canal morphology in mandibular first premolars from a Colombian population

Jaime O. Moreno¹, Martha L. Duarte¹, Marilia F. Marceliano-Alves², Flávio R.F. Alves^{2,3}, José F. Siqueira Jr.^{2,3}, José C. Provenzano²

1. Universidad Santo Tomás, Facultad de Odontología, Bucaramanga, Colombia

2. Universidade Iguazu (UNIG), Faculdade de Odontologia, Departamento de Endodontia e Pesquisa Odontológica, Nova Iguaçu, Rio de Janeiro, Brasil.

3. Universidade do Grande Rio, Programa de Pós-Graduação em Odontologia, Rio de Janeiro, Brazil.

ABSTRACT

Dental anatomy can vary significantly between different populations from different countries. Dental anatomical variations are of great interest to the dental professional, especially to endodontists, since they can influence the outcome of endodontic treatment. The purpose of the present study was to describe the anatomical variations of the root canal in mandibular first premolars in a population from Colombia, using micro-computed tomography. Fifty mandibular first premolars were scanned on a SkyScan 1174 and the microcomputed tomographic images were reconstructed. Anatomy was assessed using three-dimensional models. The parameters used were: Vertucci's classification, area and volume, perimeter, circularity, and major and minor diameter at 1, 2 and 3 mm from the apical foramen. According to the Vertucci's classification, teeth were classified as: types I (40%), V (24%), VII (4%) and III (4%), with 28% not classifiable. C-shaped canals were found in 1.8%

of the sample. Mean evaluations at 1, 2, 3 mm of the foramen were as follows, respectively: perimeter 1.07 ± 0.57 , 1.27 ± 0.78 and 1.57 ± 0.84 mm; circularity 0.59 ± 0.19 , 0.57 ± 0.20 and 0.56 ± 0.22 ; maximum diameter 0.41 ± 0.23 , 0.48 ± 0.33 and 0.60 ± 0.37 mm; minimum diameter 0.24 ± 0.10 , 0.26 ± 0.11 and 0.21 ± 0.13 mm. Mean total area and volume were 61.27 ± 16.47 mm² and 12.47 ± 4.95 mm³, respectively. There was wide anatomical variation in mandibular first premolars from Colombian individuals, reinforcing the need for proper anatomical knowledge to establish more effective strategies for endodontic treatment.

Received: October 2020; Accepted: February 2021.

Keywords: anatomical model – X-Ray microtomography – bicuspid..

Avaliação microromográfica da morfologia interna de canais de primeiros pré-molares de uma população colombiana

RESUMO

A anatomia dentária pode variar significativamente entre diferentes populações, de diferentes países. As variações anatômicas dentais são de grande interesse para o profissional da odontologia, principalmente para os endodontistas, pois podem influenciar no resultado do tratamento endodôntico. Descrever as variações anatômicas do canal radicular dos primeiros pré-molares inferiores em uma população da Colômbia, usando a micro tomografia computadorizada. Cinquenta primeiros pré-molares inferiores foram digitalizados em um SkyScan 1174 e as imagens tomográficas foram reconstruídas e a anatomia foi avaliada por meio de modelos tridimensionais. Os parâmetros utilizados foram: classificação de Vertucci, área e volume, perímetro, circularidade e diâmetros maior e menor a 1, 2 e 3 mm do forame apical. De acordo com a classificação de Vertucci, os dentes foram classificados em: tipos I (40%), V (24%), VII (4%) e III (4%), sendo 28% não classificáveis.

Canais em forma de C foram encontrados em 1,8% da amostra. As avaliações médias em 1, 2, 3 mm do forame foram as seguintes, respectivamente: perímetro $1,07 \pm 0,57$, $1,27 \pm 0,78$ e $1,57 \pm 0,84$ mm; circularidade $0,59 \pm 0,19$, $0,57 \pm 0,20$ e $0,56 \pm 0,22$; diâmetro maior $0,41 \pm 0,23$, $0,48 \pm 0,33$ e $0,60 \pm 0,37$ mm; diâmetro menor $0,24 \pm 0,10$, $0,26 \pm 0,11$ e $0,21 \pm 0,13$ mm. A média da área total e do volume foram $61,27 \pm 16,47$ mm² e $12,47 \pm 4,95$ mm³, respectivamente. Houve uma grande variação anatômica nos primeiros pré-molares inferiores de colombianos, reforçando a necessidade de conhecimento anatômico adequado para estabelecer estratégias mais eficazes para o tratamento endodôntico.

Palavras-chave: modelo anatômico - microtomografia de raios-X - bicúspide.

INTRODUCTION

The main objective of endodontic treatment is to prevent or treat apical periodontitis¹. The persistence or emergence of an apical periodontitis lesion after treatment can be regarded as a failed outcome and may be associated with difficulties encountered during endodontic intervention².

Chemomechanical preparation can be considered as the main phase of root canal treatment³. It consists of cleaning, shaping, and disinfecting the main canal, through the mechanical action of instruments and the chemical effects of irrigant solutions, creating appropriate intracanal conditions to receive the filling material⁴⁻⁶.

Anatomical complexities of the root canal system can pose a major challenge during endodontic treatment, so knowledge of internal anatomy and its variations is of utmost importance for success^{7,8}. Endodontic instruments and irrigants have limitations in reaching and disorganizing bacterial biofilms located in areas such as isthmuses, ramifications and recesses, which often require special strategies for cleaning and disinfection¹.

Difficult-to-reach irregular areas can harbor remnants of pulp tissue or residual infected debris, which may compromise the treatment outcome⁹. Mandibular premolars can present complex anatomy; according to the Vertucci's classification⁷, these teeth can present several anatomical classifications, from type I to V. In addition to these variations, these teeth can also present a C-shaped canal, which is a ribbon-shaped orifice, formed when the canals merge to form a 180° arc and a narrow strip of curved pulp tissue is formed¹⁰. A C-shaped canals presents a serious challenge for adequate endodontic treatment. Root canal anatomy may vary according to ethnic factors¹¹, sex¹² and age¹³. Most previous studies were performed in Caucasian populations¹⁴. Similar investigations in other populations in South America are less frequent, especially in Colombia, where studies on internal dental anatomy are rare. Thus, the purpose of the present study was to describe the root canal morphology of the mandibular first premolar in a Colombian population using micro-computed tomography (micro-CT) as the evaluation method.

MATERIALS AND METHODS

Fifty mature mandibular first premolars with intact crowns, available from the Bank of Human

Permanent Teeth of the Santo Tomás University, Bucaramanga, Colombia, were used in this study. Teeth had been extracted for orthodontic reasons unrelated to this study. Consent was secured prior to tooth donation. The teeth evaluated in this study were from patients from the metropolitan region of Bucaramanga, Colombia, including the cities Floridablanca, Girón, Lebrija, and Piedecuesta. The population in this region is miscegenated, as in other Latin American countries. This study was conducted under the principles established in Resolution 08430 of Colombia and approved by the Ethics Committee of Santo Tomás University. Exclusion criteria included teeth with incomplete root formation, root resorption, crown and/or root fractures, previous endodontic treatment and extensive restorations and/or caries.

The teeth were scanned on the SkyScan 1174v2 micro-CT device (Bruker-microCT, Kontich, Belgium) with a 50 kV source at 800 μ A, with the following parameters: rotation step of 1.0°, a 360° rotation around the vertical axis, and 17 μ m pixel size. The image of each specimen was reconstructed from the apex to the cemento-enamel junction with the NRecon v.1.6.9 software (Bruker-microCT), which provided transversal axial sections of the internal structure. After this procedure, three-dimensional models of the dentin and canals were obtained through an automatic segmentation threshold with the CTAn V.1.13 software (Bruker-microCT). Subsequently, the software CTVol v.2.2.1 (Bruker-microCT) was used for visualization and qualitative evaluation of root canal morphology according to the Vertucci classification.

Images of each tooth were evaluated by two observers, and by a third in case of disagreement. The evaluation parameters included: Vertucci's classification, two-dimensional data of root canal perimeter, circularity, and major and minor diameters at 1, 2 and 3 mm short of the apical foramen, as well as three-dimensional data of the total area and volume of the root canals.

RESULTS

According to the Vertucci classification, 40% of the mandibular first premolars were categorized as type I, while 32% were distributed among types III, V and VII (Fig. 1, Table 1). The remaining 28% of the tooth specimens did not meet any of the Vertucci classification types and were considered

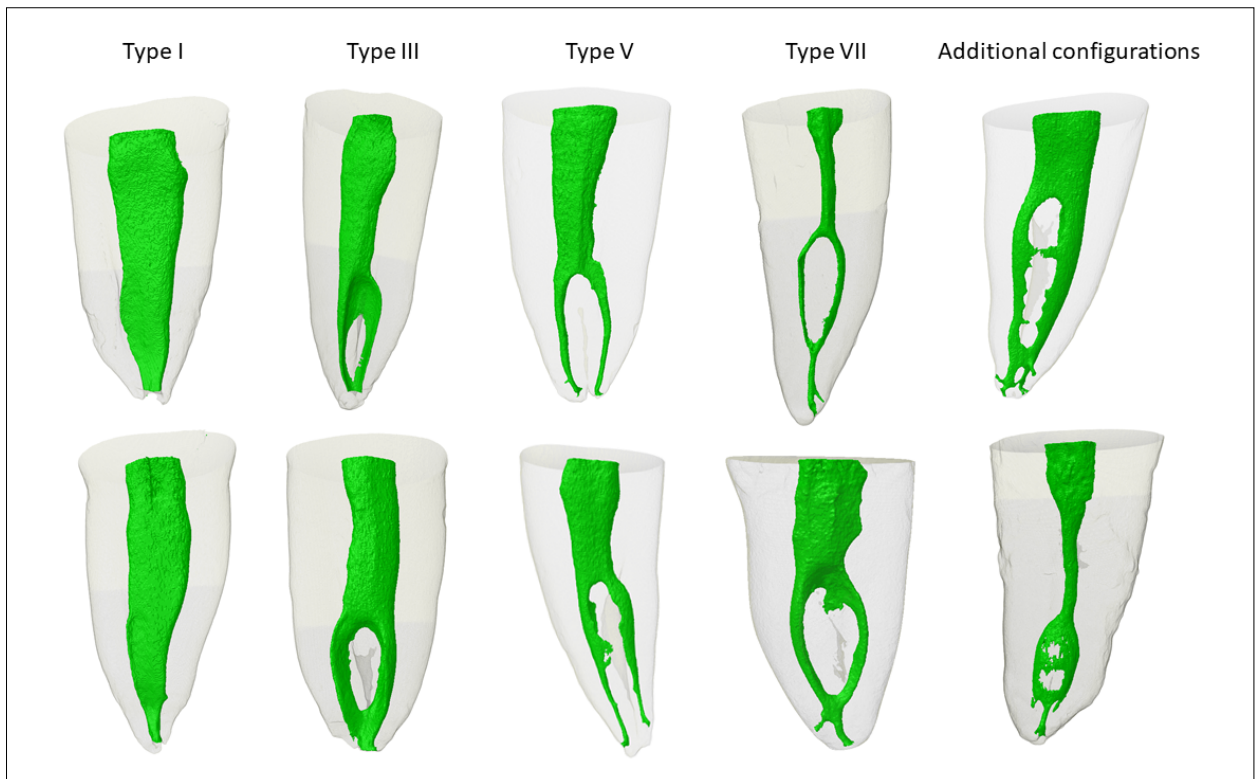


Fig. 1: Types of canals found in Colombian first mandibular premolars according to the Vertucci classification (1984).

as additional configurations. Of these, the most frequent configuration was type 1-2-3 (six teeth), followed by configuration 1-3 (three teeth) (Table 2). C-shaped canals were found in 1.8% of the specimens (Fig. 2). Table 3 shows the data from the two and three-dimensional evaluations.

DISCUSSION

Knowledge of the internal and external anatomy of the different tooth groups is essential for an endodontic treatment with favorable prognosis. Some studies have associated the complexity of

the root canal system with the failure of endodontic treatment, usually because of the difficulties in attaining proper disinfection throughout the system irregularities^{15,16}. Thus, the aim of this study was to contribute to the knowledge of the anatomy of mandibular premolars, a tooth with recognized complexity in internal anatomy, from a Colombian population that had not been the subject of an anatomical study by micro-CT.

Micro-CT is an excellent non-invasive, non-destructive tool for assessing internal and external

Table 1. Vertucci classification of the root canal morphology of Colombian mandibular first premolars as evaluated by micro-computed tomography

Vertucci classification	Specimens (n)	Frequency (%)
Type I	20	40
Type III	2	4
Type V	12	24
Type VII	2	4
Additional configurations	14	28
Total	50	100

Table 2. Additional configurations of the root canal morphology of Colombian mandibular first premolars as evaluated by micro-computed tomography and not included in the Vertucci classification

Additional configuration	Specimens (n)
1-3	3
1-4	1
1-2-3	6
1-3-2	1
1-2-1-2	1
1-2-1-2-1-3	1
1-2-4-3-4-3	1

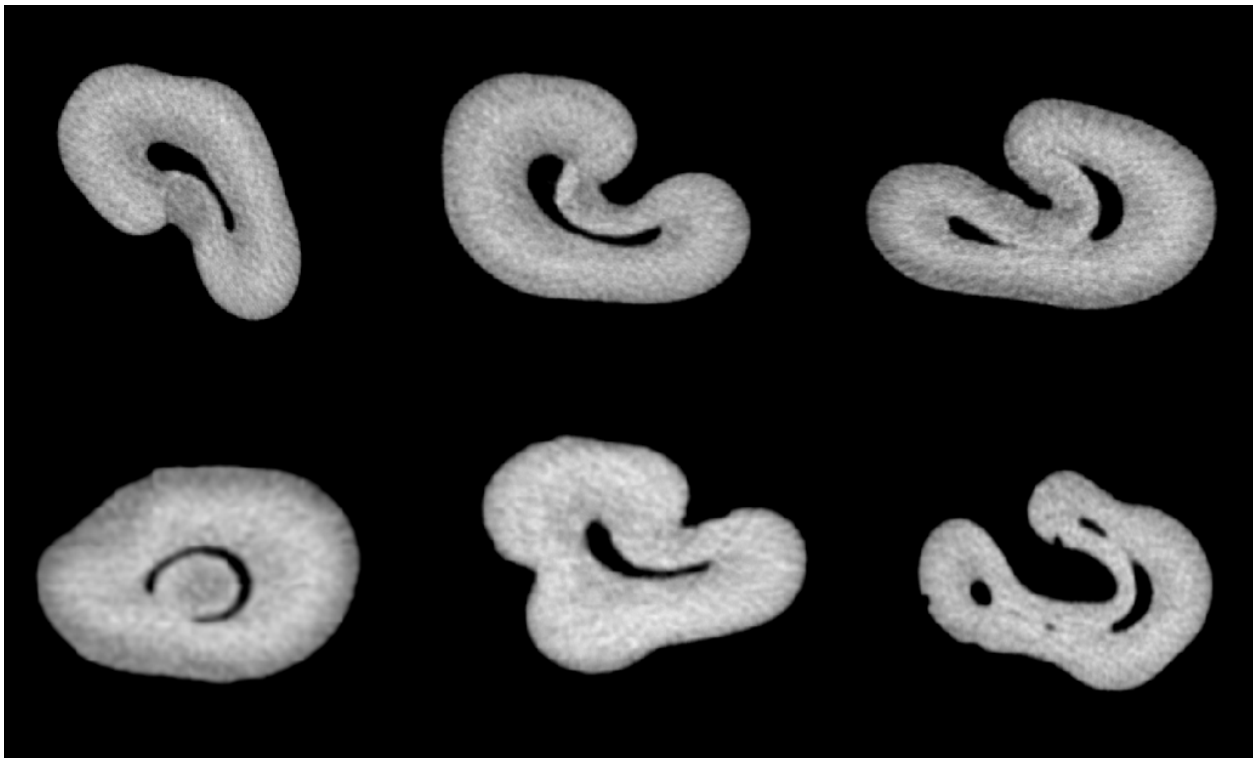


Fig. 2: Cross-sectional representative images of C-shaped canal found in the sample of Colombian individuals.

dental anatomy through the reconstruction of three-dimensional models. In the present study, a pixel size of 17 μm resolution was used, which is efficient to demonstrate the complexity of root canal anatomy¹⁷. In this study, the Vertucci type I configuration was the most prevalent (40% of cases), in contrast to a systematic review that found a frequency of this configuration almost twice as high in other countries¹⁴.

The prevalence of Vertucci class V canals in the present study of a Colombian population (24%) is similar to prevalence reported in other studies that used micro-CT, including specimens evaluated from populations of China and Saudi Arabia with a frequency of approximately 21%^{18,19}. It should be noted that some studies^{18,19} did not evaluate data such as apical canal diameter (Table 3), which could be valuable to plan the instrument size and other preparation strategies²⁰.

Vertucci types III and VII configurations had the lowest frequencies in this study, each occurring in 2% of the sample. Similar findings were reported by Liu et al.²¹, who found 2.6% for type III and 0.9% for type VII. Together, types III, V and VII and the additional configurations comprised 60% for the evaluated premolars, highlighting the complex,

Table 3. Data from the total area and volume and other parameters evaluated at 1, 2 and 3 mm from the apical foramen (mean \pm standard deviation) of Colombian mandibular first premolars as evaluated by micro-computed tomography

Parameter	Mean \pm SD	Range
Area mm ²	61.27 \pm 16.47	27.53 – 96.51
Volume mm ³	12.47 \pm 4.95	2.91 – 22.95
Perimeter		
1 mm	1.07 \pm 0.57	0.05 – 2.79
2 mm	1.27 \pm 0.78	0.20 – 4.08
3 mm	1.57 \pm 0.84	0.15 – 4.83
Circularity		
1 mm	0.59 \pm 0.19	0.12 – 1.00
2 mm	0.57 \pm 0.20	0.15 – 0.93
3 mm	0.56 \pm 0.22	0.12 – 0.88
Major diameter		
1 mm	0.41 \pm 0.23	0.02 – 1.14
2 mm	0.48 \pm 0.33	0.07 – 1.65
3 mm	0.60 \pm 0.37	0.06 – 2.13
Minor diameter		
1 mm	0.24 \pm 0.10	0.02 – 0.58
2 mm	0.26 \pm 0.11	0.05 – 0.63
3 mm	0.21 \pm 0.13	0.02 – 0.63

variable anatomy in this group of teeth. These characteristic configurations in the study population may pose greater difficulties for the clinician during endodontic management^{18,22}.

The results of this study for canal types III, V and VII are similar to those of another study of internal anatomy using a different methodology, also carried out in Colombia²³. However, Vertucci type I was less frequent in the present study. Just over ¼ of the analyzed samples were considered as an additional configuration that did not fit the Vertucci classification, similar to that reported by Alkaabi et al.¹⁹ in an Arab population.

More than half of the evaluated teeth were not Vertucci class I, i.e., they had more than one canal and/or foraminal exit. This condition can be explained by the diversity of the Colombian population and the presence of external radicular grooves, as mentioned in a previous study⁹. These teeth have at least 2 apical foramina, which can be a challenge for proper cleaning and disinfection, increasing the risk for a poor outcome, as the complexity of the root canal system has been associated with the failure of endodontic treatment^{4,15}.

The Vertucci classification can be a limitation of this study, as it can be considered to be incomplete for studies of internal tooth anatomy. This is because

when the classification was created, there was no availability of a method as accurate as micro-CT. The presence of accessory canals does not allow objective classification, and many additional configurations or biases of interpretation may arise in the assessment.

Only one study²² with the same group of teeth and methodology in Latin America has been carried out to date, so it is not possible to make a broader comparison with other population groups. Further research with micro-CT, analyzing lower premolars in different regions of Latin America, is necessary for better morphometric comparison of this group of teeth.

CONCLUSION

The internal anatomy of mandibular premolars from the studied Colombian population proved to be more complex when compared with some other populations, with most of the teeth not being classified as Vertucci class I. Knowledge of an anatomical pattern can assist the clinician in planning the endodontic treatment and improve the prognosis. More comprehensive studies including more samples should be conducted on this and other populations to gather more data on internal anatomy.

ACKNOWLEDGMENTS

This study was conducted following an institutional agreement between the Santo Tomás de Bucaramanga University (Colombia) and the Estácio de Sá University.

DECLARATION OF CONFLICTING INTERESTS

The authors declared no potential conflicts of interest with respect to the research, authorship, and/or publication of this article.

FUNDING:

This work was supported by grants from Fundação Carlos Chagas Filho de Amparo à Pesquisa do Estado do Rio de Janeiro (FAPERJ) (E-26/202.729/2019) and Conselho Nacional de Desenvolvimento Científico e Tecnológico (CNPq), Brazilian Governmental Institutions.

CORRESPONDENCE

Dr. Marília Fagury Videira Marceliano-Alves
Av. Abílio Augusto Távora, 2134 - Dom Rodrigo, Nova Iguaçu - RJ, 26260-045
Brasil
mmarceliano@hotmail.com

REFERENCES

1. Siqueira JF Jr, Rôças IN. Clinical implications and microbiology of bacterial persistence after treatment procedures. *J Endod* 2008; 34:1291-1301.
2. Siqueira JF Jr, Rôças IN, Veiga LM, Lopes HP, Machado de Oliveira JC, Alves FR. Outlining the causes of persistent post-treatment pain in endodontics. *ENDO* 2009;3:185-204.
3. Byström A, Sundqvist G. Bacteriologic evaluation of the efficacy of mechanical root canal instrumentation in endodontic therapy. *Scand J Dent Res* 1981;89:321-328.
4. Schilder H. Cleaning and shaping the root canal. *Dent Clin North Am* 1974; 18:269-296.
5. Siqueira JF Jr, Alves FR, Versiani MA, Rôças IN, Almeida BM, Neves MA, Sousa-Neto MD. Correlative bacteriologic and micro-computed tomographic analysis of mandibular molar mesial canals prepared by self-adjusting file, reciproc, and twisted file systems. *J Endod* 2013;39:1044-1050.
6. Siqueira JF Jr, Pérez AR, Marceliano-Alves MF, Provenzano JC, Silva SG, Pires FR, Vieira GCS, Rôças IN, Alves FRF

- (2018). What happens to unprepared root canal walls: a correlative analysis using micro-computed tomography and histology/scanning electron microscopy. *Int Endod J* 2018;51:501-508.
7. Vertucci FJ. Root canal anatomy of the human permanent teeth. *Oral Surg Oral Med Oral Pathol* 1984; 58:589-599.
 8. Vertucci FJ. Root canal morphology and its relationship to endodontic procedures. *Endod Top* 2005; 10:3-29.
 9. Guerreiro D, Shin JM, Pereira M, McDonald NJ. Radicular groove accessory canal morphology in mandibular first premolars: micro-computed tomographic study. *J Endod* 2019;45:554-559.
 10. Jafarzadeh H, Wu Y-N. The c-shaped root canal configuration: a review. *J Endod* 2007; 33:517-523.
 11. Trope M, Elfenbein L, Tronstad L. Mandibular premolars with more than one root canal in different race groups. *J Endod* 1986;12:343-345.
 12. Sert S, Bayirli G. Evaluation of the root canal configurations of the mandibular and maxillary permanent teeth by gender in the turkish population. *J Endod* 2004;30:391-398.
 13. Peiris HRD, Pitakotuwage TN, Takahashi M, Sasaki K, Kanazawa E. Root canal morphology of mandibular permanent molars at different ages. *Int Endod J*.2008; 41:828-835.
 14. Kottoor J, Albuquerque D, Velmurugan N, Kuruvilla J. Root anatomy and root canal configuration of human permanent mandibular premolars: a systematic review. *Anat Res Int* 2013; 2013:1-14.
 15. Siqueira JF, Antunes HS, Rôças IN, Rachid CTCC, Alves FRF. Microbiome in the apical root canal system of teeth with post-treatment apical periodontitis. *PLoS One* 2016; 11:e0162887.
 16. Moreno JO, Alves FRF, Gonçalves LS, Martinez AM, Rôças IN, Siqueira JF. Periradicular status and quality of root canal fillings and coronal restorations in an urban colombian population. *J Endod* 2013;39:600-604.
 17. Boschetti E, Silva-Sousa YTC, Mazzi-Chaves JF, Leoni GB, Versiani MA, Pécora JD, Saquy PC, Souza-Neto MD. Micro-CT evaluation of root and canal morphology of mandibular first premolars with radicular grooves. *Braz Dent J* 2017; 28:597-603.
 18. Dou L, Li D, Xu T, Tang Y, Yang D. Root anatomy and canal morphology of mandibular first premolars in a Chinese population. *Sci Rep* 2017;7:750.
 19. Alkaabi W, AlShwaimi E, Farooq I, Goodis HE, Chogle SMA. A micro-computed tomography study of the root canal morphology of mandibular first premolars in an emirati population. *Med Princ Pract* 2017;26:118-124.
 20. Almeida BM, Provenzano JC, Marceliano-Alves MF, Rôças IN, Siqueira JF Jr. Matching the dimensions of currently available instruments with the apical diameters of mandibular molar mesial root canals obtained by micro-computed tomography. *J Endod* 2019; 45:756-760.
 21. Liu N, Li X, Liu N, et al. A micro-computed tomography study of the root canal morphology of the mandibular first premolar in a population from southwestern China. *Clin Oral Invest* 2013;17:999-1007.
 22. Ordinola-Zapata R, Bramante CM, Villas-Boas MH, Cavenago BC, Duarte MH, Versiani MA. Morphologic micro-computed tomography analysis of mandibular premolars with three root canals. *J Endod* 2013;39:1130-1135.
 23. Alfonso-Rodríguez CA, Acosta-Monzón EV, López-Marín DA, Lancheros-Bonilla S, Moreno-Abello GC, Tovar ME. Description of the root canal system of mandibular first premolars in a colombian population. *Oral Sci Int* 2014;11:35-36.