

# Cone-Beam Computed Tomography to evaluate changes in trabecular lower jawbone microstructure caused by bone loss and antiresorptive treatment

María E Avendaño<sup>1</sup>, Marina S Bonanno<sup>2</sup>, Estefanía M Zeni Coronel<sup>2</sup>,  
Clarisa Marotte<sup>2</sup>, Susana N Zeni<sup>2</sup>, Mario R Davison<sup>3</sup>

1. Universidad Nacional de Cuyo. Facultad de Odontología. Departamento de Diagnóstico por Imágenes 1, Mendoza, Argentina.
2. Laboratorio de Osteopatías Metabólicas. Instituto de Inmunología, Genética y Metabolismo (INIGEM), Consejo Nacional de Investigaciones Científicas y Técnicas (CONICET), Universidad de Buenos Aires (UBA), Facultad de Farmacia y Bioquímica (FFyB), Hospital de Clínicas "José de San Martín", Buenos Aires, Argentina.
3. Universidad Nacional de Río Negro. Carrera de Odontología, Río Negro, Argentina.

## ABSTRACT

For decades, conventional histomorphometry has been the gold standard for analyzing trabecular bone microarchitecture. In recent years, micro-computed tomography ( $\mu$ CT) devices have been validated and are now considered the gold standard for quantifying bone microstructure. **Aim:** The aim of this preliminary report is to evaluate the usefulness of CBCT to assess trabecular mandible microstructural properties in normal ewes and to compare the quantitative changes associated with ovariectomy and antiresorptive treatment. **Material and Method:** Twelve adult Corriedale ewes ( $n=4$ /group) aged 3-4 years were divided into 3 groups and studied for 28 months. Eight ewes were ovariectomized (OVX) and divided into OVX and OVX+ZOL groups ( $n=4$ /group) which were treated as follows, by jugular injection: OVX received saline solution and OVX+ZOL received zoledronate (Zol) (Gador SA, CABA, Argentina) (4 mg/month). Another four ewes were subjected to sham surgery (SHAM group) and received saline solution. **Results:** Densitometry showed that jaw mineral content (BMC) and density (BMD) were significantly lower in OVX than in SHAM and OVX+ZOL ewes; no difference was observed between OVX+ ZOL and SHAM groups. CBCT analysis showed that bone volume (BV/TV%); trabecular thickness (TbTh); connectivity density (CD) and anisotropy degree (AD) were significantly lower; and trabecular spacing (TbSp), significantly higher in OVX than in SHAM ewes. AD was significantly higher and TbSp significantly lower in OVX+ZOL than in OVX groups. BV/TV%, TbTh and CD showed a clear tendency to be higher in OVX+ZOL than in OVX groups. No statistical difference was observed between OVX+ZOL and SHAM ewes. CBCT in a nondestructive, fast, very precise procedure for measuring bone morphometric indices without biopsies, which are not indicated for morphometric evaluation in osteoporosis. **Conclusions:** The current study demonstrated the potential of the high-resolution CBCT imaging to assess in vivo quantitative bone morphometry and bone quality of lower jaw cancellous bone under normal conditions and to differentiate changes associated with excessive bone loss induced by estrogen withdrawal and antiresorptive intervention.

**Keywords:** cone beam computed tomography - osteoporosis - zoledronic acid

## To cite:

Avendaño ME, Bonanno MS, Zeni Coronel EM, Marotte C, Zeni SN, Davison MR. Cone-Beam Computed Tomography to evaluate changes in trabecular lower jawbone microstructure caused by bone loss and antiresorptive treatment. Acta Odontol Latinoam. 2023 Dec 31;36(3):131-139. <https://doi.org/10.54589/aol.36/3/131>

## Corresponding Author:

Susana N. Zeni  
snzeni@hotmail.com

Received: September 2022.

Accepted: October 2023.



This work is licensed under a Creative Commons Attribution-NonCommercial 4.0 International License

## CBCT para evaluar cambios en la microarquitectura ósea de la mandíbula por pérdida ósea y tratamiento antirresortivo

### RESUMEN

**Objetivo:** El presente informe preliminar evaluó la utilidad de Tomografía Computada de Haz Cónico (CBCT) para analizar las propiedades microestructurales trabeculares del maxilar inferior de ovejas y comparar los cambios cuantitativos asociados con la ovariectomía y tratamiento antirresortivo. Se estudiaron dieciséis ovejas Corriedale adultas de 3-4 años. **Materiales y Método:** Doce ovejas fueron ovariectomizadas (OVX) y divididas en 2 grupos: OVX y OVX+ZOL ( $n=4$ /grupo) cuyo tratamiento por inyección endovenosa en la yugular durante 28 meses fue el siguiente: OVX con solución salina y OVX+ZOL con zoledronato (Gador S.A. CABA, Argentina) (Zol) (4 mg/mes); 4 ovejas fueron sometidas a cirugía simulada (grupo SHAM). **Resultados:** La densitometría (Lunar DPX) mostró que el contenido mineral del hueso maxilar (CMO) y la densidad (DMO) fueron significativamente más bajas en OVX que en SHAM y OVX+ZOL; no se observaron diferencias entre los grupos OVX+ZOL y SHAM. El análisis de las imágenes por CBCT (Planmeca Promax 3D Classic) mostró que el volumen óseo (BV/TV%); el espesor trabecular (TbTh); la densidad de conectividad (CD) y el grado de anisotropía (AD) fueron significativamente menores ( $p<0.05$ ), y el espaciado trabecular (TbSp), significativamente mayor en OVX que en SHAM ( $p<0.05$ ). AD fue significativamente mayor ( $p<0.05$ ) y TbSp, significativamente menor en OVX+ZOL que en OVX ( $p<0.05$ ). BV/TV%, TbTh y CD mostró una clara tendencia a ser mayor en OVX+ZOL que en OVX. No se observaron diferencias estadísticas entre OVX+ZOL y SHAM. **Conclusiones:** En base a nuestros resultados consideramos que CBCT presenta suficiente confiabilidad y validez para evaluar in vivo la morfometría cuantitativa y la calidad del hueso esponjoso del maxilar inferior en condiciones normales, así como para diferenciar los cambios en dichos parámetros asociados a la pérdida ósea excesiva por la caída estrogénica e intervención antirresortiva. Aunque se necesitan estudios futuros, nuestros resultados agregarían una herramienta no invasiva adicional para diferenciar la microestructura del hueso trabecular mandibular en estudios preclínicos, sentando las bases para su futura aplicación en la práctica clínica.

**Palabras clave:** tomografía computarizada de haz cónico - osteoporosis - ácido zoledrónico

## INTRODUCTION

Cancellous bone architecture provides appropriate information about the biomechanical characteristics of bone<sup>1</sup>. For decades, conventional histomorphometry has been the gold standard for analyzing trabecular bone microarchitecture. However, it only enables two-dimensional measurements (2D) of specific, small sections of bone, and is invasive, time consuming, and predisposes to sampling errors. In recent years, micro-computed tomography ( $\mu$ CT) devices have been validated and are now the gold standard for quantifying bone microstructure<sup>2</sup>. The  $\mu$ CT technique enables detailed assessment of 3D trabecular bone microstructure. However, because it causes high radiation exposure, it can be only used *in vitro* for small samples. Cone-beam computed tomography (CBCT) has spatial resolution similar to that of conventional  $\mu$ CT but, particularly for trabecular bone, has relatively low cost and requires a lower dose or effective radiation<sup>3</sup>. In recent years, CBCT has emerged as a feasible, non-invasive, accurate tool for the assessment of several parameters of trabecular bone microarchitecture, including bone volume fraction (BV/TV%), trabecular thickness (TbTh) and trabecular spacing (TbSp)<sup>4</sup>. These parameters are important to evaluating trabecular bone quality, and the CBCT technique enables their quantitative examination<sup>5</sup>.

Postmenopausal osteoporosis is a metabolic disorder characterized by low bone mass and microarchitectural deterioration of bone tissue, which increases the risk of bone fractures. The primary clinical diagnostic criteria for osteoporosis are based on the decrease in bone mineral density (BMD)<sup>6</sup>. Nonetheless, bone architecture, too, affects the risk of bone fractures. Bisphosphonates (BPs), which are synthetic analogues of pyrophosphate, have traditionally been used to treat postmenopausal osteoporosis and other metabolic bone diseases<sup>7</sup>. BPs are rapidly cleared from systemic circulation and located on bone mineral surfaces, particularly at sites of high osteoclast activity, because of their high affinity for the calcium of the hydroxyapatite crystal<sup>8</sup>. Nitrogen-containing BPs inhibit the mevalonate pathway in the osteoclasts, decreasing cell activity and the rate at which bone is remodeled. Although they prevent loss of bone mass, their effect on bone quality is still not clear.

Bone remodeling enables bone tissue to adapt to different physiological conditions, and to replace damaged bone with newly formed bone. Even

though trabecular bone remodeling is similar throughout the skeleton, jawbone remodeling is faster and constant because of the mechanical loading stimulus (forces) during mastication, particularly in alveolar bone<sup>9,10,11</sup>. The high reduction in bone turnover, especially with the most potent BPs, such as zoledronic acid (Zol), could affect the microarchitecture and biomechanical properties of bone. In this regard, BP-related osteonecrosis of the jaw (BRONJ) has been characterized as one of the main side effects of chronic therapy with BPs<sup>12</sup>. Sheep have long been used in bone research because they are large, docile animals that are easy to house and handle, and have low maintenance costs<sup>13</sup>. They are comparable to humans due to their weight, size and bone similarity, and have often been subject to research in maxillofacial areas<sup>14,15,16</sup>. They have molars and premolars with periodontium similar to humans, experience age-related skeletal problems including tooth loss, and develop periodontitis with similar oral pathogenic bacteria to those found in the human oral environment<sup>17</sup>. Ovariectomized (OVX) ewes showed a remarkable decrease in BMD<sup>18</sup>. As in humans, the OVX ewes treated with high doses of BPs for a long time could develop BRONJ<sup>16</sup>.

In dentistry, CBCT is still limited to evaluating bone density in the jaw<sup>19,20</sup>. However there is a strong demand in clinical practice for quantitative analyses of bone microstructure. We hypothesize that CBCT has high potential for the diagnosis and treatment of osteoporosis. It is thus important to determine whether it is sensitive enough to identify changes in jawbone microstructure after bone loss or specific treatments. The aim of this preliminary report was to use CBCT analysis for assessing quantitative trabecular changes in the lower jawbone associated with high bone loss and antiresorptive treatment.

## MATERIALS AND METHOD

### Animals

Twelve virgin adult Corriedale ewes (3-4 years old), with 35 to 40 kg body weight (BW) were used for this study. They were housed, treated, and then euthanized by veterinarians authorized to handle animals by the "National Service for Health and Agro-Food Quality" (SENASA: "Servicio Nacional de Sanidad y Calidad Agroalimentaria"). BW was recorded once a month till the end of the study<sup>16</sup>. All procedures were performed in compliance with

Buenos Aires University's Hospital de Clínicas "José de San Martín" ethics guidelines approved on December 26, 2016. The animals were housed at the experimental farm of Río Negro National University and fed a daily ration of standard dry sheep feed with hay, wheatgrass, and grasses to meet nutritional recommendations. Water was supplied *ad libitum*.

### Drug administration

In humans, intravenous amino-BPs injections are used to decrease bone resorption in several bone pathologies (e.g., osteoporosis, bone metastases, multiple myeloma, hypercalcemia of malignancy). To ensure high accumulation of BP in bone in order to induce a drastic decrease in bone resorption, the ewes were administered the most potent amino-BP at higher doses. The drug administration schedule and dose were in keeping with a published regimen for treating myeloma patients<sup>21</sup>. Fasting ewes were administered 4 mg Zol/month (equivalent to 66 µg/kg for 60 kg of BW) by jugular injection for 28 months. In order to rule out confounding factors and evaluate exclusively the effect of BP accumulation on the jaw, no other drug known to suppress the immune system (e.g., glucocorticoids) or inhibit it (e.g., bevacizumab) was administered.

### Experimental design

The experimental design was previously published by our group<sup>16</sup>. Briefly, a veterinarian surgeon performed bilateral OVX on 8 animals and sham surgery (SHAM) on 4 animals under general anesthesia and cardiac and respiratory monitoring, following standard protocols for this type of procedure<sup>22</sup>. Two days post-surgery, OVX ewes were divided into two subsets and treated for 28 months (T=28) as follows:

- OVX: OVX ewes receiving 10 mL of saline solution by jugular injection.
- OVX+ZOL: OVX ewes treated with 10 mL of a Zol solution (4 mg/month) to obtain a high cumulative dose of Zol in the bone.
- SHAM: SHAM ewes receiving 10 mL saline solution and serving as controls

At T=28 animals were euthanized, and hemi-mandibles were excised and cleaned of soft tissue. Immediately after excision, they were analyzed by densitometry and computed tomography. Then, the hemi-mandibles were washed with saline and immersed in ethanol 60 % (v/v) for 72 hours. The alcohol was replaced at

24 hours intervals. The samples were dried in an oven at 100 °C for 24 hours and weighed.

### Densitometry

Hemi-mandible BMD and bone mineral content (BMC) were evaluated *ex vivo* by dual energy x-ray absorptiometry (DXA) (Lunar DPX) using a software specifically designed for animals. All bones were scanned using an identical scanning procedure. Hemi-mandibles were analyzed on a bone image on the screen. Software precision for mandible BMD was assessed by measuring one piece of mandible five times after repositioning between scans both on the same and on different days<sup>15</sup>. The hemi-mandible coefficients of variation (CVs) were as follows: BMD=0.8 % and BMC=3.0 %. All analyses were performed by a single blinded technician, to minimize inter-observer variation.

### Imaging Studies

The hemi-mandibles were analyzed by computed tomography at 1:1 magnification (Tomograph Gendex CB-500, Cone Beam, Georgia, USA). The digitalized images were analyzed using a 2D Image Analysis Software (Image Pro Plus 4.5, Media Cybernetics, USA) at the Department of Oral and Maxillofacial Radiology at Río Negro National University.

CBCT images were taken at 200 mm field of view, 120 kV, 300 minutes, scanning time 0.5 second/rotation, and slice thickness 0.5 mm with a high-resolution model. The CBCT analysis was performed using Planmeca Promax 3D Classic. Field of view was set at 80x80 mm, and voxel size at 200 µm<sup>3</sup>. Each maxilla was scanned with tube current 9 mA, voltage 105 kv, and exposure time 9 seconds. The trabecular bone histomorphometry parameters measured by CBCT were analyzed using ImageJ<sup>23</sup> with BoneJ2 plug-in<sup>24</sup>. CBCT scans were imported into the software. Images were calibrated in mm and default threshold was applied. Five cuboids were obtained from each hemi-mandible, including only cancellous bone, endeavoring to cover the entire tomography trabecular bone. TbTh, TbSp, BV/TV%, connectivity density (CD) and degree of anisotropy (AD) were calculated.

### Statistical analysis

IBM SPSS Statistics for Windows Version 21.0 (IBM Corp. USA) was used. A value of p<0.05 was considered significant. Data were expressed

as mean  $\pm$  standard deviation (SD). Normality of variables was evaluated using the Shapiro Wilk test, and homogeneity of variances was assessed by Levene's test. Data were analyzed using one-way analysis of variance (ANOVA) to detect differences in percentages and means, followed by multiple comparisons using Bonferroni's post hoc test.

## RESULTS

No significant difference in BW was observed among groups, either at the beginning or at T=28 (Table 1). At the end of the study, the significantly lowest hemi-mandible weight was observed in OVX ( $p < 0.05$ ), and the significantly highest value in OVX+ZOL ( $p < 0.05$ ) (Table 1).

Hemi-mandible BMC and BMD values were significantly lower in OVX than in SHAM and OVX+ZOL ( $p < 0.01$ ); no statistical difference was observed between OVX+ZOL and SHAM (Table 1). CBCT analysis showed that BV/TV% (Fig. 1), TbTh, CD and AD were significantly lower ( $p < 0.0075$ ;  $p < 0.0075$ ,  $p < 0.001$  and  $p < 0.02$ , respectively), and TbSp was significantly higher ( $p < 0.0002$ ) in OVX than in SHAM (Fig. 2A-D). AD was significantly higher ( $p < 0.018$ ) and TbSp significantly lower in OVX+ZOL than in OVX ( $p < 0.043$ ) (Figs. 2D and 2B, respectively). BV/TV%, TbTh and CD showed a clear tendency to be higher in OVX+ZOL than in OVX ( $p = 0.055$ ;  $p = 0.061$  and  $p = 0.054$ , respectively) (Figs. 1, 2A, and 2C). No statistical difference in the CBCT parameters was observed between OVX+ZOL and SHAM.

The area of analysis of CBCT is shown in Fig. 3. The tomography of the hemi-mandible shows normal radiodensity in SHAM and OVX+ZOL (Fig. 3A and 3C). The arrows point to the areas of low radiodensity in OVX (Fig. 3B).

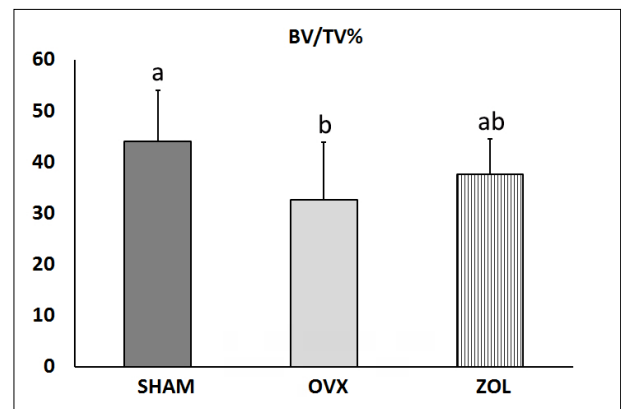
## DISCUSSION

The present preliminary report evaluated the usefulness of CBCT for assessing the quantitative changes in jawbone microarchitecture after estrogen withdrawal and antiresorptive treatment. The comparative analysis of the results showed that the jawbone quality of the ewes, as occurred in bone density, was seriously affected after 28 months post-OVX, and although the loss of bone density was prevented by the treatment with high doses of Zol, the microstructural parameters were only partially recovered.

**Table 1. Body and maxilla weight, bone mineral content and density at the end of the study.**

Experimental Groups	BW (Kg)	Maxilla weight (g)	BMC (g)	BMD (g/cm <sup>2</sup> )
SHAM	29.7 $\pm$ 2.8	178.4 $\pm$ 4.0 <sup>b</sup>	37.2 $\pm$ 2.9 <sup>b</sup>	0.244 $\pm$ 0.016 <sup>b</sup>
OVX	30.7 $\pm$ 4.6	142.8 $\pm$ 2.3 <sup>c</sup>	24.0 $\pm$ 6.1 <sup>a</sup>	0.166 $\pm$ 0.040 <sup>a</sup>
ZOL	32.0 $\pm$ 2.8	185.1 $\pm$ 5.7 <sup>a</sup>	42.3 $\pm$ 3.0 <sup>b</sup>	0.254 $\pm$ 0.026 <sup>b</sup>

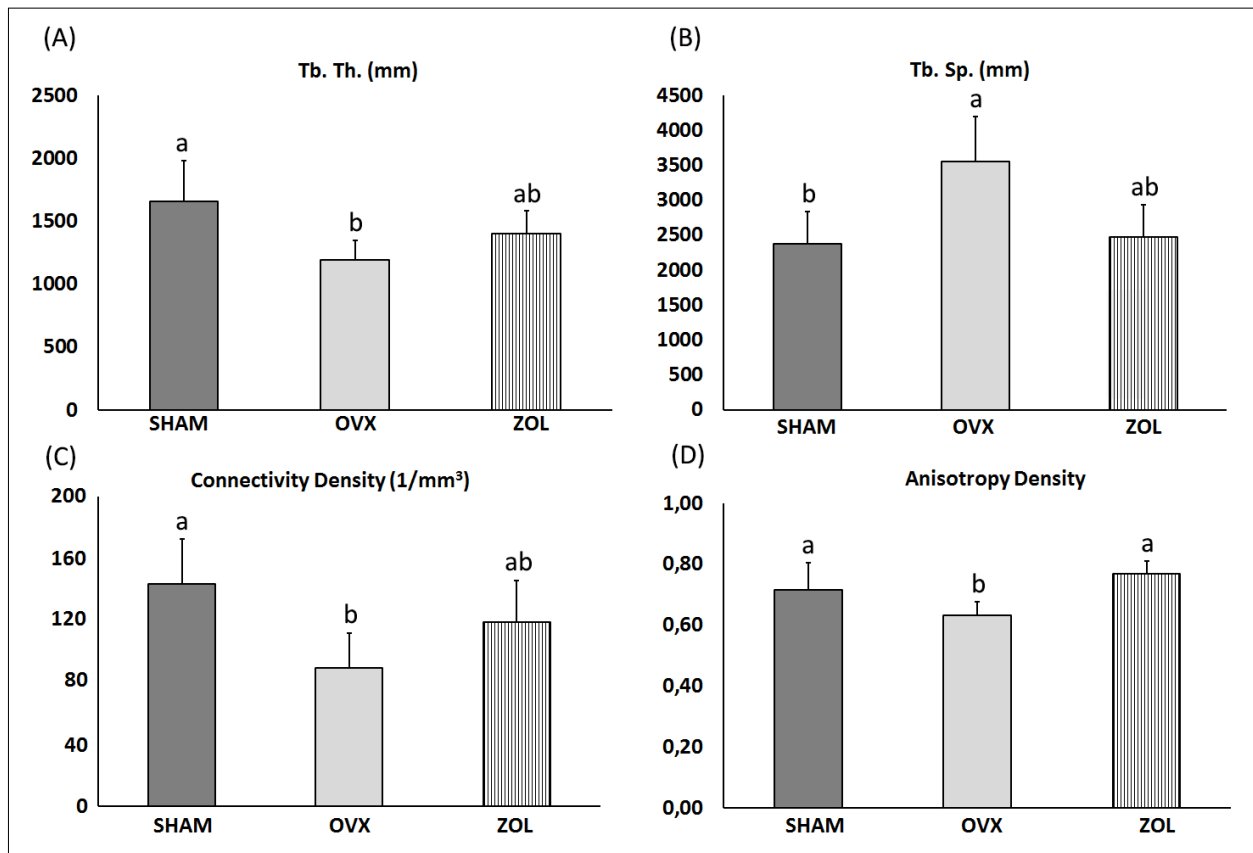
**Table 1. Body and maxilla weight, bone mineral content and density at the end of 28 months of treatment.** Data were analyzed by one-way ANOVA followed by multiple comparisons using Bonferroni's post hoc test. Results were expressed as mean  $\pm$  SD. Different letters indicate statistically significant difference. BW: body weight; BMC: bone mineral content; BMD: bone mineral density.



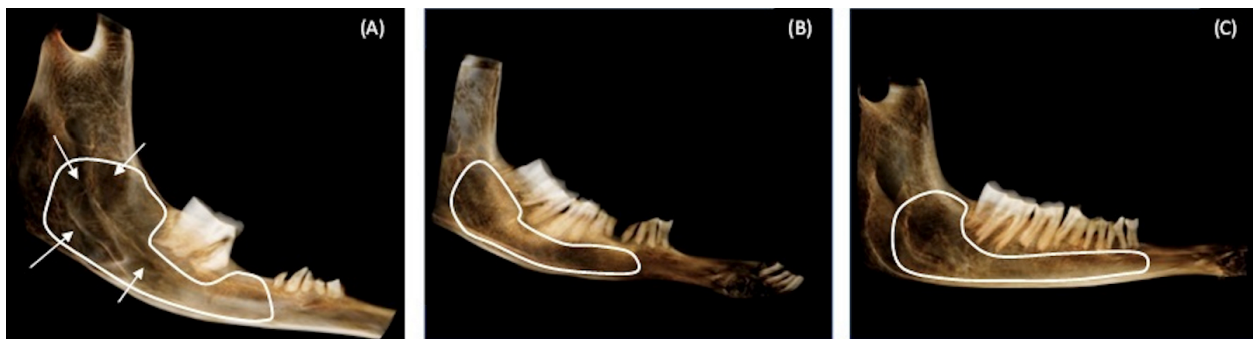**Fig. 1:** Change in the jawbone volume (BV/TV%) measured by CBCT in the three experimental groups. Data were analyzed by one-way ANOVA followed by multiple comparisons using Bonferroni's post hoc test. Results expressed as mean  $\pm$  SD. Different letters indicate statistically significant difference ( $p < 0.05$ ).

Animal models are very important to understanding several aspects of the pathological mechanism of bone diseases, as well as to establishing prevention and management strategies. Most basic investigations in this field have been conducted in rats<sup>25</sup>. Ewes are large animals that provide a suitable experimental model for many reasons. They are closer than rodents to humans in genetic constitution and metabolic rate (0.22 vs. 0.21); they undergo Haversian bone remodeling, and like women, they have menarche and regular, frequent ovulatory cycles. Bone metabolism in the OVX sheep resembles that of women during early postmenopause<sup>26,27</sup>.

Estrogen is an important regulator of bone homeostasis. The decline in estradiol levels accelerates bone remodeling characterized by higher bone resorption than bone formation, leading to



**Fig. 2:** A) Bar graphs of trabecular thickness (TbTh), B) trabecular spacing (TbSp), C) connectivity density, and D) anisotropy density, measured by CBCT in the three experimental groups. Data were analyzed by one-way ANOVA followed by multiple comparisons using Bonferroni's post hoc test. Results expressed as mean  $\pm$  SD. Different letters indicate statistically significant difference ( $p < 0.05$ ).



**Fig. 3:** Panoramic tomography of the lower left jaw of SHAM (A), OVX (B) and ZOL (C) groups. The zone delimited in white corresponds to the area of analysis by the CBCT technique. Arrows show the reduced radiodensity area in the OVX group as compared to SHAM and ZOL groups. The latter two show similar levels of radiopacity.

bone loss over time<sup>28</sup>. The animal model of estrogen withdrawal is ovariectomy. In the present report, as expected, bone mass and density had decreased by 30% at T=28. In addition to bone mass, the composition and microstructure arrangement of the basic components of bone play a critical role in the ability of the jawbone to support mastication. Indeed, the load required for bone deformation is

proportional to BMD, and therefore to the degree of bone matrix mineralization. However, the spatial distribution of bone mass (i.e., microarchitecture) influences the biomechanical efficiency of bone to support loads. It has been estimated that bone quantity is responsible for 60 to 80% of the biomechanical resistance of the bone, while the remaining 20-40% depends on bone quality<sup>29</sup>.

The term bone quality comprises a set of bone tissue characteristics encompassing multiple aspects of bone physiology, degree of mineralization, morphology and type of trabecular pattern which, in addition to density, contribute to bone strength<sup>30</sup>. According to the literature, BV/TV%, TbTh and TbSp are the most crucial indices for determining the trabecular bone microarchitecture<sup>31</sup>. However, it is important to note that trabecular bone is anisotropic, and that the inclusion of structural anisotropy improves the assessment of bone strength. In the present report, the evaluation of lower jawbone quality included these indices. The reference values were obtained by analyzing the lower jaw of the SHAM control group, which characterizes the physiological bone microarchitectural state. Any changes in these values were considered as having been induced by ovariectomy and anticatabolic treatment.

Under the experimental conditions in the current study, the CBCT technique showed that ovariectomy induced a mean loss of 25% in BV/TV%, and decreases of 30% in TbTh, 50% in TbSp, 40% in CD, and only 12% in AD. All these changes suggest an impairment of lower jaw bone mechanical integrity. According to the literature, BV/TV, which is considered one of the most important parameters in bone quality, shows a high correlation with BMD<sup>32</sup>. In this regard, the significant decrease in BV/TV% following ovariectomy observed in the present study may indicate that the trabecular bone strength of the jaw was highly affected. The changes in the bone morphometric parameters detected by CBCT in the lower jawbone of OVX ewes agree with previous findings in other bones, using a different technique. Conventional histomorphometric analysis of the lumbar vertebrae and the iliac crest showed a decrease in BV/TV% and in TbTh, and an increase in TbSp<sup>33,34</sup>;  $\mu$ -CT analysis of femoral neck showed a decrease in BV/TV% and TbTh one year after OVX<sup>35,36</sup>, while in the spine or distal femur such changes were observed one or two years after OVX<sup>5</sup>. Connectivity estimates the number of connected structures in a network whose maintenance is critical for supporting loads. CBCT measurement of CD showed a significant decrease in OVX, providing evidence that the trabecular network was seriously altered. This finding is crucial because it has been suggested that for the same decline in bone mass, the loss of trabecular connectivity is 2 to 5 times more

deleterious to bone strength than is the thinning of the trabeculae<sup>37</sup>. The high reduction in trabecular separation was not unexpected because in 3-D analysis, this parameter is influenced by connectivity. Anisotropy represents the 3D configuration and arrangement of bone, and it is more independent of bone mass than the other 3D morphometric parameters, so may strongly contribute to predicting changes in bone strength. Our CBCT analysis showed that in OVX, both BV/TV% and the heterogeneity of trabeculae were reduced, suggesting a decrease in the load-carrying capacity and mechanical function of the lower jawbone. All these findings indicate that, as expected, densitometry reveals the loss of bone mass and density by ovariectomy, but CBCT analysis adds information showing that ovariectomy seriously jeopardized the structural resistance of the lower jawbone.

Remodeling enables bone tissue to adapt to different physiological conditions and replace damaged bone with newly-formed bone. Although the bone remodeling mechanism in the jawbone is similar to that in other bones, jawbone is remodeled more rapidly because of the effect of mastication<sup>9</sup>. Excessive osteoclastic bone resorption results in an osteoporotic stage characterized by loss of BMD and biomechanical properties of bone as observed in the OVX ewes. Pharmacological strategies for osteoporosis consist of increasing bone strength and improving bone quantity and quality. BPs are the drugs of choice to initiate anticatabolic therapy for osteoporosis. They are incorporated faster in the active areas of osteoclastic bone resorption<sup>6</sup>, reducing the rate of bone remodeling and bone loss. In the current study, treatment with Zol was started immediately after surgery (2 days), preventing the bone loss that occurs as a consequence of the estrogen withdrawal induced by the ovariectomy. In this regard, the results of the present report agree with previous findings showing that preventive treatment with Zol protected against OVX-induced loss of BMD and BMC. However, the CBCT technique showed that bone quality was only partially recovered. Indeed, in OVX+ZOL ewes, BV/TV%, TbTh and CD values were 15% lower than in control ewes, while TbSp and AD values were similar. These results provided evidence that although Zol prevented the decay of cancellous bone mass and density induced by OVX, the recovery of bone microstructure was only partial. It must be taken into account that the main

bone quality defect in osteoporosis is the disruption in bone microarchitecture, and that Zol treatment cannot completely restore the mechanical integrity of jawbone because it lacks an anabolic effect.

Traditionally, the evaluation of bone status has depended on bone quantity or bone density; however, if bone architecture is also determined as described in the present report, it is possible to assess bone mass and quality at the same time, enabling a more precise evaluation of bone strength and therefore of the risk of fracture. The results of the present report clearly indicate that high-resolution CBCT is adequate for characterizing and differentiating the microarchitecture of both normal and osteoporotic lower jaws of ewes, before and after antiresorptive treatment. The future standardization of these findings may extend the availability of this technology in basic longitudinal research, laying the groundwork for future use in clinical practice, especially when repetitive follow-up measurements are needed.

Although CBCT technology can be used to evaluate the jawbone *in vivo*, one limitation of the present study is that the measurements were conducted *ex*

*vivo*, in the absence of motion artifacts that could affect the results. We will conduct further studies *in vivo* to determine the potential effects of repeated CBCT scans, and whether it can be used monitor changes accurately and precisely over time.

## CONCLUSION

CBCT in a nondestructive, fast, very precise procedure for measuring bone morphometric indices without biopsies, which are not indicated for morphometric evaluation in osteoporosis.

In conclusion, the present study demonstrated the potential of the high-resolution CBCT imaging to evaluate *in vivo* the quantitative bone morphometry and bone quality of lower jaw cancellous bone in normal condition, and to distinguish the changes associated with excessive bone loss induced by estrogen withdrawal and antiresorptive intervention. Although further studies are needed, these results provide an additional tool for evaluating trabecular mandibular bone microstructure in preclinical studies, laying the groundwork for its future application in clinical practice.

## ACKNOWLEDGMENTS

The authors thank Gador SA for kindly providing the zoledronate used throughout the experiment.

## FUNDING

This study was partially supported by a Grant from the Universidad Nacional de Río Negro N°40-A-139; a Grant from the Universidad de Buenos Aires, Programación científica

UBACyT, N°20020090200037 and a Grant from the Agencia Nacional de Promoción de la Investigación, el Desarrollo Tecnológico y la Innovación. Proyectos de Investigación Científica y Tecnológica (PICT) N°2018- 01252.

## CONFLICT OF INTEREST

The authors declare no potential conflicts of interest regarding the research, authorship, and/or publication of this article.

## REFERENCES

1. He RT, Tu MG, Huang HL, Tsai MT, Wu J, Hsu JT. Improving the prediction of the trabecular bone microarchitectural parameters using dental cone-beam computed tomography. *BMC Med Imaging*. 2019;19(1):1-9. <https://doi.org/10.1186/s12880-019-0313-9>
2. Van Dessel J, Huang Y, Depypere M, Rubira-Bullen I, Maes F, Jacobs R. A comparative evaluation of cone beam CT and micro-CT on trabecular bone structures in the human mandible. *Dentomaxillofacial Radiol*. 2013;42(8):20130145. <https://doi.org/10.1259/dmfr.20130145>
3. Servais JA, Gaalaas L, Lunos S, Beiraghi S, Larson BE, Leon-Salazar V. Alternative cone-beam computed tomography method for the analysis of bone density around impacted maxillary canines. *Am J Orthod Dentofacial Orthop*. 2018;154(3):442-9. <https://doi.org/10.1016/j.ajodo.2018.01.008>
4. Barnkggei I, Al Haffar I, Shaarani E, Khatib R, Mashlah A. Assessment of jawbone trabecular bone structure amongst osteoporotic women by cone-beam computed tomography: the OSTEOSYR project. *J Investig Clin Dent*. 2016;7(4):332-40. <https://doi.org/10.1111/jicd.12170>
5. Kreipke TC, Rivera NC, Garrison JG, Easley JT, Turner AS, Niebur GL. Alterations in trabecular bone microarchitecture in the ovine spine and distal femur following ovariectomy. *J Biomech*. 2014;47(8):1918-21. <https://doi.org/10.1016/j.jbiomech.2014.03.025>
6. Peck WA. Consensus development conference: diagnosis, prophylaxis, and treatment of osteoporosis. *Am J Med*. 1993;94(6):646-50. [https://doi.org/10.1016/0002-9343\(93\)90218-e](https://doi.org/10.1016/0002-9343(93)90218-e)
7. McClung MR. Bisphosphonates. *Endocrinol Metab Clin*. 2003;32(1):253-71. [https://doi.org/10.1016/S0889-8529\(02\)00079-8](https://doi.org/10.1016/S0889-8529(02)00079-8)
8. Diel IJ, Fogelman I, Al-Nawas B, Hoffmeister B, Migliorati C, Gligorov J, et al. Pathophysiology, risk

- factors and management of bisphosphonate-associated osteonecrosis of the jaw: Is there a diverse relationship of amino- and non-aminobisphosphonates? *Crit Rev Oncol Hematol.* 2007;64(3):198-207. <https://doi.org/10.1016/j.critrevonc.2007.07.005>
9. Huja SS, Fernandez SA, Hill KJ, Li Y. Remodeling dynamics in the alveolar process in skeletally mature dogs. *Anat Rec Part Discov Mol Cell Evol Biol Off Publ Am Assoc Anat.* 2006;288(12):1243-9. <https://doi.org/10.1002/ar.a.20396>
  10. Phal PM, Myall RWT, Assael LA, Weissman JL. Imaging findings of bisphosphonate-associated osteonecrosis of the jaws. *Am J Neuroradiol.* 2007;28(6):1139-45. <https://doi.org/10.3174/ajnr.A0518>
  11. Zahrowski JJ. Bisphosphonate treatment: an orthodontic concern calling for a proactive approach. *Am J Orthod Dentofacial Orthop.* 2007;131(3):311-20. <https://doi.org/10.1016/j.ajodo.2006.09.035>
  12. O'Ryan FS, Khoury S, Liao W, Han MM, Hui RL, Baer D, et al. Intravenous bisphosphonate-related osteonecrosis of the jaw: bone scintigraphy as an early indicator. *J Oral Maxillofac Surg.* 2009;67(7):1363-72. <https://doi.org/10.1016/j.joms.2009.03.005>
  13. Reinwald S, Burr D. Review of nonprimate, large animal models for osteoporosis research. *J Bone Miner Res.* 2008;23(9):1353-68. <https://doi.org/10.1359/jbmr.080516>
  14. Voss PJ, Stoddart M, Ziebart T, Zeiter S, Nelson K, Bittermann G, et al. Zoledronate induces osteonecrosis of the jaw in sheep. *J Cranio-Maxillofac Surg.* 2015;43(7):1133-8. <https://doi.org/10.1016/j.jcms.2015.04.020>
  15. Voss PJ, Stoddart MJ, Bernstein A, Schmelzeisen R, Nelson K, Stadelmann V, et al. Zoledronate induces bisphosphonate-related osteonecrosis of the jaw in osteopenic sheep. *Clin Oral Investig.* 2016;20(1):31-8. <https://doi.org/10.1007/s00784-015-1468-6>
  16. Davison MR, Lyardet L, Preliasco M, Yaful G, Torres P, Bonanno MS, et al. Aminobisphosphonate-treated ewes as a model of osteonecrosis of the jaw and of dental implant failure. *J Periodontol.* 2020;91(5):628-37. <https://doi.org/10.1002/JPER.19-0213>
  17. Ismaiel MO, Greenman J, Morgan K, Glover MG, Rees AS, Scully C. Periodontitis in sheep: a model for human periodontal disease. *J Periodontol.* 1989;60(5):279-84. <https://doi.org/10.1902/jop.1989.60.5.279>
  18. Li YH, Gao FQ, Cheng LM, Zeng MD, Qiu QY, Ding M. Different changes of microarchitectures of cortical and cancellous bones in sheep femoral head after long-term glucocorticoid interventions. *Sci Rep.* 2018;8(1):1-6. <https://doi.org/10.1038/s41598-018-28433-7>
  19. Barnkgkei I, Al Haffar I, Khattab R. Osteoporosis prediction from the mandible using cone-beam computed tomography. *Imaging Sci Dent.* 2014;44(4):263-71. <https://doi.org/10.5624/isd.2014.44.4.263>
  20. Gomes CC, de Rezende Barbosa GL, Bello RP, Bóscolo FN, De Almeida SM. A comparison of the mandibular index on panoramic and cross-sectional images from CBCT exams from osteoporosis risk group. *Osteoporos Int.* 2014;25(7):1885-90. <https://doi.org/10.1007/s00198-014-2696-3>
  21. Clemons MJ, Dranitsaris G, Ooi WS, Yogendran G, Sukovic T, Wong BY, et al. Phase II trial evaluating the palliative benefit of second-line zoledronic acid in breast cancer patients with either a skeletal-related event or progressive bone metastases despite first-line bisphosphonate therapy. *J Clin Oncol.* 2006;24(30):4895-900. <https://doi.org/10.1200/JCO.2006.05.9212>
  22. Fini M, Giavaresi G, Rimondini L, Giardino R. Titanium alloy osseointegration in cancellous and cortical bone of ovariectomized animals: histomorphometric and bone hardness measurements. *Int J Oral Maxillofac Implants.* 2002;17(1). PMID: 11858572.
  23. Abràmoff MD, Magalhães PJ, Ram SJ. Image processing with ImageJ. *Biophotonics Int.* 2004;11(7):36-42.
  24. Doube M, Klosowski MM, Arganda-Carreras I, Cordelières FP, Dougherty RP, Jackson JS, et al. BoneJ: free and extensible bone image analysis in ImageJ. *Bone.* 2010;47(6):1076-9. <https://doi.org/10.1016/j.bone.2010.08.023>
  25. Pautke C, Kreuzer K, Weitz J, Knödler M, Münzel D, Wexel G, et al. Bisphosphonate related osteonecrosis of the jaw: a minipig large animal model. *Bone.* 2012;51(3):592-9. <https://doi.org/10.1016/j.bone.2012.04.020>
  26. Thorndike EA, Turner AS. In search of an animal model for postmenopausal diseases. *Front Biosci-Landmark.* 1998;3(3):17-26. <https://doi.org/10.2741/A260>
  27. Turner AS. The sheep as a model for osteoporosis in humans. *Vet J.* 2002;163(3):232-9. <https://doi.org/10.1053/tvjl.2001.0642>
  28. Seifert-Klauss V, Fillenberg S, Schneider H, Luppä P, Mueller D, Kiechle M. Bone loss in premenopausal, perimenopausal and postmenopausal women: results of a prospective observational study over 9 years. *Climacteric.* 2012;15(5):433-40. <https://doi.org/10.3109/13697137.2012.658110>
  29. Faulkner KG. Bone matters: are density increases necessary to reduce fracture risk? *J Bone Miner Res.* 2000;15(2):183-7. <https://doi.org/10.1359/jbmr.2000.15.2.183>
  30. Bouxsein ML. Bone quality: an old concept revisited. *Osteoporos Int.* 2003;14(5):1-2. <https://doi.org/10.1007/s00198-003-1467-3>
  31. Bouxsein ML, Boyd SK, Christiansen BA, Guldberg RE, Jepsen KJ, Müller R. Guidelines for assessment of bone microstructure in rodents using micro-computed tomography. *J Bone Miner Res.* 2010;25(7):1468-86. <https://doi.org/10.1002/jbmr.141>
  32. Kulah K, Gulsahi A, Kamburoğlu K, Geneci F, Ocak M, Celik HH, et al. Evaluation of maxillary trabecular microstructure as an indicator of implant stability by using 2 cone beam computed tomography systems and micro-computed tomography. *Oral Surg Oral Med Oral Pathol Oral Radiol.* 2019;127(3):247-56. <https://doi.org/10.1016/j.oooo.2018.11.014>
  33. Giavaresi G, Fini M, Torricelli P, Martini L, Giardino R. The ovariectomized ewe model in the evaluation of biomaterials for prosthetic devices in spinal fixation. *Int J Artif Organs.* 2001;24(11):814-20. <https://doi.org/10.1177/039139880102401106>
  34. Newton BI, Cooper RC, Gilbert JA, Johnson RB, Zardiackas LD. The ovariectomized sheep as a model for human bone loss. *J Comp Pathol.* 2004;130(4):323-6. <https://doi.org/10.1016/j.jcpa.2003.12.007>



35. Wu Z xiang, Lei W, Hu Y yu, Wang H qiang, Wan S yong, Ma Z sheng, et al. Effect of ovariectomy on BMD, micro-architecture and biomechanics of cortical and cancellous bones in a sheep model. *Med Eng Phys.* 2008;30(9):1112-8. <https://doi.org/10.1016/j.medengphy.2008.01.007>
36. Holland JC, Brennan O, Kennedy OD, Rackard SM, O'Brien FJ, Lee TC. Subchondral trabecular structural changes in the proximal tibia in an ovine model of increased bone turnover. *J Anat.* 2011;218(6):619-24. <https://doi.org/10.1111/j.1469-7580.2011.01376.x>
37. Iolascon G, Frizzi L, Di Pietro G, Capaldo A, Luciano F, Gimigliano F. Bone quality and bone strength: benefits of the bone-forming approach. *Clin Cases Miner Bone Metab.* 2014;11(1):20. <https://doi.org/10.11138/ccmbm/2014.11.1.020>